

## CASE REPORT

# Catamenial Pneumothorax: A Challenging Diagnosis

Flavio Colaut, Nicola Clemente, Maurizio De Luca, Giulia Bora, Guido Scaffidi

Flavio Colaut, Nicola Clemente, Maurizio De Luca, Guido Scaffidi, Thoracic Surgery, City Hospital, via Montegrappa 1, Montebelluna (TV), Italy

Giulia Bora, Division of Thoracic Surgery, University of Turin, Molinette Hospital, Turin, Italy

**Conflict-of-interest statement:** The author(s) declare(s) that there is no conflict of interest regarding the publication of this paper.

**Open-Access:** This article is an open-access article which was selected by an in-house editor and fully peer-reviewed by external reviewers. It is distributed in accordance with the Creative Commons Attribution Non Commercial (CC BY-NC 4.0) license, which permits others to distribute, remix, adapt, build upon this work non-commercially, and license their derivative works on different terms, provided the original work is properly cited and the use is non-commercial. See: <http://creativecommons.org/licenses/by-nc/4.0/>

**Correspondence to:** Flavio Colaut, Thoracic Surgery, City Hospital, via Montegrappa 1, Montebelluna (TV), Italy  
Email: [flavio.colaut@outlook.it](mailto:flavio.colaut@outlook.it)  
Telephone: +39 349 6039619

Received: December 1, 2016

Revised: January 9, 2017

Accepted: January 12, 2017

Published online: March 30, 2017

## ABSTRACT

Catamenial pneumothorax is the most frequent manifestation of thoracic endometriosis. Diagnosis should be suspected if a spontaneous pneumothorax occurs within 72 hours from the onset of menstrual bleeding. Furthermore diagnosis can be supported by the macroscopic findings within the pleural cavity, generally represented by multiple nodules with color ranging from brown to violet and of variable dimension (from several micrometers to 1 cm); confirmation comes from histologic examination of the resected specimens (endometrial glands surrounded by a decidual-like stroma). Increased levels of CA 125 and CA 19-9 are useful clues. On the other hand, diagnosis of catamenial pneumothorax can be challenging in atypical cases presenting with none of the above mentioned features. We report a similar case in which no proof of endometriosis was found neither

at intraoperative examination of the affected hemithorax, nor at gynecological evaluation; moreover laboratory parameters and CA 125 and CA 19-9 in particular were within normal values. Eventually, diagnosis of catamenial pneumothorax was formulated only when a temporal connection with menstrual bleeding was noticed and when, on the ex juvantibus principle, implementation of a specific medical treatment was able to prevent further recurrences of the disease. A gonadotropin releasing hormone (GnRH) analogue therapy was established and since then, after a two years follow-up, pneumothorax had never recurred. In conclusion, diagnosis of catamenial pneumothorax could be established on clinical grounds only.

**Key words:** Pneumothorax; Diagnosis

© 2017 The Author(s). Published by ACT Publishing Group Ltd. All rights reserved.

Colaut F, Clemente N, De Luca M, Bora G, Scaffidi G. Catamenial Pneumothorax: A Challenging Diagnosis. *Journal of Respiratory Research* 2017; 3(1): 102-104 Available from: URL: <http://www.ghrnet.org/index.php/jrr/article/view/1799>

## INTRODUCTION

Catamenial pneumothorax is considered the most frequent (73%) manifestation of thoracic endometriosis; it can manifest also as hemothorax (14%), hemoptysis (7%) or pulmonary nodules (6%)<sup>[1]</sup>. In up to 95 % of cases, catamenial pneumothorax occurs in the right hemithorax. Diagnosis should be suspected if a spontaneous pneumothorax occurs within 72 hours from the onset of menstrual bleeding<sup>[2]</sup>.

To date, there is still lack of consensus regarding diagnosis and optimal treatment of this condition. Indeed, because of its rarity, only case reports or retrospective studies are available on this subject in the existing literature.

The aim of this case report is to highlight that a refractory pneumothorax in a female patient can be the only element to rely diagnosis upon. An helpful clue for diagnosis, according to the ex juvantibus principle, comes from the benefits of the specific ovaries inhibiting therapy.

## CASE REPORT

In February 2009, a 42 years old female presented at the outpatient

clinic complaining of cough and mild dyspnea since the month before. She was admitted after detection of a large right pneumothorax extending from the apex to the base (Figure 1).

General health conditions were good; laboratory parameters, electrocardiogram (ECG) and O<sub>2</sub> saturation were within normal limits. She only suffered from mild hypertension, mitral valve prolapse and glaucoma. The patient was on estro-progestinic medication. A right chest drain was placed. The subsequent chest X-ray demonstrated an almost complete expansion of the affected lung. Only a tiny, 35 mm wide, apical pneumothorax was detectable. Air leaks waned first and then ceased within 48 hours. After confirmation of complete pneumothorax healing, the chest drain was removed and the patient was discharged in good health conditions on 4th post-operative day. The high resolution chest CT performed one month later, as a second-level diagnostic test, demonstrated a tiny 18 mm diameter bleb located in the subpleural parenchyma of the right apex. Pneumothorax was almost undetectable (Figure 2).

Nevertheless, on July 2009, the patient presented with another episode of right spontaneous pneumothorax. Via Video-Assisted Thoracoscopic Surgery (VATS), the right apex with the bleb inside was resected by the stapled wedge resection technique. Then, in order to obliterate the pleural space, mechanical pleurodesis by parietal pleural abrasion, was carried out. The post-operative course was uneventful. A check X-ray performed on the 2nd post-operative day demonstrated a 2 cm wide residual right apical pneumothorax. This progressively resolved; consequently, on the 4th post-operative day, the chest drains were removed and the patient was finally discharged. There was no evidence of residual or recurrent pneumothorax on the plain chest radiograph carried out at the outpatient clinic on the 10th post-operative day.

On November 2009, the right pneumothorax recurred for the third time. This prompted a chest tube placement; then, in an elective setting, a thorascopic access to the right hemithorax was gained. All the areas where the blebs and bullae are generally more prone to develop, such as the apical segments of the lower lobes, were actively examined searching for any missed bleb or bullae. This was not the case; so only a further mechanical pleurodesis was carried out. The patient fully recovered and was discharged on 5th post-operative day. A check X ray in the outpatient setting was within normal limits.

Nonetheless, on August 2010 a right pneumothorax limited to the base was detected; this time, no active treatment was considered as the patient was asymptomatic and the pneumothorax appeared to be very tiny.

Unfortunately, on September 2012 the pneumothorax still hadn't resolved; on the contrary, it was wider than before, reaching about 4 cm in width. At this stage, the pneumothorax was deemed of clinical significance, so a chest drain was placed with successful expansion of the lung. On this occasion, the patient pointed out that the thoracic symptoms had emerged simultaneously with menstrual bleeding. It dawned on us that the association could not be accidental; on the contrary, a catamenial pneumothorax was deemed to be likely. Bearing in mind that most of the clinical signs of endometriosis are within the pelvis and genital organs, a gynecological examination was carried out. Unfortunately no proof of endometriosis was found. Moreover, serum CA 125 and CA 19-9, which are usually raised in case of endometriotic disease, were within normal values.

When a chest CT was performed, after discharge, a recurrent, 3.5 cm wide, pneumothorax extending from the apex to the base was again demonstrated. In this case as well, a temporal connection with menstrual bleeding was noticed. Eventually, the diagnosis of catamenial pneumothorax was deemed very likely, though it could be based

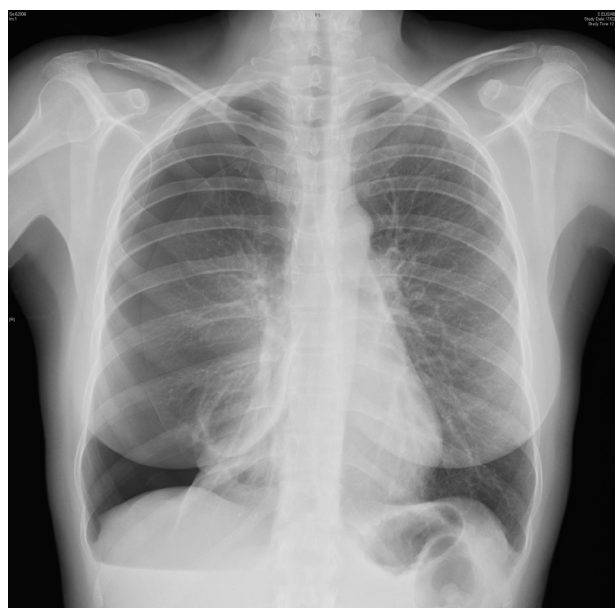


Figure 1 Large right pneumothorax extending from the apex to the base.

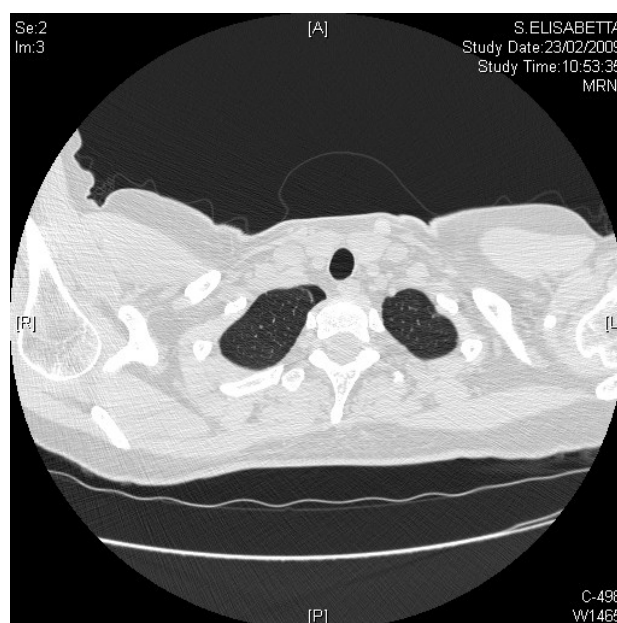


Figure 2 Catamenial pneumothorax: chest CT scan showing almost undetectable right pneumothorax one month after pneumothorax resolution (first episode).

on clinical grounds only. A gonadotropin releasing hormone (GnRH) analogue therapy was established aiming at suppressing hormonal production from ovaries and the ectopic endometrial tissue response to this stimulus. Since then, a clinical and radiological follow-up at three months intervals was scheduled; to date, at two years follow-up, after implementation of medical therapy, pneumothorax had never recurred. A chest X ray, dating two years from the last episode of pneumothorax, shows a tiny apical pneumothorax, 1 cm wide, which seems to be stable over time. The patient is asymptomatic and in good general health conditions. Basing on the *ex juvantibus* principle, the diagnosis of catamenial pneumothorax can be definitely inferred without any doubt.

## DISCUSSION

Thoracic endometriosis syndrome includes 4 well recognized cli-

nical entities, namely, catamenial pneumothorax, catamenial hemothorax, catamenial hemoptysis, and lung nodules<sup>[1]</sup>. Catamenial pneumothorax was first reported in the 1950s<sup>[2-3]</sup> and is considered the most frequent manifestation of thoracic endometriosis (73 % of patients).

It is believed to be consequence of the implantation of ectopic endometrial tissue onto pleural serosa or onto bronchial tree mucosa. Most Authors advocate embolization by lymphovascular circulation; it cannot be ruled out a mechanism of direct seeding from the peritoneal to pleural cavity before their complete separation early in the embryogenesis or after that, as in case of their abnormal, incomplete separation. Either way, the implanted tissue, because of its sensibility to the hormonal stimuli from ovaries, bleeds simultaneously to the normal endometrial one at every menstrual cycle. Bleeding leads to the clinical manifestations described above.

The above mentioned patho-physiology explains why thoracic endometriosis can be clinically evident only in fertile women with uninhibited menstrual cycles. It is well acknowledged that thoracic endometriosis syndrome normally occurs in women between the ages of 25 and 35 years<sup>[1]</sup>. Nevertheless, though rarely, some cases of catamenial pneumothorax have been described despite estro-progestinic therapy<sup>[4]</sup> or during pregnancy<sup>[5]</sup>.

Pleural endometriosis usually presents with multiple implants that can range from several micrometers to 1 cm; their color can range from brown to violet, according to the period of the menstrual cycle<sup>[6]</sup>.

Studies have shown that increased levels of CA 125 and CA 19-9 are useful in diagnosis of endometriosis<sup>[7-8]</sup>.

Diagnosis is usually supported by histologic examination of the resected specimens. Microscopically, numerous endometrial glands and stroma are usually encountered within a relatively well circumscribed lesion. Endometrial glands are typically characterized by the presence of ciliated cells with a cuboid morphology; the surrounding stroma has a decidual-like architecture.

Based on clinical manifestations, operative findings, serological tests and histopathological confirmation, diagnosis of thoracic endometriosis in all its manifestations is usually quite straightforward.

Here we report the case of a patient who suffered from multiple episodes of right pneumothorax despite surgical treatment. Diagnosis was hindered by the lack of typical endometriotic implants at macroscopic surgical exploration. Similarly, at a microscopical level, no specific feature of endometriosis was detected into the resected specimen (lung apex). Laboratory tests such as CA 125 and CA 19-9 were within normal values. Moreover, the patient was on medication with estro-progestinics which inhibit the endocrin activity of the ovaries. This was quite misleading as ectopic endometriotic tissue needs hormonal stimulus to be active and, consequently, to be responsible of the clinical manifestations of thoracic endometriosis.

Diagnosis of catamenial pneumothorax was formulated, based on

the *ex juvantibus* principle, only when, implementation of the specific medical treatment was able to prevent further recurrences of the disease.

## CONCLUSION

Diagnosis of catamenial pneumothorax can be challenging especially in atypical cases presenting with few diagnostic clues. The case reported here demonstrates that sometimes thoracic endometriosis is not associated with typical macroscopic or microscopic findings; laboratory tests can be within normal limits and the pelvic organs, which are primarily affected by endometriosis, may have a regular appearance. In such cases of young fertile females presenting with recurrent pneumothorax, a low threshold for the diagnosis of catamenial pneumothorax should be held, relying on the benefits of the specific ovarian inhibiting therapy only.

## Statement of Informed Consent

Informed consent was obtained from all individual participants included in the study.

## REFERENCES

1. Joseph J, Sahn SA. Thoracic endometriosis syndrome: new observations from an analysis of 110 cases. *Am J Med* 1996; **100**(2): 164-170. [PMID: 8629650]
2. Peikert T, Gillespie DJ, Cassivi SD. Catamenial pneumothorax. *Mayo Clinic Proc* 2005; **80**: 677-80 [PMID: 15887438]; [DOI: 10.4065/80.5.677]
3. Alifano M. Catamenial pneumothorax. *Curr Opin Pulm Med* 2010; **16**(4): 381-386. [PMID: 20473170]; [DOI: 10.1097/MCP.0b013e32833a9fc2]
4. Schoenfeld A, Ziv E, Zelel Y, Ovadia J. Catamenial pneumothorax – a literature review and report of an unusual case. *Obstet Gynecol Surv* 1986; 4120-4 [PMID: 3510408]
5. Yoshioka H, Fukui T, Mori S, Usami N, Nagasaka T, Yokoi K. Catamenial pneumothorax in a pregnant patient. *Jpn J Thorac Cardiovasc Surg* 2005; **53**: 280-2 [PMID: 15952324]; [DOI: 10.1007/s11748-005-0042-6]
6. Alifano M, Trisolini R, Cancellieri A, Regnard JF. Thoracic endometriosis: current knowledge. *Ann Thorac Surg* 2006; **81**(2): 761-769. [PMID: 16427904]; [DOI: 10.1016/j.athoracsur.2005.07.044]
7. Saito T, Maniwa T, Kaneda H, Minami K, Sakaida N, Uemura Y, Okamura A, Saito Y Coexistence of catamenial pneumothorax and catamenial hemoptysis in a patient with pulmonary hemangiomatosis-like foci: a case report. *J Thorac Cardiovasc Surg* 2010; **139**(2): e14-e16. [DOI: 10.1016/j.jtcvs.2008.07.025]
8. Foster DC, Stern JL, Buscema J, Rock JA, Woodruff JD. Pleural and parenchymal pulmonary endometriosis. *Obstet Gynecol* 1981; **58**(5): 552-556. [PMCID: PMC3021334]

**Peer reviewers:** Fahad Al-Hameed