

Presentation and Management of Pyogenic Liver Abscess in Surgery Department: About 34 Cases

Bassam Nasr, Fethi Derbel, Malek Barka, Waad Farhat, Asma Sghaier, Jaafar Mazhoud, Mohamed Ben Mabrouk, Fathia Harrabi, Mohamed Azzaza, Nefis Abdennaceur, Youssef Chaker, Lilia Mdimegh Chatty, Ali Ben Ali, Ridha Ben Hadj Hamida

Bassam Nasr, Fethi Derbel, Malek Barka, Waad Farhat, Asma Sghaier, Jaafar Mazhoud, Mohamed Ben Mabrouk, Fathia Harrabi, Mohamed Azzaza, Nefis Abdennaceur, Youssef Chaker, Ali Ben Ali, Ridha Ben Hadj Hamida, Department of surgery, University hospital Sahloul, Sousse, 4056, Tunisia

Lilia Mdimegh Chatty, Department of medical imaging, University hospital Sahloul, Sousse, Tunisia

Correspondence to: Derbel Fethi, Professor, Department of surgery, Sahloul hospital, Sousse, Tunisia

Email: Fethi.derbel@gmail.com

Telephone: +21698547896

Received: September 5, 2014

Revised: October 13, 2014

Accepted: October 18, 2014

Published online: November 21, 2014

ABSTRACT

AIM: To describe the clinical features, imaging findings, bacteriologic profile, etiology, treatment and outcome in patients presenting pyogenic liver abscess in a Tunisian hospital.

METHODS: We report, in a retrospective study, 34 cases of pyogenic liver abscess that were hospitalized between January, 1st 2004 and December, 31st 2013.

RESULTS: Thirty-four cases (19 males, 15 females) were found. The mean age was 64 years. The most significant clinical features of pyogenic liver abscess were upper abdominal pain with high grade fever and hepatomegaly. Thirty-one patients were investigated by CT scan, which showed a positive diagnosis in 100% of cases, 82.4% of liver abscesses were found in the right lobe of liver and were solitary in 79.4% of cases. The most causative germs, were isolated in pus culture, were *Escherichia coli* and *Klebsiella*. The most common etiologies were biliary and cryptogenic origin; portal pyemia and hematogenous origin were also found. All of patient had received intravenous antibiotic therapy (cephalosporin or fluoroquinolones combination with metronidazole and aminoglycoside) but only two patients were healed by this regime. The mean duration of

intravenous antibiotic therapy was 15.5 days. The percutaneous drainage was performed in 50% ($n=17$) of cases and was successfully in about 70% of cases. Surgery was performed in 58.82% ($n=20$) of cases. Six patients had only surgical drainage of abscess and the other 14 patients had cholecystectomy with drainage of abscess. The mean length of hospital stay was 19.7 days. The outcome was generally favorable with the exception of one death from septic shock.

CONCLUSION: PLA is a rare condition but has undergone a huge change. It affects the subjects increasingly older. Bacteriologically, there is an emergence of *Klebsiella* in favor of *Escherichia coli*. Its treatment became less surgical thanks to the development of percutaneous drainage. Its outcome is generally favorable.

© 2014 ACT. All rights reserved.

Key words: Liver; Abscess; Antibiotics; Percutaneous drainage; Surgery

Nasr B, Derbel F, Barka M, Farhat W, Sghaier A, Mazhoud J, Mabrouk MB, Harrabi F, Azzaza M, Abdennaceur N, Chaker Y, Chatty LM, Ali AB, Hamida RBH. Presentation and Management of Pyogenic Liver Abscess in Surgery Department: About 34 Cases. *Journal of Gastroenterology and Hepatology Research* 2014; 3(11): 1349-1356 Available from: URL: <http://www.ghrnet.org/index.php/joghr/article/view/922>

INTRODUCTION

Pyogenic liver abscess (PLA) is a suppurative infection of the hepatic parenchyma. It can develop as a complication of abdominal and biliary infections, or following hematogenous bacterial seeding of the liver. It is a rare condition but with significant mortality up to 19%^[1,2]. Its diagnostic is based in clinical features and biological findings and confirmed by imaging. If left untreated, the PLA runs a lethal course, so an adequate treatment should be performed. This treatment can be medical (antibiotic) which can be associated with interventional

(percutaneous aspiration or drainage) or surgical treatment.

METHODS

This is a retrospective study covering the period from 1 January 2004 until 31 December 2013 conducted in the digestive and visceral surgery department at Sahloul university hospital of Sousse, TUNISIA.

We report a series of 34 cases over 10 years. The diagnosis was made on clinical, biological and imaging data.

The treatment was either medical (antibiotic), interventional (percutaneous drainage) or surgical.

Clinical, biological, radiological, therapeutic and evolutive data were collected from the records of inpatients.

RESULTS

This study included 19 men and 15 women (sex ratio=1.26). The mean age was 64 years (range 21-85). Forty seven percent of patients were holders of cardiovascular problems (hypertension, dylipidemia, coronary artery disease ...) ($n=16$), 29.4% ($n=10$) had diabetes, 26.5% ($n=9$) were operated for a cholecystitis or angiocholitis and had either only cholecystectomy ($n=3$) or cholecystectomy with biliodigestive anastomosis ($n=6$), 14.7% ($n=5$) were operated for a gastric or duodenal ulcer and one case had appendicectomy 30 days ago.

The mean delay between the onset of the symptoms and the admission was 13.32 days (range 3-30).

Majority of patients (94.1%) ($n=32$) with pyogenic liver abscess reported upper abdominal pain. High-grade fever or chills were reported in 91.2% ($n=31$) of cases, vomiting and nausea in 35.3% ($n=12$) of cases, while loss of appetite in 20.6% ($n=7$) of cases (Table 1).

On examination, 73.5% ($n=25$) of patients were febrile (temperature more than 38°C), tenderness in right hypochondrium or localized guarding were the predominant signs and were found in 91.2% ($n=31$) of cases (47.1% and 44.1% respectively), whereas 8.8% ($n=3$) of patients were presented with hepatomegaly. About 17.6% ($n=6$) of patients presented with jaundice.

Laboratory tests revealed leukocytosis and elevated level of CRP in all cases. In 23.5% ($n=8$) patients had hyperbilirubinemia.

Ninety-one percent of patients ($n=31$) were investigated by CT scan with or without ultrasound, which showed a positive diagnosis in 100% of cases (Figure 1). Three patients were investigated by only ultrasound which showed a positive diagnosis in one third of cases preoperatively.

Majority of liver abscesses [82.4% of cases ($n=28$)] were found in the right lobe of liver. About 11.7% ($n=4$) of liver abscesses were confined to the left lobe only. Both lobes were involved in 5.9% ($n=2$) of cases. Acute cholecystitis was found in 26.47% ($n=9$) of cases and it was the origin of abscesses.

In our series, 79.4% ($n=27$) of patients were presented with solitary abscesses. Multiple abscesses were found in 20.6% ($n=7$) of cases. The mean size of abscesses was 9 cm (range 3.5 to 20 cm).

Thrombosis of the portal vena or the inferior vena cava as a complication of pyogenic liver abscesses was found in three cases.

Pus culture study was performed in 82.35% ($n=28$) of cases of which 21 reports came with positive microbial reports. Here, 28.57% ($n=6$) of cases were positive for *Escherichia coli* and 23.80% ($n=5$) shown *Klebsiella*. Other organisms were *Bacteroides* in 9.5% ($n=2$), *Staphylococcus* in 4.76% ($n=1$), and *Streptococcus* in 4.76% ($n=1$). Polymorphic bacterial flora was found in 19% of cases ($n=4$).

Of all the pyogenic liver abscesses, 47% were biliary tract in origin (9 cases of cholecystitis, 6 cases of angiocholitis, one case of

intraductal papillary mucinous neoplasm (IPMN)). The rest were cryptogenic in 41%, portal pyemia (appendicitis and diverticulitis) in 6%, or hematogenous (urinary infection) in 6% of cases.

All of patient had received intravenous antibiotic therapy (cephalosporin or fluoroquinolones combination with metronidazole and aminoglycoside) but only two patients were healed by this regime (one case was poorly collected abscess and the other was disseminated abscesses). The mean duration of intravenous antibiotic therapy was 15.5 days (range 5 to 30 days).

The percutaneous drainage (PCD) (Figure 2) was performed in 50% ($n=17$) of cases and was successfully in about 70% of cases (we had resort for surgical management in only 5 cases: 3 cases the abscess was localized in the segment VII or VIII of liver and the catheter was blocked or dislodged, one case the abscess was

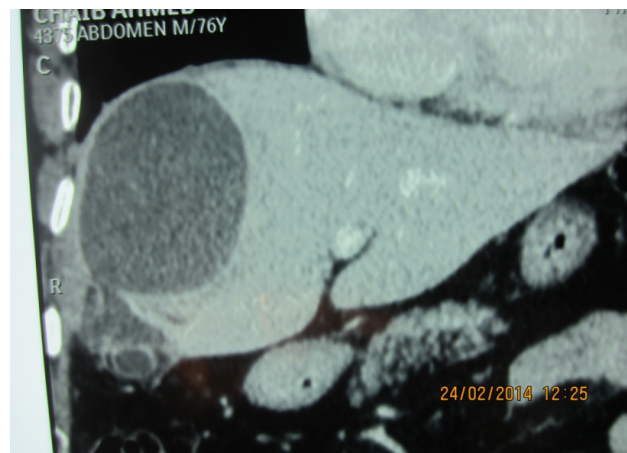


Figure 1 Solitary abscess confined to the right lobe of liver.

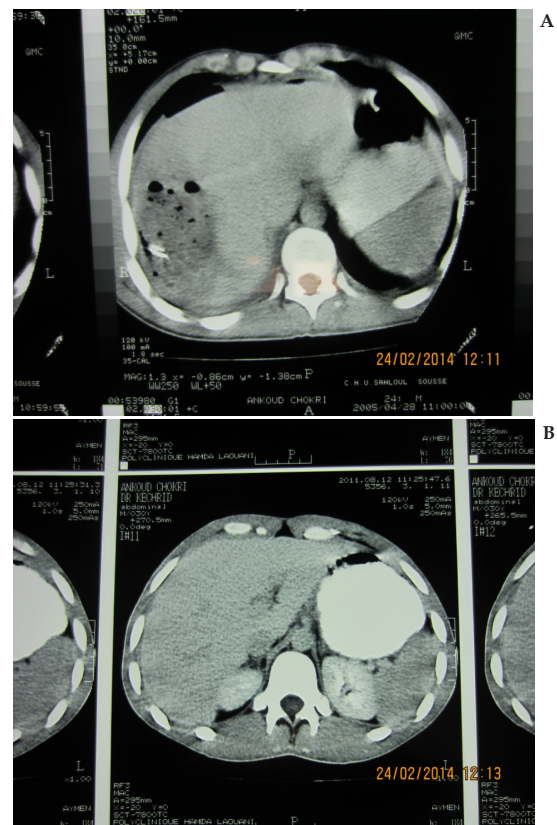


Figure 2 A: percutaneous continuous catheter drainage of liver abscess; B: CT scan after percutaneous drainage (after 2 years).

Table 1 Patients demographic data.

OBSERVATION	AGE (years)/SEX; past history	Clinical Manifestations	Laboratory Tests	Imaging	Treatment	Bacteriology	Outcome
Patient 01	79; M	Fever+ pain in the right upper-quadrant for 3 weeks. O/E: T°=39°C; gardening at palpation of the right upper-quadrant.	Leukocytes: 10700 CRP:232 Hepatic cytolysis	Ultrasound and CT scan: solitary abscess (15 cm, segment VII)	Antibiotic therapy. Percutaneous drainage: failed Surgical drainage.	Pus culture: E. coli	Good. Hospitalization= 30 days
Patient 02	45; M	Fever+ pain in the right upper-quadrant for 3 weeks. O/E: T°=37.5°C; gardening at palpation of the right upper-quadrant.	Leukocytes: 14000 CRP:79 Hepatic cytolysis and cholestasis	Ultrasound and CT scan: solitary abscess (segment VII) with thrombosis of inferior vena cava	Antibiotic therapy. Percutaneous drainage.	-	Good. Hospitalization= 45 days
Patient 03	82; M	Fever+ right upper-quadrant and epigastric pain for 10 days. O/E: T°=38.7°C; gardening at palpation the right upper-quadrant with jaundice.	Leukocytes: 15000 CRP:150 cholestasis	Ultrasound and CT scan: multiple abscess of liver with cholecystitis	Antibiotic therapy. Surgical drainage and cholecystectomy.	-	Death after 10 days (septic shock)
Patient 04	81; M; cholecystectomy with biliodigestive anastomosis for angiocholitis.	Fever+ right upper-quadrant and epigastric pain for 3 weeks. O/E: T°=37.7°C; gardening at palpation the right upper-quadrant.	Leukocytes: 13400 CRP: 83	Ultrasound and CT scan: solitary abscess (6 cm; segment IV).	Antibiotic therapy. Percutaneous drainage.	Pus culture: Bacteroides	Good. Hospitalization= 15 days
Patient 05	85; F; hypertension; cholecystectomy with biliodigestive anastomosis for angiocholitis	Fever+ pain in the right upper-quadrant +vomiting for 4days. O/E: T°=37.5°C; tenderness at palpation of the right upper-quadrant.	Leukocytes: 13800 CRP: 191	Ultrasound and CT scan: solitary abscess (6 cm, segments V-VI)	Antibiotic therapy. Percutaneous drainage.	Pus culture: E. coli	Good. Hospitalization= 20 days
Patient 06	31; M duodenal ulcer none operated.	Fever+ vomiting and epigastric pain for 3 weeks. O/E: T°=37.7°C; tenderness at palpation of the right upper-quadrant.	Leukocytes: 13700 CRP: 469	Ultrasound and CT scan: multiple abscess of liver (segments V-VII and VIII)	Antibiotic therapy. Percutaneous drainage.	Pus culture: negative	Good. Hospitalization= 6 days
Patient 07	76;F; hypertension; diabetes; dyslipidemia; cholecystectomy	Fever+ right upper-quadrant pain for 2 weeks. O/E: T°=38.7°C; gardening at palpation the right upper-quadrant.	Leukocytes: 12300 CRP: 65	Ultrasound and CT scan: multiple abscess of liver (segments V-VI) with cholecystitis	Antibiotic therapy. Percutaneous drainage: failed Surgical drainage+ cholecystectomy.	Pus culture: negative	Good. Hospitalization= 45 days
Patient 08	69;F hypertension; diabetes	Fever+ right upper-quadrant and epigastric pain for 7 days. O/E: T°=39.2°C; gardening at palpation the right upper-quadrant.	Leukocytes: 15300 CRP: 265	Ultrasound and CT scan: solitary abscess of liver (7.5 cm; segment IV) with cholecystitis	Antibiotic therapy. Surgical drainage and cholecystectomy.	Pus culture: negative	Good. Hospitalization= 15 days
Patient 09	58; F; hypertension; diabetes; dyslipidemia	Fever+ total abdominal pain for 10 days. O/E: T°=39°C; total abdominal tenderness at palpation	Leukocytes: 16500 CRP: 394 Hepatic cytolysis	CT scan: solitary abscess of liver (segment VIII)	Antibiotic therapy. Percutaneous drainage: failed Surgical drainage.	Pus culture: Klebsiella	Good. Hospitalization= 60 days
Patient 10	75; M; cholecystectomy with biliodigestive anastomosis for angiocholitis	Fever+ right upper-quadrant and epigastric pain for 19days. O/E: T°=37.5°C; gardening at palpation the right upper-quadrant and epigastric.	Leukocytes: 15000 CRP: 94	Ultrasound and CT scan: solitary abscess of liver (9 cm; segment IV-V)	Antibiotic therapy. Percutaneous drainage.	Pus culture: Bacteroides	Good. Hospitalization= 17 days
Patient 11	43; M; appendicectomy 3 weeks ago.	Fever+ right upper-quadrant pain for 7 days. O/E: T°=38.9°C; gardening at palpation the right upper-quadrant.	Leukocytes: 9400 CRP: 172	Ultrasound and CT scan: solitary abscess of liver (9 cm; segment V-VIII)	Antibiotic therapy alone for 19 days.	-	Good. Hospitalization= 12 days
Patient 12	70; F	Fever+ pain in the right upper-quadrant +vomiting for 3 weeks. O/E: T°=39°C; painful mass at palpation of the right upper-quadrant with jaundice.	Leukocytes: 10200 CRP: 279 Hepatic cytolysis and cholestasis	Ultrasound and CT scan: solitary abscess of liver (5 cm; segment V) with cholecystitis	Antibiotic therapy. Surgical drainage and cholecystectomy.	Pus culture: negative	Good. Hospitalization= 8 days

Table 1 Patients demographic data.

OBSERVATION	AGE (years); SEX; past history	Clinical Manifestations	Laboratory Tests	Imaging	Treatment	Bacteriology	Outcome
Patient 13	58; F	Fever+ right upper-quadrant pain+ vomiting for 2 weeks. O/E: T°=37.5°C; tenderness at palpation of the right upper-quadrant.	Leukocytes: 14500 CRP: 93	Ultrasound and CT scan: solitary abscess of liver (segment IV-V) with cholecystitis	Antibiotic therapy. Surgical drainage and cholecystectomy.	Pus culture: negative	Good. Hospitalization= 15 days
Patient 14	60; M; hypertension; dyslipidemia.	Fever + right upper-quadrant pain for 5 days. O/E: T°=38.8°C; gardening at palpation of the right upper-quadrant.	Leukocytes: 12300	Ultrasound: cholecystitis. At surgery: solitary abscess of liver (segment IV)	Antibiotic therapy. Surgical drainage and cholecystectomy.	Pus culture: <i>E. coli</i>	Good. Hospitalization= 6 days
Patient 15	79;M; diabetes	Fever+ right upper-quadrant pain+ vomiting for 2 weeks. O/E: T°=37.2°C; tenderness at palpation of the right upper-quadrant.	Leukocytes: 9900 CRP: 226	Ultrasound: cholecystitis. At surgery: solitary abscess of liver (segment V)	Antibiotic therapy. Surgical drainage and cholecystectomy.	Pus culture: negative	Good. Hospitalization= 7 days
Patient 16	52; M; hypertension.	Fever+ right upper-quadrant pain + vomiting for 7 days. O/E: T°=39°C; gardening at palpation of the right upper-quadrant.	Leukocytes: 11700	Ultrasound and CT scan: solitary abscess of liver (7 cm; segment V-VI)	Antibiotic therapy. Percutaneous drainage.	-	Good. Hospitalization= 16 days
Patient 17	79; F	Fever+ right upper-quadrant pain + vomiting for 3 days. O/E: T°=39°C; tenderness at palpation of the right upper-quadrant and epigastria with jaundice.	Leukocytes: 23300 Hepatic cytolysis	Ultrasound and CT scan: multiple abscess of liver (segments III-VI)	Antibiotic therapy. Surgical drainage and cholecystectomy.	Pus culture: Klebsiella	Good. Hospitalization= 16 days
Patient 18	75; M	Fever+ right upper-quadrant pain + vomiting for 7 days. O/E: T°=39.3°C; gardening at palpation of the right upper-quadrant.	Leukocytes: 13400	Ultrasound and CT scan: solitary abscess of liver (9.5 cm; segments IV-VIII)	Antibiotic therapy. Percutaneous drainage.	Pus culture: <i>E. coli</i>	Good. Hospitalization= 10 days
Patient 19	73; M	11 days after cholecystectomy, fever and right upper-quadrant pain. O/E: T°=39.3°C.	Leukocytes: 23600 CRP: 175 cholelasis	Ultrasound and CT scan: solitary abscess of liver (6cm;segment VII)	Antibiotic therapy. Surgical drainage.	Pus culture: <i>E. coli</i>	Good. Hospitalization= 21 days
Patient 20	24; M	Fever+ right upper-quadrant pain + vomiting for 2weeks. O/E: T°=39°C; gardening at palpation of the right upper-quadrant and epigastria with jaundice.	Leukocytes: 14300 Hepatic cytolysis and cholelasis	Ultrasound and CT scan: solitary abscess of liver (20 cm; segment V-VI-VII)	Antibiotic therapy. Surgical drainage and cholecystectomy.	Pus culture: Polymorphic bacterial flora	Good. Hospitalization= 10 days
Patient 21	55; M; duodenal ulcer none operated.	Fever + right upper-quadrant pain for 4 days. O/E: T°=39°C; gardening at palpation of the right upper-quadrant.	Leukocytes: 26600	Ultrasound and CT scan: solitary abscess of liver (9 cm; segment V)	Antibiotic therapy. Surgical drainage and cholecystectomy.	Pus culture: negative	Good. Hospitalization= 10 days
Patient 22	85; F	Fever+ right upper-quadrant pain + vomiting for 4weeks. O/E: T°=39.4°C; tenderness at palpation of the right upper-quadrant and epigastria with jaundice.	Leukocytes: 14000 CRP: 250 Hepatic cytolysis and cholelasis	Ultrasound and CT scan: solitary abscess of liver (14 cm; segment III-IV-VIII)	Antibiotic therapy. Surgical drainage and cholecystectomy.	Pus culture: Polymorphic bacterial flora	Good. Hospitalization= 28 days
Patient 23	46; M; diabetes.	Fever for 11 days. O/E: T°=39.4°C; abdomen: normal	Leukocytes: 14700 CRP: 133 Hepatic cytolysis	Ultrasound and CT scan: solitary abscess of liver (7 cm; segment V)	Antibiotic therapy. Percutaneous drainage.	Pus culture: Klebsiella	Good. Hospitalization= 15 days
Patient 24	73; F; duodenal ulcer none operated.	Fever+ right upper-quadrant pain for 5days. O/E: T°=39.5°C; tenderness at palpation of the right upper-quadrant and epigastria.	Leukocytes: 14300 CRP:33	Ultrasound and CT scan: two abscess of liver (segments III-V)	Antibiotic therapy. Percutaneous drainage.	-	Good. Hospitalization= 20 days

Table 1 Patients demographic data.

OBSERVATION	AGE (years); SEX; past history	Clinical Manifestations	Laboratory Tests	Imaging	Treatment	Bacteriology	Outcome
Patient 25	63; M hypertension; diabetes; dyslipidemia.	Fever+ pain in the right upper- quadrant +vomiting for 4 days. O/E: T°=39.4°C; painful mass at palpation of the right upper- quadrant.	Leukocytes: 10700 CRP: 38 Hepatic cytolysis	Ultrasound and CT scan: solitary abscess of liver (9 cm; segment VI) Colonoscopy: colic diverticulitis.	Antibiotic therapy. Percutaneous drainage.	Pus culture: Streptococcus.	Good. Hospitalization= 14 days
Patient 26	77; F hypertension; diabetes; dyslipidemia; chronic renal failure.	Fever+ right upper-quadrant pain for 4 weeks. O/E: T°=39°C; tenderness at palpation the right upper-quadrant.	Leukocytes: 17200 CRP: 535 Hepatic cytolysis	Ultrasound and CT scan: solitary abscess of liver (14 cm; segments IV-V-VI).	Antibiotic therapy. Percutaneous drainage:failed Surgical drainage cholecystectomy.	Pus culture: Klebsiella.	Good. Hospitalization= 30 days
Patient 27	65;F; diabetes; cholecystectomy with biliodigestive anastomosis	Fever+ right upper-quadrant pain for 7 days. O/E: T°=39°C; tenderness at palpation the right upper-quadrant.	Leukocytes: 14000 Hepatic cytolysis and cholelasis	Ultrasound and CT scan: solitary abscess (3.5 cm, segment IV) with thrombosis of portal vena.	Antibiotic therapy. Percutaneous drainage.	Pus culture: negative.	Good. Hospitalization= 23 days
Patient 28	21; F	Fever+ diffuses abdominal pain for 7 days. O/E: T°=39.°C; painful mass at palpation of the right upper-quadrant	Leukocytes: 12500	Ultrasound and CT scan: multiple abscess of liver.	Antibiotic therapy. Surgical drainage.	Pus culture: negative.	Good. Hospitalization= 12 days
Patient 29	63; M; diabetes.	Right upper-quadrant pain for 4 weeks with anorexia. O/E: T°=37.5°C; abdomen: normal.	Leukocytes: 10200	Ultrasound and CT scan: solitary abscess of liver (8.5 cm; segments V-VII-VIII).	Antibiotic therapy. Percutaneous drainage: failed Surgical drainage.	Pus culture: Staphylococcus.	Good. Hospitalization= 21 days
Patient 30	66; M; gastric ulcer; cholecystectomy with biliodigestive anastomosis for angiocholitis.	Fever+ vomiting with anorexia for 7 days. O/E: T°=39.4 °C; tenderness at palpation the right upper- quadrant.	Leukocytes: 16300 CRP: 156	CT scan: multiple abscess of liver with thrombosis of portal vena.	Antibiotic therapy. Percutaneous aspiration for pus culture.	Pus culture: Polymorphic bacterial flora.	Good. Hospitalization= 30 days
Patient 31	72; M	Fever+ right upper-quadrant and epigastric pain for 2weeks. O/E: T°=39°C; tenderness at palpation the right upper-quadrant.	Leukocytes: 9500 CRP: 108	Ultrasound and CT scan: solitary abscess of liver (segment V) with cholecystitis.	Antibiotic therapy. Surgical drainage and cholecystectomy.	Pus culture: Klebsiella.	Good. Hospitalization= 15 days
Patient 32	61; F; cholecystectomy with biliodigestive anastomosis.	Right upper-quadrant pain, epigastric pain for 7 days. O/E: T°=37.5°C; gardening at palpation of the right upper-quadrant.	Leukocytes: 9200 CRP: 182	CT scan: solitary abscess of liver (segment VI) intraductal papillary mucinous neoplasm.	Antibiotic therapy. Surgical drainage.	Pus culture: Polymorphic bacterial flora.	Good. Hospitalization= 21 days
Patient 33	69; F; hypertension cholecystectomy.	Right upper-quadrant pain, vomiting for 3 weeks. O/E: T°=37.7°C; gardening at palpation the right upper-quadrant and epigastria with jaundice.	Leukocytes: 13100 CRP: 320 Hepatic cytolysis and cholelasis	Ultrasound and CT scan: solitary abscess of liver (8 cm; segment IV).	Antibiotic therapy. Percutaneous drainage.	Pus culture: E. coli	Good. Hospitalization= 22 days
Patient 34	57; F; hypertension; diabetes; dyslipidemia.	Fever+ right upper-quadrant pain +vomiting with anorexia for 4 weeks. O/E: T°=39°C; tenderness at palpation the right upper- quadrant.	Leukocytes: 13500 CRP: 183	Ultrasound and CT scan: solitary abscess of liver (12 cm; segment IV) with cholecystitis.	Antibiotic therapy. Surgical drainage and cholecystectomy.	-	Good. Hospitalization= 19 days

disseminate and in the other case the abscess was associated with a cholecystitis). The mean size of abscess in the percutaneous drainage group was 8.7 cm (3.5 to 15 cm) and in more than 82% ($n=14$) of cases abscess was solitary.

Surgery was performed in 58.82% ($n=20$) of cases. Six patients had only surgical drainage of abscess and the other 14 patients had cholecystectomy with drainage of abscess (because of associated cholecystitis in 9 cases, gallbladder stone in 2 cases, or because the abscess involved segment V of liver in 3 cases).

The mean length of hospital stay was 19.7 days (range 6 to 62 days).

The outcome was generally favorable with the exception of one death from septic shock.

DISCUSSION

Pyogenic liver abscess is a rare but life threatening disease with the reported incidence ranging from 446 per 100,000 hospital admissions in some locations to 22 per 1,000,000 hospital admissions in others^[2,3]. In our series, the sex-ratio was 1.26 and confirmed the male predominance in many studies, for example Ali *et al* and Mangukiya *et al* had sex-ratio 1.5 and 4 respectively^[4,5]. Historically, liver abscess developed in young, otherwise healthy patients with an intra-abdominal infection. Ochsner *et al* and Mangukiya *et al* reported a peak incidence in the fourth decade^[5,6], but there is a gradual trend of increase in the age of patients with liver abscess, probably due to aggressive treatment of acute appendicitis and other intra-abdominal infections of the young which prevents the abscess from occurring which corresponded to the findings of Ali *et al* and our series (mean age 56 years and 64 years respectively). Patients who are immunocompromised or diabetic are especially prone to developing pyogenic liver abscess; diabetic persons have a 3.6 fold increased risk for developing pyogenic liver abscess compared with the general population^[7]. In our series, 47% of patients were holders of cardiovascular problems and 29.4% had diabetes.

Ochsner *et al* and Norman *et al*^[6,8] showed that clinical features of pyogenic liver abscess were non-specific. Many authors^[4,6,8,9,13] reported that the most significant clinical features of pyogenic liver abscess were upper abdominal pain with high grade fever and hepatomegaly as reported by our series.

In our series, laboratory tests revealed leukocytosis and elevated level of CRP in all cases and 23.5% of patients had hyperbilirubinemia. Mangukiya *et al* found total leukocytic count more than 11,000 in 78% of cases and hyperbilirubinemia in 12.5% of cases.

Consistent with other studies, CT scan was more sensitive than ultrasonography in the detection of liver abscesses, with 100% being clearly identified by CT scan^[10,11,13]. Pyogenic liver abscess is usually located in the right lobe of the liver as reported by our study. This predilection for the right lobe can be explained anatomically. The right hepatic lobe receives blood from the superior mesenteric vein via the right portal vein, whereas the left lobe receives inferior mesenteric and splenic drainage (There is a preferential blood supply to the right hepatic lobe through the large right branch of portal vein). It also contains a denser network of biliary canaliculi and, overall, accounts for more hepatic mass^[4,12,13]. In our study, PLA was solitary in the majority of cases, the same findings was reported by Ali *et al* and Mangukiya *et al*^[4,5] (54% and 56% respectively).

Inferior vena cava and/or hepatic vein thrombosis are infrequent but life-threatening complications of liver abscess. Budd Chiari syndrome or pulmonary embolism could cause rapid deterioration of these patients. Usually, it has been reported only in adult patients of

amebic liver abscess but BAGRI *et al* reported a case of inferior vena caval and right atrial thrombosis complicating pyogenic liver abscess in a young child^[14-16]. In our study, 3 cases of thrombosis of the portal vena or the inferior vena cava as a complication of pyogenic liver abscesses were reported.

Etiologically, PLA could have as origin a biliary tract, cryptogenic, portal pyemia or hematogenous origins. Consistent with our study, Ali *et al* found that the most common etiologies were biliary in 42% of cases then cryptogenic in 35% of cases and portal pyemia in 13%, but Mangukiya *et al* found that 56% of the total abscesses were cryptogenic in origin, while 15.5, 15, and 13.5% were of biliary, portal, and hematogenous in origin, respectively. Although it has been suggested that cryptogenic liver abscess is a sign of occult gastrointestinal malignancy, for that a screening colonoscopy should be performed in patients with cryptogenic liver abscess^[17].

Gram negative aerobes are found to be the major abscess pathogens in pyogenic liver abscess. *E. coli* is the most common pathogen in most of European studies, but in USA and Asian countries, other distributions are seen with high proportions of Klebsiella spp. (Especially, the highest incidence in Taiwan that ranges from 80% to 90% and a relatively low incidence of 30%-40% is estimated in the US). Diabetes has been found to be an important risk factor for Klebsiella liver abscess (KLA); up to 75% of patients with KLA in Asia have diabetes^[5,13,18,19]. In our study, pus culture study was performed in 28 cases of which 21 reports came with positive microbial reports (28.57% of cases were positive for *Escherichia coli* and 23.80% ($n=5$) shown Klebsiella of which 3 patients had diabetes. Other organisms were *Bacteroides* in 9.5%, *Staphylococcus* in 4.76% and *Streptococcus* in 4.76%. Polymorphic bacterial flora was found in 19% of cases).

In the past, liver abscesses were considered a clear indication for surgical drainage. In recent years, a more conservative approach has been adopted and needle aspiration or percutaneous continuous catheter drainage in combination with parenteral antibiotics is considered the gold standard treatment^[1,4,13,20,21]. The most commonly used antibiotics were fluoroquinolones, the third-generation cephalosporins with metronidazole and an aminoglycoside^[4,19,22]. Other combinations are proposed. The optimal duration intravenous therapy, as well as the duration of subsequent oral therapy, remains unclear. In the study of Taiwan, therapy generally consisted of 3 weeks of intravenous antibiotics followed by 1-2 months of oral therapy^[23]. However, a US study in 2004 indicated shorter courses of antibiotic therapy with durations of intravenous therapy of 17.5 days, and oral therapy of 13.6 days which were associated with extremely low mortality^[24]. This antibiotic therapy can be curative alone, in Mangukiya's study, 32% of patient were improved completely by antibiotic medication alone. In our study, all of patient had received intravenous antibiotic therapy (cephalosporin or fluoroquinolones combination with metronidazole and aminoglycoside) but only two patients were improved completely by this regime. The mean duration of intravenous antibiotic therapy was 15.5 days (range 5 to 30 days).

Percutaneous drainage has the advantages to simplify the treatment and avoid a general anesthesia and laparotomy; in addition, it can be helpful in determining the causative organisms and can shorten the duration of treatment. It includes percutaneous aspiration and percutaneous catheter drainage. Yu *et al* found that intermittent needle aspiration was probably as effective as continuous catheter drainage for the treatment of PLA^[25]. It's indicated in following situations^[4,19]: (1) Patients who continued to be febrile even after 48-72 h of adequate medical treatment; (2) Liver abscess more than 6 cm in size; (3) Clinical or ultrasonographic features suggesting impending perforation.

Success rate of percutaneous drainage is more than 90%. It has a low rate of complications which include hemorrhage, perforation of hollow viscera, peritoneal spillage, catheter displacement or blockage, and sepsis. Although complications of PCD are infrequent, the sequel can be serious therefore PCD should be performed under active monitoring of vital sign^[22]. In our study, percutaneous drainage was performed in 50% of cases and success rate was about 70%. The mean size of abscess in the percutaneous drainage group was 8.7 cm and in more than 82% of cases abscess was solitary. In the study of Mangukiya, among the catheter group, 91.66% of patients had solitary large abscess and the mean size of abscess was 11.5 cm.

Surgery drainage is carried out in patients falling within the criteria which are as follows^[19]: (1) Thick pus which could not be aspirated; (2) Patients with multiple liver abscesses; (3) Patients with ongoing sepsis even after antibiotic therapy and percutaneous drainage; (4) Patients with underlying diseases such as the biliary tract disease or the liver cirrhosis; (5) Multiloculated abscess; (6) Abscess in the left lobe; (7) Ruptured abscesses.

In our study, surgery was performed in 58.82% of cases because of biliary tract disease associated, multiple liver abscesses, left localization of abscess, or failure of PCD. Six patients had only surgical drainage of abscess and the other 14 patients had cholecystectomy with the drainage of the abscess.

In general, surgical drainage has been reserved for patients who fail to respond to treatment with percutaneous drainage and antibiotics or who have concurrent intra-abdominal pathology which requires surgical management. Thus, percutaneous and surgical techniques are not competing methods, but they have different indications, and surgery also represents an option for non-responders to percutaneous treatment^[26].

The mean length of hospital stay was 19.7 days (18.4 days for the PCD group, 20.36 days for the surgical management group and 21 days for the patients who are treated by antibiotic therapy alone). Ali *et al* report a mean length of hospital stay of 20±22 days (range: 1-82 days)^[5].

The outcome was generally favorable and the mortality rate in developed countries ranges from 2 to 12% and can be up to 19% in some series^[1,2]. Mangukiya *et al* and Ali *et al* report a rate of 1.5% and 2% respectively^[4,5], in our study the rate was 3%.

CONCLUSION

PLA is a rare condition but has undergone a huge change. It affects the subjects increasingly older. Bacteriologically, there is an emergence of Klebsiella in favor of Escherichia coli. Its treatment became less surgical thanks to the development of percutaneous drainage. Its outcome is generally favorable.

CONFLICT OF INTERESTS

There are no conflicts of interest with regard to the present study.

REFERENCES

- Alkofer B, Dufay C, Parienti JJ, Lepenne V, Dargere S, Chiche L. Are pyogenic liver abscesses still a surgical concern? A Western experience. *HPB Surg* 2012; **2012**: 316013
- Nasser A, Al Amer, Walid M. Abd El Maksoud. Abscess of the caudate lobe of the liver, a rare disease with a challenging management: a case report. *The Journal of Biomedical Research*, 2013; **27(5)**: 430-434
- Hope WW, Vrochides DV, Newcomb WL, Mayo Smith WW, Iannitti DA. Optimal Treatment of hepatic abscess. *Am Surg* 2008; **74**: 178-182
- Dhaval O. Mangukiya, Jitendra R. Darshan, Vijay K. Kanani, Saunabh T. Gupta. A Prospective Series Case Study of Pyogenic Liver Abscess: Recent Trends in Etiology and Management. *Indian J Surg* (September–October 2012) **74(5)**: 385-390
- Ahmad h ali, Roger D Smalligan, Mashrafi ahmed, Faisal a Khasawneh. Pyogenic liver abscess and the emergence of Klebsiella as an etiology: a retrospective study. *International Journal of General Medicine* 2014; **7**: 37-42
- Ochsner A, DeBakey M, Murray S. Pyogenic abscess of liver. II. An analysis of forty seven cases with review of literature. *Am J Surg* 1938; **40**: 292-319
- Thomsen RW, Jepsen P, Sorensen HT. Diabetes mellitus and pyogenic liver abscess: risk and prognosis. *Clin Infect Dis* 2007; **44**: 1194-1201
- Norman DC, Yoshikawa TT. Intra-abdominal infection: diagnosis and treatment in the elderly patient. *Gerontology* 1984; **30**: 327-328
- Miedema BW, Dineen P. The diagnosis and treatment of pyogenic liver abscess. *Ann Surg* 1984; **200(3)**: 328-334
- Halvorsen RA Jr, Foster WL Jr, Wilkinson RH Jr, Silverman PM, Thompson WM. Hepatic abscess: sensitivity of imaging tests and clinical findings. *Gastrointest Radiol*. 1988; **13(2)**: 135-141.
- Halvorsen RA, Korobkin M, Foster WL, Silverman PM, Thompson WM. The variable CT appearance of hepatic abscesses. *AJR Am J Roentgenol* 1984; **142(5)**: 941-946
- Albuquerque A, Magro F, Rodrigues S, Lopes S, Pereira P, Melo RB. Liver abscess of the caudate lobe due to Staphylococcus aureus in an ulcerative colitis patient: first case report. *J Crohns Colitis* 2011; **5**: 360-363
- Da Hye Yoon, Yeon Jin Jeon, E Young Bae, Dae Chul Jeong, Jin Han Kang. Liver abscess due to Klebsiella pneumoniae in a healthy 12-year-old boy. *Korean J Pediatr* 2013; **56(11)**: 496-499
- Hodkinson J, Couper-Smith J, Kew MC. Inferior vena caval and right atrial thrombosis complicating an amebic hepatic abscess. *Am J Gastroenterol* 1988; **83**: 786-788
- Huddle KR. Amoebic liver abscess, inferior vena-caval compression and the nephrotic syndrome. *S Afr Med J* 1982; **61**: 758-760
- NARENDRA BAGRI, DINESH YADAV AND A LOK HEMAL. Inferior Vena Caval and Right Atrial Thrombosis: Complicating Pyogenic Liver Abscess. *INDIAN PEDIATRICS JOURNAL* 2013; **50**: 701-702.
- Lai HC, Lin HC. Cryptogenic pyogenic liver abscess as a sign of colorectal cancer: a population-based 5-year follow-up study. *Liver Int* 2010; **30(9)**: 1387-1393
- Wang JH, Liu YC, Lee SS, Yen MY, Chen YS, Wann SR, Lin HH. Primary liver abscess due to Klebsiella pneumoniae in Taiwan. *Clin Infect Dis* 1998; **26(6)**: 1434-1438
- Yun Liu, Ji-yao Wang, and Wei Jiang. An Increasing Prominent Disease of Klebsiella pneumoniae Liver Abscess: Etiology, Diagnosis, and Treatment. *Gastroenterology Research and Practice* 2013; **2013**: 258514
- Nah BK, Kim YS, Moon HS, Park KO, Kim SM, Lee YS, Yang HW, Seo SW, Kim SH, Lee BS, Kim NJ, Lee HY. Recent changes of organism and treatment in pyogenic liver abscess. *Taehan Kan Hakhoe Chi* 2003; **9**: 275-83
- Ch Yu S, Hg Lo R, Kan PS, Metreweli C. Pyogenic liver abscess treatment with needle aspiration. *Clinical Radiol* 1999; **52**: 912-916
- Kwon JM, Hye Lim Jung, Jae Won Shim. Klebsiella pneumoniae liver abscess in an immunocompetent child. *Korean J Pediatr* 2013; **56(9)**: 407-410
- JH Wang, Y Liu, SS Lee et al. "Primary liver abscess due to Klebsiella pneumoniae in Taiwan," *Clinical Infectious Diseases* 1998; **26(6)**: 1434-1438
- Rahimian J, Wilson T, Oram V, Holzman RS. "Pyogenic liver abscess: recent trends in etiology and mortality," *Clinical Infectious Diseases* 2004; **39(11)**: 1654-1659
- Yu SCH, Ho SSM, Lau WY. "Treatment of pyogenic liver abscess:

Nasr B *et al.* Pyogenic abscess of liver

prospective randomized comparison of catheter drainage and needle aspiration," *Hepatology* 2004; **39**(4): 932-938

- 26 Malik AA, Bari SU, Rouf KA, Wani KA. "Pyogenic liver abscess: changing patterns in approach," *World Journal of Gastrointestinal Surgery* 2010; **2**(12): 395-401

Peer reviewers: Kazuhiro Hanazaki, Professor and Chairman, Department of Surgery, Kochi Medical School, Kochi University, Kohasu, Okocho, Nankoku, Kochi, 783-8505, Japan; Herwig Cerwenka, Department of Surgery, Medical University of Graz, Auenbruggerplatz 29, A-8036 Graz, Austria.