

Squamous Cell Carcinoma of the Pancreas with Liver Metastasis: Report of A Case and Review of Literature

Nejmeddine Affes, Amine Chhaidar, Mohamed Hammami, Waad Farhat, Foued Frikha, Hazem Ben ameur, Bassem Abid, Salah Boujelben, Fethi Derbel, Rafik Mzali

Nejmeddine Affes, Amine Chhaidar, Mohamed Hammami, Foued Frikha, Hazem Ben ameur, Bassem Abid, Salah Boujelben, Fethi Derbel, Rafik Mzali, Department of General Surgery, Habib Bourguiba Hospital, Sfax 3003, Tunisia

Waad Farhat, Fethi Derbel, Department of Surgery, University Hospital Sahloul, Sousse 4056, Tunisia

Correspondence to: Fethi Derbel, MD, Department of General Surgery, sahloul hospital, sousse. 4056. Tunisia.

Email: fethi.derbel@gmail.com

Telephone: +216 24 130 460

Received: October 12, 2013 Revised: September 18, 2014

Accepted: November 23, 2014

Published online: November 21, 2014

ABSTRACT

Context: Squamous cell carcinoma of the pancreas is a rare entity. The incidence has been estimated at approximately 1% of all pancreatic malignancies. The histogenesis is uncertain, but it has been proposed to originate from areas of squamous metaplasia of pancreatic ductal epithelium. Aims: We report a case of 68 years old patient with a liver metastatic squamous cell carcinoma of the pancreas. Histological diagnosis was established by CT guided biopsy of the liver. Two types of chemotherapy have been performed with an association of Gemcitabine and cisplatin. An objective response was obtained and the patient's health improved. Conclusion: Pure squamous cell carcinoma of the pancreas is a very rare malignancy. In most cases, it is not possible to make a preoperative histological diagnosis and curative resection is unlikely because of dissemination at the time of initial diagnosis or laparotomy.

© 2014 ACT. All rights reserved.

Key words: Squamous cell carcinoma; Pancreatic malignancies; Chemotherapy

Affes N, Chhaidar A, Hammami M, Farhat W, Frikha F, Ben ameur H,

Abid B, Boujelben S, Derbel F, Mzali R. Squamous Cell Carcinoma of the Pancreas with Liver Metastasis: Report of A Case and Review of Literature. *Journal of Gastroenterology and Hepatology Research* 2014; 3(11): 1360-1363 Available from: URL: <http://www.ghrnet.org/index.php/joghr/article/view/859>

INTRODUCTION

Squamous cell carcinoma of the pancreas is an extremely rare subtype of pancreatic cancer of ductal origin, with an incidence of 0.5 to 2% of all pancreatic malignancies^[1,2,3]. Normally, the pancreas is entirely devoid of squamous cells and hence the pathogenesis of this carcinoma remains uncertain^[3,4,5]. This carcinoma is poorly understood with respect to causation, risk factors, biologic behavior, and response to chemotherapeutic agents^[5]. Its prognosis remains poor, as for other pancreatic carcinoma^[3,6]. We present a case of Squamous cell carcinoma of the pancreas with liver metastasis treated with chemotherapy. A literature survey of this rare form is also provided.

CASE REPORT

A 68-year-old man presented to us with a colicky pain localized to the right upper abdomen. Epigastric and upper abdominal pain had been present intermittently for three months prior to the admission. This pain was accompanied by a history of dyspepsia and progressively increasing jaundice with clay-colored stools. There was no history of fever or pruritus. On physical examination, there was evidence for icterus without any palpable neck lymphadenopathy. The gallbladder was not palpable and no evidence was found for ascites or peripheral edema. Initial laboratory investigation revealed abnormal liver tests; bilirubin 60 µmol/L (reference: range: 0-17 µmol/L) alkaline phosphatase 2,563 IU/L (reference: range: 40-120 IU/L), and GGT 552 IU/L (reference: range: 0-150 IU/L). A chest X-ray examination showed no abnormality. Abdominal ultrasonography demonstrated multiple hypoechogenic liver nodules suggestive of secondary lesion. The pancreas could not be evaluated. Abdominal and chest computed tomography scan confirmed the presence of hypodense liver nodules

and a tumor of the tail of the pancreas hypodense and necrotic measuring 55×45 mm. A per-cutaneous biopsy of the liver metastasis showed metastatic well-differentiated SCC, no glandular components were seen (Figure 1). Results of a search for other possible primary SCC with a spiral CT scan of the thorax, neck, and nasopharynx were negative. Endoscopy of the upper gastrointestinal tract revealed no primary esophageal cancer. The diagnosis of pancreatic carcinoma with liver metastasis was strongly postulated. The patient had chemotherapy with gemcitabine and cisplatin for 7 weeks. Under the effect of this treatment, the pain quickly disappeared. Morphological assessment showed an objective decrease in the size of liver metastases and the pancreatic tumor. The general condition of the patient remains stable and he is still alive 28 months after diagnosis.

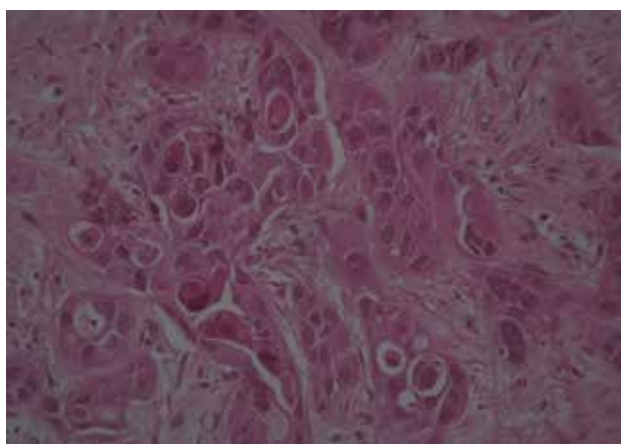


Figure 1 Histological section demonstrating a well-differentiated squamous-cell carcinoma of the pancreas without adenomatous features (HE, ×200).

DISCUSSION

The pancreas can be involved by a variety of neoplastic processes. Ductal carcinoma is the most common pancreatic cancer, and this classification is further subdivided into adenocarcinoma and SCC^[5]. The classic adenocarcinoma constitutes about 75% to 81% of all pancreatic cancers. SCC of the pancreas is very rare malignancy. According to the World Health Organization (WHO) classification, it represents a special form of adenosquamous carcinoma^[6,7]. It has various reported incidence rates, in seven large series, an average of 0.5% to 2% was reported^[1,8,9]. This discrepancy in the reported incidence rates can be explained in part by the fact that some of the cases represent adenosquamous carcinoma rather than pure SCC of the pancreas^[2,5].

Because of its rarity, SCC in the pancreas is presumed to be metastatic from another primary site, until proven otherwise. Appropriate radiographic and endoscopic evaluations are needed to rule out this possibility. However, it should be noted that the metastases to the pancreas are rare^[3,5,10].

We undertook a MEDLINE database search to identify cases of pure squamous cell carcinoma of the pancreas reported in the English literature and their management and outcomes using the following key words: carcinoma, squamous cell, pancreas, exocrine, pancreatic neoplasms. We have identified (Table 1) a total of 40 cases of pure squamous cell carcinoma of the pancreas, diagnosed based on histology findings, have been reported in the English literature^[3].

No specific known risk factors exist for the development of primary

SCC of the pancreas other than risk factors associated with the more common ductal adenocarcinoma. Multiple theories have been postulated to explain the development of pancreatic specimen cell carcinoma. These include^[3,5,11,12,13]: (1) A primitive cell capable of differentiating into either Squamous or glandular carcinoma undergoes malignant change; (2) A pre-existing adenocarcinoma undergoes squamous changes; (3) An aberrant squamous cell undergoes a malignant change; (4) A malignant transformation of squamous metaplasia, secondary to chronic inflammation.

During periods of inflammation such as pancreatitis, squamous metaplasia of the ductal columnar cells can be observed. Squamous metaplasia of the pancreatic duct is found in 9%-64% of pancreas routinely examined at necropsy^[14]. Despite this frequency of squamous cell metaplasia, its transformation to SCC is a rare event^[2,12].

Observations of squamous carcinoma listed in the literature have for most been documented by the anatomic-pathological exam of an autopsy or surgical specimen. For many authors, the diagnostic of squamous carcinoma can only be put after multiples cut and colorations to eliminate all glandular components^[5,13,15]. However, it does not appear to exist clear consensus on the histological analysis method. Thus, the over estimate of the incidence rate of the squamous carcinoma is possible. In our presentation, the absence of histological analysis of the pancreas tumor does not permit to separate a mixed pancreatic tumor of which only the squamous component is metastatic in liver.

The clinical presentation of SCC is similar to that of adenocarcinoma with patient presenting with upper abdominal and back pain, anorexia, weight loss, nausea vomiting, and obstructive jaundice^[6,12,16,17]. In some cases, hypercalcemia or tarry stool also occurred as a main feature^[16,18]. One of the unusual presentations is upper gastrointestinal bleeding and melena secondary to gastric invasion^[16]. The anatomic head, tail, and body of the pancreas seem to be affected equally by SCC^[9,19,20]. The mean tumor size as reported by brown *et al* in the review of 25 cases with detailed data was 7.8 cm^[9]. No specific laboratory investigation is helpful in the diagnostic or monitoring of pancreatic squamous cell carcinoma^[5,6].

Approximately 95% of patients show evidence of disseminated or locally metastatic diseases at the time of initial evaluation or laparotomy, with the regional lymph nodes, liver, lung and bones being most commonly targeted^[19,21].

Two radiographic features: enhancement of the tumor on contrast CT and tumor blush patterns on angiography have been reported to aid in the differentiation of pancreatic squamous cell carcinoma and classical ductal adenocarcinoma. Both of these radiographic phenomena are probably a result of the hypervascularity of squamous cell carcinoma^[11,18,22,23]. Although this finding is unusual in typical adenocarcinoma of the pancreas, hypervascularity can be seen with cystadenoma, cystadenocarcinoma, islet cell tumors, angiosarcoma, and hemangiomas.

Histology findings characteristic of SCC of pancreas frequently reported in the literature include keratinization with eosinophilic cytoplasm on hematoxylin and eosin staining, the formation of whorls or “pearls” with intracellular bridges, and irregularly shaped nests and cords of epithelial cells^[5].

Desmoplastic response secondary to ductal obstruction may be a prominent feature^[18,19]. No criteria exist for the cytologic distinction of metastatic from primary pancreatic squamous cell carcinoma^[24] and this situation again emphasizes the importance of searching for another primary source by an extensive workup including exploration of head, neck, lung, and esophagus.

Several options for treating pancreatic squamous cell carcinoma

Table 1 Reported cases of squamous cell carcinoma of the pancreas in the literature.

Author/reference	Year	No. of patients reported	Age	Sex	Race	Presenting symptom(s)	Location	Size	Surgery	Outcome	Treatment	Time to death (months)
Kensuke ^[2]	2011	1	67	F	Japanese	Anorexia, back pain	Tail	6 cm	Distal pancreatectomy, total gastrectomy, splenectomy.	LR at four months	Radiotherapy for LR	11 months from S
Mansfield <i>et al</i> ^[3]	2010	8	64 (median)	6M+2F	NA	Jaundice (4/8), abdominal discomfort (3/8), back pain (1/8), early satiety (1/8)	NA	NA	1 (S), 1(S+R), 3(S+R+C), 1(C), 2 (P)	NA	NA	Median five months
Terada ^[4]	2010	1	69	F	Japanese	Abdominal pain, jaundice	Head	5 cm	Pancreatoduodenectomy	Distant metastasis	Nil	Three months
Lai <i>et al</i> ^[5]	2009	1	76	F	African-American	Epigastric/back pain, weight loss	Tail	5cm	Cytological diagnosis, no histology	Liver metastasis at diagnosis	Not known	Not known
Rana <i>et al</i> ^[6]	2009	1	50	M	NA	Abdominal pain, jaundice, weight loss	Head	NA	No surgery, cytological diagnosis, no histology	Peritoneal deposits, ascites at diagnosis	Nil	Not known
Qiang-pu <i>et al</i> ^[7]	2008	1	55	M	Mandarin Chinese	Jaundice, weight loss	Head	4 cm	Pancreatoduodenectomy and segmental liver resection	Liver metastasis at 10 months	Nil	10 months
Al-Shehri <i>et al</i> ^[8]	2008	1	48	F	NA	Abdominal pain, jaundice, weight loss	Head	4.4 cm	Palliative bypass surgery	Liver metastasis at diagnosis	Carboplatin+gemcitabine (two courses)	Five months OS from presentation
Aragnotopoulos <i>et al</i> ^[9]	2006	1	72	M	NA	Painless jaundice	Head	6 cm	Palliative bypass surgery		Nil	Four months
Brown <i>et al</i> ^[10]	2005	1 (plus 24 case literature review)							As published in literature			
Fonseca <i>et al</i> ^[11]	2000	1	52	M	NA	Melena, jaundice	Head	NA	No surgery, cytological diagnosis, confirmed histology at autopsy	Liver metastasis at diagnosis	Nil	712 days

S: Surgery; R: Radiotherapy, C: Chemotherapy; P: Palliative care; LR: Local relapse; OS: Overall survival; NA: Not available.

are described in the literature. They include surgical resection, chemotherapy, with curative resection being the best therapeutic option in the appropriate setting. In most cases (more than 80%), curative resection of the tumor is impossible because of dissemination and/or metastasis at the time of initial evaluation or laparotomy. Some investigators report a better response to chemotherapy based on gemcitabine^[13,14], and some patients seem to have a “benign” course^[25]. Although the few reports of the use of chemotherapeutic agents including an objective response to gemcitabine in unresectable tumors, the response to various chemotherapeutic agents as well as radiotherapy is not encouraging and the prognosis of this malignancy remains poor^[2,9,13]. The literature on SCC has reported a variety of median survivals, with one study showing a median survival of 7 months (range: 6-16 months) for patients who underwent curative resection and three months (range: 0.25-9 months) for patient who did not undergo curative resection^[9,12]. One-year and 5-year survival rates of 5% and 1% respectively, in most of reports render the prognosis of this cancer even worse than that of the usual adenocarcinoma^[1,11,25]. Virtually all reported cases were locally advanced or metastatic on the patient’s initial presentation.

CONCLUSION

Squamous cell carcinoma of the pancreas is a rare malignancy. Outside of some morphological features, clinical presentation is the same that adenocarcinoma. A curative or palliative surgical treatment must be performed when the tumoral extension and the patient’s general state permit it. Otherwise, the use of chemotherapy as the gemcitabine may give an improvement of the survival or even an objective response in an exceptional way.

CONFLICT OF INTERESTS

There are no conflicts of interest with regard to the present study.

REFERENCES

- Baylor SM, Berg JW. Cross-classification and survival characteristics of 5,000 cases of cancer of the pancreas. *J Surg Oncol* 1973; **5**: 335-338
- Anagnostopoulos GK, Aithal GP, Ragunath K, Kaye P, Rowlands BJ. Squamous cell carcinoma of the pancreas: report of a case and review of the literature. *JOP J Pancreas* 2006; **7**: 47-50
- Ravi Kodavatiganti, Fiona Campbell, Ahmed Hashmi, Simon W Gollins. Primary squamous cell carcinoma of the pancreas: a case report and review of the literature. *Journal of Medical Case Reports* 2012; **6**: 295
- George Zacharia, Justin Levine, Nathaniel S. Winstead, Mainor R. Antillon, Nancy K. Davis. Primary Squamous Cell Carcinoma of the Pancreas Diagnosed by Endoscopic ultrasound-Guided Fine Needle Aspiration. *J Gastrointest Liver Dis September* 2012; **21(3)**: 321-323
- Al-Shehri A, Silverman S, King KM. Squamous cell carcinoma of the pancreas. *Current oncology* 2008; **15(6)**: 293-297
- CHEN QP, OU K, GUAN Q, ZHANG F. Squamous cell carcinoma of the pancreas with liver metastasis: a case report. *Chinese Medical Journal* 2008; **121(9)**: 853-854
- Kloppel G, Solcia E, Longnecker DS, Capella C, Sobin LH. Histological typing of tumors of the exocrine pancreas. In: World Health organization. International Histological Classification of Tumors. 2nded. Berlin, Heidelberg, New York: Springer; 1996: 15-21
- Halpert B, Makk L, Jordan GL Jr. A retrospective study of 120 patients with carcinoma of the pancreas. *Surg Gynecol Obstet* 1965; **121**: 91-96
- Brown HA, Dotto J, Robert M, Salem RR. Squamous cell carcinoma of the pancreas. *J Clin Gastroenterol* 2005; **39**: 915-919
- Kensuke Adachi. Primary Squamous Cell Carcinoma of the Pancreas: A Case Report. *Journal of the Pancreas* 2011; **12(2)**: 181-184
- NAKASHIMA H, HAYAKAWA T, HOSHINO M, KAMIYA Y, OHARA H, YAMADA T, MIZUNO K, INAGAKI T, NAKAZAWA T, YAMADA H, MIYAJI M, TAKEUCHI T. Squamous cell carcinoma of the pancreas with massive invasion of the retroperitoneum. *Intern Med* 1995; **34**: 61-64
- Abby LM, Peter SY, Charles C. Less common neoplasms of the pancreas. *World J Gastroenterol* 2006; **12(20)**: 3180-3185
- Bideau K et al. Treatment of squamous cell carcinoma of the pancreas with gemcitabine. *Gastroenterol Clin Biol* 2006; **30**: 1217-1220
- Sears HF, Kim Y, Strawitz J. Squamous cell carcinoma of the pancreas. *J Surg Oncol* 1980; **14**: 261-265
- Kubota K, Mori M, Ishihara T, Kokuho M. Squamous cell carcinoma of the pancreas accompanied by mucinous cystadenocarcinoma: a case report of unusual association. *Pancreas* 1997; **14**: 99-101
- Minami T, Fukui K, Morita Y, Kondo S, Ohmori Y, Kanayama S, Taenaka N, Yoshikawa K, Tsujimura T. A case of squamous cell carcinoma of the pancreas with an initial symptom of tarry stool. *J Gastroenterol Hepatol* 2001; **16**: 1007-9.
- Surinder SR, Bhasin DK, Jain K, Nada R, Sinha SK, Singh K. Endoscopic diagnosis of squamous cell carcinoma of the pancreas invading the stomach. *Journal of the pancreas* 2009; **10(2)**: 181-183.
- Brayko CM, Doll DC. Squamous cell carcinoma of the pancreas associated with hypercalcemia. *Gastroenterology* 1982; **839**: 1297-1299
- Itani KM, Karni A, Green L. Squamous cell carcinoma of the pancreas. *J Gastrointest Surg* 1999; **3**: 512-515
- Mulkeen AL, Yoo PS, Cha C. Less common neoplasms of the pancreas. *World J Gastroenterol* 2006; **12**: 3180-3185
- Bringel RW, Souza CP, Araújo SE, Lopasso FP, Gama-Rodrigues J, Pinotti HW, Laudanna AA. Squamous cell carcinoma of the pancreas with gastric metastasis. Case report. *Rev Hosp Clin Fac Med Sao Paulo* 1996; **51**: 195-197
- Figardo LL, Yoshino MT, Chernin MM. Computed tomography findings in squamous cell carcinoma of the pancreas. *J Comput Tomogr* 1988; **12**: 138-139
- Koduri VG, Ravi TJ. Squamous cell carcinoma of the pancreas: report of a case and review of ERCP findings. *Endoscopy* 1994; **26**: 333-334
- Layfield LJ, Cramer H, Madden J, Gopez EV, Liu K. Atypical squamous epithelium in cytologic specimens from the pancreas: cytological differential diagnosis and clinical implications. *Diagn Cytopathol* 2001; **25**: 38-42
- Beyer KL, Marshall JB, Metzler MH, Poulter JS, Seger RM, Diaz-Arias AA. Squamous cell carcinoma of the pancreas. Report of unusual case and review of the literature. *Dig Dis Sci* 1992; **37**: 312-318

Peer reviewers: Changsong Zhang, Clinical Oncology Laboratory, Changzhou Tumor Hospital, Soochow University, No.1 North huaide Road, Changzhou, China; Isidoro DI CARLO, Associate Professor of Surgery (Prof. Aggr.), Department of Surgical Sciences OT and AT, University of Catania, Cannizzaro Hospital, Via Messina 829, 95125, Catania.