

Journal of Gastroenterology and Hepatology Research

Online Submissions: <http://www.ghrnet.org/index./joghr/>
doi: 10.6051/j.issn.2224-3992.2012.01.028

Journal of GHR 2012 April 21 1(3): 36-39
ISSN 2224-3992 (print) ISSN 2224-6509 (online)

ORIGINAL ARTICLE

Liver Resection for Hepatocellular Carcinoma in Patients with Cirrhosis: Radiofrequency-Assisted versus Cavitron Ultrasonic Surgical Aspirator

Ke-Fei Chen, Han-Teng Yang, Wei-Hong He, Hong-Yu Li, Yong-Gang Wei, Bin Huang, Bo Li

Ke-Fei Chen, Wei-Hong He, Hong-Yu Li, Yong-Gang Wei, Bin Huang, Bo Li, Division of Liver, Department of Surgery, West China Hospital, Sichuan University, Chengdu, Sichuan Province, China
Han-Teng Yang, Division of Liver, Department of Surgery, Wu Wei Tumor Hospital, Gansu Province, China

Correspondence to: Bo Li, Department of Surgery, Division of Liver Transplantation, West China Hospital, Sichuan University, 37 Guo Xue Rd, Chengdu 610041, Sichuan Province, China. boli2011@163.com

Telephone: +86-28-85422476 Fax: +86-28-85423724

Received: December 7, 2011 Revised: January 7, 2012

Accepted: January 14, 2012

Published online: April 21, 2012

ABSTRACT

AIM: To compare the early postoperative results between Radiofrequency (RF)-assisted and Cavitron Ultrasonic Surgical Aspirator (CUSA) liver resection for HCC in patients with cirrhosis.

METHODS: 18 cirrhotic patients who underwent RF-assisted liver resection for HCC were compared with 18 cirrhotic patients who underwent CUSA liver resection. The two groups were well matched for age, gender, tumor size, and severity of cirrhosis. (Child-Pugh A).

RESULTS: The mean Intraoperative blood loss (RF, 58±61 mL; vs CUSA, 197±75 mL; $p=0.001$) was statistically less for the RF-assisted group. The mean hospital stay is shorter in the RF-assisted group (RF-assisted, 7±2 days; vs CUSA, 10±3 days; $p=0.02$).

CONCLUSIONS: RF-assisted liver resection for HCC in properly selected cirrhotic group showed less intraoperative blood loss and shorter hospital stay than the CUSA group.

© 2012 Thomson research. All rights reserved.

Key words: Radiofrequency; Liver resection; Hepatocellular carcinoma; Liver cirrhosis

Chen KF, Yang HT, He WH, Li HY, Wei YG, Huang B, Li B. Liver Resection for Hepatocellular Carcinoma in Patients with Cirrhosis: Radiofrequency-Assisted versus Cavitron Ultrasonic Surgical Aspirator. *Journal of Gastroenterology and Hepatology Research* 2012; 1(3): 36-39 Available from: URL: <http://www.ghrnet.org/index./joghr/>

INTRODUCTION

Hepatocellular carcinoma (HCC) is considered the fifth most

common and the third most lethal malignant tumor in the world, and the morbidity and mortality rates of HCC are high^[1,2]. Over 80% patients with HCC are complicated with liver cirrhosis or chronic hepatitis due to infection of hepatitis B virus (HBV) or hepatitis C virus (HCV)^[2-4]. Surgical liver resection is the primary treatment method for HCC. However, blood loss during surgery poses a major challenge to surgeons as intraoperative bleeding affects prognosis and mortality^[5]. Moreover, liver resection for HCC in cirrhotic patients with esophageal varices (EV) may increase the risk of perioperative bleeding and liver failure^[6-8]. Therefore, portal hypertension has been considered a contraindication for hepatic resection in cirrhotic patients with HCC by many surgeons.

Radiofrequency ablation (RFA) has been widely used for unresectable HCC and favorable long-term outcomes have been observed in some cases^[9]. RF-assisted liver resection was firstly described by Habib's group who applied a single needle probe to deploy RFA energy before liver resection, and the mean blood loss during the surgery significantly decreased to 30±10 mL in 15 patients^[10]. Since then, this technique has been used in different medical centers and good prognosis has been observed^[10-16]. However, short-term outcomes after RF-assisted liver resection for HCC in patients with cirrhosis are still unclear.

The aims of this study were using this technique to reduce intraoperative blood loss during liver resection for HCC in cirrhotic patients and investigating the short-term results.

PATIENTS

Between May 2010 and August 2010, 36 cirrhotic patients with HCC underwent liver resection. Of these 36 cases, 18 patients underwent RF-assisted liver resection (RF-assisted group) while the other 18 patients underwent liver resection (CUSA group). All these cohorts have tumors less than 5 cm in diameter and lack intrahepatic metastasis as conformed by preoperative ultrasound, spiral computed tomography and intraoperative ultrasound. The diagnosis of HCC and underlying Child A cirrhosis were conformed by histological examination in these patients. Preoperative preparation was the same as the normal liver resection, including serum biochemistry examination, indocyanine green clearance test, spiral computed tomography or magnetic resonance imaging and exclusion of unresectable extrahepatic diseases. Signed-consent forms were obtained according to the Declaration of Helsinki from all subjects that participated in this study. The protocol of this study was approved

by the Ethical Committee of the West China Hospital in Sichuan University.

Methods

We used the Valleylab Cool-tip™ RF Multiple Switching controller 3 electrodes ablation system (USA, Valleylab, Boulder CO) to deploy pulsed radiofrequency current during operation in the RF-assisted group. The 3 electrodes were arranged in line at 1cm intervals (Figure 1 A and B). Before resection, the electrodes were inserted into the liver with a depth of 2 cm, and then four steps were carried out to apply RF-assisted liver resection. In step 1, intraoperative ultrasound was performed and an inner line was made on liver surface with diathermy to mark the resection margin. In step 2, an outer line was made 1 cm outside the inner line to mark the location where coagulative necrosis would be achieved with RFA electrodes. In step 3, radiofrequency current was deployed along the outer line and coagulative necrosis was obtained. During this procedure, saline was used to cool the electrodes. In step 4, each application of RFA was deployed 3 to 5 min to obtain a necrotic zone. The liver was transected along the necrotic zone with scalpel. In the CUSA group, the patients underwent normal liver resection by using CUSA (US, Valleylab, Boulder CO) to remove the diseased sections. In our experiments, portal vein obstruction was not performed. The volume of resected liver, the operative time and the intraoperative blood loss were recorded.

RESULTS

Baseline characteristics of the study participants were listed in Table 1. The mean age of the patients was 57 years (range 42 to 73 years) and the patients were comprised of 30 men and 6 women. Diagnosis of all the patients was conformed by histological examination. In the RFA group, anterior right lobes ($n=10$), posterior right lobes($n=3$), left hemiliver($n=1$), left lateral lobe($n=4$), were performed (Figure 1 C,D,EandF), as compared with anterior right lobes($n=8$), posterior right lobes($n=4$), left hemiliver($n=2$), left lateral lobe($n=4$) in the CUSA group. The resected volumes of the RF-assisted group and the CUSA group were $103\pm 37\text{ cm}^3$ and $118\pm 36\text{ cm}^3$, respectively, and no than that in the CUSA group ($42\pm 10\text{ min}$ vs $76\pm 50\text{ min}$ $p=0.04$). The

intraoperative blood loss significantly differ between the RF-assisted statistically significant difference was found between the two groups. The operative time was significantly shorter in the RF-assisted group and the CUSA group ($58\pm 61\text{ mL}$ and $197\pm 75\text{ mL}$ $p=0.001$). None of the patients in the RF-assisted group required intraoperative blood transfusion whereas 4 patients in CUSA group did require intraoperative blood transfusion (RF-assisted, 0%; vs CUSA, 22.2%; $p=0.05$). Serum AST levels were significantly higher in the RF- assisted

Table 1 Clinical details of RF-assisted and CUSA liver resection groups

	RF-assisted <i>n</i> =18	CUSA <i>n</i> =18	<i>P</i> value
Preoperation			
Age(years)	57±9	56±7	0.82
Male/Female	14/4	16/2	0.24
Maximum tumor diameter(cm)	4.1±0.8	3.9±0.7	0.57
ICG-R15(%)	11±2.8	13±3.1	0.75
TB (mg/dL)	23±6	22±8	0.8
ALT(U/L)	49±18	42±11	0.29
ALB(g/L)	34±2	36±3	0.83
HbsAg(+)	16	17	0.39
AFP(+)	12	14	0.22
EV(+)	10	8	0.21
Mild to moderate liver cirrhosis	15	17	0.25
Operation			
Resected hepatic Volume(cm^3)	103±37	118±36	0.25
Operation time(min)	42±10	76.8±51	0.03
Bleeding(mL)	58±61	197±75	0.001
Postoperation			
TB (mg/dL)	36±15	39±13	0.57
ALT(U/L)	223±91	128±55	0.001
ALB(g/L)	31±4	29±3	0.4
Biliary leaks(+)	1	0	0.5
hospital stay(days)	7±2	10±3	0.02
1-year overall survival rates (%)	83.3	88.9	0.33

Abbreviations: ICG-R15: The retention rate of indocyanine green at 15 min; ALT: Alanine aminotransferase; TB: Total bilirubin; ALB: albumin; AFP: Alpha fetoprotein ; EV: Esophageal varices; RF:Radiofrequency; CUSA: Cavitron Ultrasonic Surgical Aspirator.

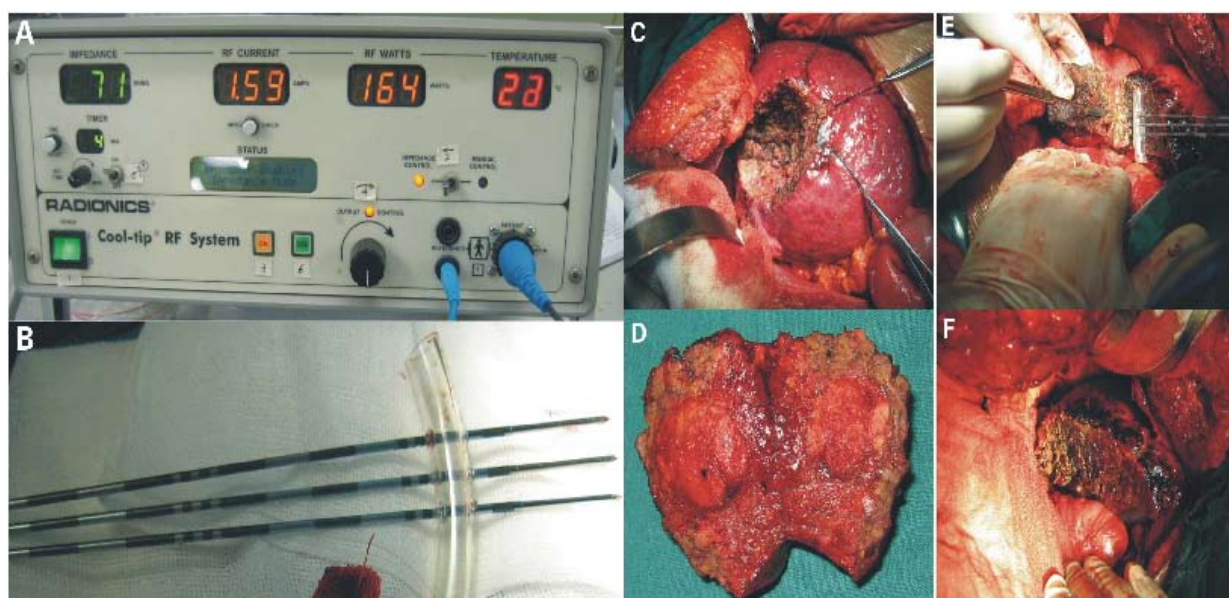


Figure 1 A: The Valleylab Cool-tip™ RF Multiple Switching controller 3 electrodes ablation system; B: The 3 electrodes were arranged in line and the interval between nearby electrodes was 1cm; C, D and E, F: hepatic resection in posterior and anterior right lobes by RF-assisted liver resection.

group than those in the CUSA group on the 3d postoperation (RF-assisted, 223 ± 91 U/L; vs CUSA, 123 ± 55 U/L; $p=0.001$), but they decreased to normal level in one week. No difference were observed in Postoperative TB and ALB levels between the two groups. Postoperative bile leakage occurred in 1 patient in the RF-assisted group and healed spontaneously 10d postoperation. The mean length of hospital stay of the RF- assisted group was shorter than the that of the CUSA group (RF-assisted, 7 ± 2 days; vs CUSA, 10 ± 3 days; $p=0.02$). The 1-year overall survival rates for the RF-assisted group and the CUSA group after hepatic resection were 83.3% and 88.9%, respectively, and the difference was not statistically significant ($P=0.35$, Table1).

DISCUSSION

In clinical management of HCC and surgical liver resection, the factors including tumor and cirrhosis should be both evaluated since about 80% HCC cases are accompanied by cirrhosis in China, and overall survival rate and recurrence rate should be primarily considered as censor because any treatment would be meaningless if it reduced the survival rate^[17]. Cirrhosis and EV may increase intraoperative blood loss in liver resection for HCC. Although portal vein obstruction can reduce bleeding during surgery, it may cause liver ischemia which would result in postoperative liver failure. By using CUSA, liver resection can be performed without occluding portal vein. However, cirrhosis may increase liver stiffness, which would increase liver resection time and blood loss during CUSA. In our study, applying RF-assisted liver resection significantly reduced blood loss, avoided portal vein occlusion and prevented ischemia-reperfusion damage to residual liver. Therefore, RF-assisted liver resection has a promising future in liver resection for HCC patients with cirrhosis and EV.

In this study, all the tumors were smaller than 5 cm in diameter and the resected liver volumes were similar between groups. Postoperative complications such as bile leakage, hemorrhage, and wound inflammation were rare. Although serum AST levels in the RF-assisted liver resection group were significantly higher than those in the CUSA group on the 3rd postoperation, they decreased to normal level rapidly in one week. Heat injury around the necrotic region caused by RF may be the reason of temporary increase of serum AST levels, and the amount of heat produced by RF determined the damage levels. The larger the tumor was, the more RF energy deployed and the more residual liver damage occurred. Therefore, the severity of cirrhosis and the volume of residual liver should be carefully evaluated^[18]. If excess liver was resected in the surgery, the risk of postoperative liver failure would be increased due to weak regenerative capability of cirrhotic liver. We strongly recommend that cirrhotic level of tumor should be ascertained strictly before operation and the periphery of tumor should be marked precisely before resection by using intraoperative ultrasound. Moreover, achieving a 1 cm width necrotic zone surrounding the tumor can reduce the unnecessary loss of residual liver without increasing the risk of residual tumor presence.

Recently, attention has been increasingly given to the intraoperative blood loss and perioperative blood transfusion which have been considered to be closely associated with HCC recurrence^[19,20]. In this study, no significant differences were observed in the 1-year overall survival rates between the RF-assisted liver resection group and the CUSA group. The cancer cells in the paratumor liver tissues may be killed by the heat produced by the RF, which may result in the similar short-time survival rates between the two groups. However, the long-time outcomes are still unclear and further investigation is needed.

In conclusion, HCC, which smaller than 5 cm in diameter, can be resected by using RF-assisted liver resection with shorter operative time, less blood loss and shorter hospital stay. Although RF-assisted liver resection therapy temporarily increased serum AST levels, it did not affect the recovery of the patients, and the early postoperative complications and the 1-year overall survival rate were the same for RF-assisted liver resection and the CUSA groups.

ACKNOWLEDGMENTS

We thank Dr. Lu-Nan Yan (Department of Surgery, West China Hospital, Sichuan University) for the assistance of data collection and Ding Yuan for data analysis.

REFERENCES

- 1 Roxburgh P, Evans TR. Systemic therapy of hepatocellular carcinoma: are we making progress? *Adv Ther* 2008;**25**: 1089-1104
- 2 Lee TK, Castilho A, Ma S, Ng IO. Liver cancer stem cells: implications for a new therapeutic target. *Liver Int* 2009;**29**: 955-965
- 3 de Franchis R, Hadengue A, Lau G, Lavanchy D, Lok A, McIntyre N, et al. EASL International Consensus Conference on Hepatitis B. Consensus statement. *J Hepatol* 2003; **39**: S3-25
- 4 Fattovich G. Natural history and prognosis of hepatitis B. *Semin Liver Dis* 2003; **23**: 47-58
- 5 Nagorney DM, Van Heerden JA, Ilstrup DM, Adson MA. Primary hepatic malignancy: surgical management and determinants of survival. *Surgery* 1989, **106**: 740-748
- 6 Oh JW, Ahn SM, Kim KS, Choi JS, Lee WJ, Kim BR. The role of splenectomy in patients with hepatocellular carcinoma and secondary hypersplenism. *Yonsei Med J* 2003, **44**: 1053-1058
- 7 Bruix J, Castells A, Bosch J, Feu F, Fuster J, Garcia-Pagan JC, Visa J, Bru C, Rodés J. Surgical resection of hepatocellular carcinoma in cirrhotic patients: prognostic value of preoperative portal pressure. *Gastroenterology* 1996, **111**: 1018-1022
- 8 Bruix J, Sherman M, Llovet JM, Beaugrand M, Lencioni R, Burroughs AK, Christensen E, Pagliaro L, Colombo M, Rodés J. EASL Panel of Experts on HCC Clinical management of hepatocellular carcinoma. Conclusions of the Barcelona-2000 EASL conference. European Association for the Study of the Liver. *J Hepatol* 2001, **35**: 421-430
- 9 Machi J, Bueno Rs, wong LL. Long-term follow-up outcome of patients undergoing radiofrequency ablation for unresectable hepatocellular carcinoma. *World J Surg* 2005, **29**: 1364-1373
- 10 Weber JC, Navarra G, Jiao LR, Nicholls JP, Jensen SL, Habib NA. New technique for liver resection using heat coagulative necrosis. *Ann Surg* 2002, **236**: 560-563
- 11 Navarra G, Lorenzini C, Curro G, Sampiero G, Habib NH. Radiofrequency-assisted hepatic resection—first experience. *Ann Ital Chir* 2004, **75**: 53-56
- 12 Tepel J, K10mp HJ, Habib N, Fändrich F, Kremer B. Modification of the liver resection technique with radiofrequency coagulation. *Chirurg* 2004, **75**: 66-69
- 13 Navarra G, Lorenzini c, Curro G, Basaglia E, Habib NH. Early results after radiofrequency assisted liver resection. *Tumori* 2004, **90**: 32-35
- 14 Gananadha S, Morris DL. Novel in-line multielectrode radiofrequency ablation considerably reduces blood loss during liver resection in an animal model. *ANZ J Surg* 2004, **74**: 482-485
- 15 Haghghi Ks, wang F, King J, Daniel S, Morris DL. In-Line

- radiofrequency ablation to minimize blood loss in hepatic parenchymal transection. *Am J Surg* 2005, **190**: 43-47
- 16 Haghghi Ks, Steinke K, Hazratwala K, Kam PC, Daniel S, Morris DL. Controlled study of inline radiofrequency ablation (ILRFA) assisted transection of ovine liver. *J Surg Res* 2005, **123**: 139-143
 - 17 Llovet JM, Di Bisceglie AM, Bruix J, Kramer BS, Lencioni R, Zhu AX, Sherman M, Schwartz M, Lotze M, Talwalkar J, Gores GJ. Design and endpoints of clinical trials in hepatocellular carcinoma. *J Natl Cancer Inst* 2008, **100**: 698-711
 - 18 Chen YJ, Yeh SH, Chen JT, Wu CC, Hsu MT, Tsai SF, Chen PJ, Lin CH. Chromosomal changes and clonality relationship between primary and recurrent hepatocellular carcinoma. *Gastroenterology* 2000, **119**: 431-440
 - 19 Yamamoto J, Kosuge T, Takayama T, Shimada K, Yamasaki S, Ozaki H, Yamaguchi N, Makuuchi M. Recurrence of hepatocellular carcinoma after surgery. *Br J Surg* 1996, **83**: 1219-1222
 - 20 Asahara T, Katayama K, Itamoto T, Yano M, Hino H, Okamoto Y, Nakahara H, Dohi K, Moriwaki K, Yuge O. Perioperative blood transfusion as a prognostic indicator in patients with hepatocellular carcinoma. *World J Surg* 1999, **23**: 676-680

Peer reviewers: Prof. Luis Rodrigo, Department of Gastroenterology University Hospital Central of Asturias, c/ Celestino Villamil s. n.º, 33.006, Oviedo, Spain.