



Journal of

Gastroenterology and Hepatology Research

Online Submissions: <http://www.ghrnet.org/index./joghr/>
doi:10.6051/j.issn.2224-3992.2014.03.374

Journal of GHR 2014 February 21 3(2): 963-967
ISSN 2224-3992 (print) ISSN 2224-6509 (online)

REVIEW

Role of Clips in Therapeutic Endoscopy: A Review

Diego Sánchez-Muñoz, Carlos Ortiz-Moyano, Blas Gómez-Rodríguez

Diego Sánchez-Muñoz, Carlos Ortiz-Moyano, Blas Gómez-Rodríguez. Digestive Diseases Department, Endoscopy Unit, Hospital Quirón Sagrado Corazón, Sevilla, Spain

Correspondence to: Diego Sánchez-Muñoz, MD, Digestive Diseases Department, Hospital Quirón Sagrado Corazón, C/ Rafael Salgado, 3, 41003, Sevilla, Spain.

Email: dsanchezm@digestivosanchezmunoz.com

Telephone: +34-954937676

Received: September 29, 2013 Revised: October 28, 2013

Accepted: November 15, 2013

Published online: February 21, 2014

ABSTRACT

Endoscopic clipping technology has evolved widely during the last decades, having become an essential device in the Endoscopy Units. Nevertheless, the role of clips placement, the rate of success and the comparison among other endoscopic methods are not out of discussion. The present review focus on the different devices available, and shows the actual knowledge about hemoclips usefulness, indications and outcomes in several endoscopic situations.

© 2014 ACT. All rights reserved.

Key words: Clips, Endoscopy, Polypectomy, Gastrointestinal Bleeding

Sánchez-Muñoz D, Ortiz-Moyano C, Gómez-Rodríguez B. Role of Clips in Therapeutic Endoscopy: A Review. *Journal of Gastroenterology and Hepatology Research* 2014; 3(2): 963-967 Available from: URL: <http://www.ghrnet.org/index.php/joghr/article/view/605>

INTRODUCTION

Therapeutic endoscopy is continuously changing. As time marches, endoscopic methods are becoming more effective and precise, avoiding in many situations surgical derivation, reducing morbidity and mortality. This is valid both for emergency situations, such as bleeding or perforation, and in elective procedures, such as polypectomy, endoscopic submucosal dissection or even NOTES.

In all these situations, the development of endoscopic clips was a step forward in the therapy of gastrointestinal bleeding. Afterwards, the potential mechanical effect of clips derived in an wider range of indications, so endoscopic treatment of polyps, prevention of postpolypectomy bleeding, fistula closure, small perforations borders approximation, among others, benefit from the presence of clips in endoscopy rooms. The simplicity of use and the relative low rate of adverse events make clips a good alternative or an added device to be used in combination with other established methods. Nevertheless, this is a continuously changing world, and new clips are being designed and developed to be more effective.

This review will focus on the actual indications for endoscopic clipping, as well as setting clips place in the present and future of therapeutic endoscopy.

TYPES OF ENDOSCOPIC CLIPPING DEVICES

All the devices available have similarities in their design, consisting on a metallic cable within a different length and width Teflon sheath. In the distal end of the metallic cable the clip is enclosed with a mechanism that allows several opening and closing movements, similar to other forceps used in gastrointestinal endoscopy (i.e biopsy forceps), in order to position the clip properly in front of the lesion to be treated. The same way, a rotatable mechanism is incorporated at the handle of the device, which makes achievement of a correct opening direction of the clip possible. The detachment of the clip is also controlled by the handle. All but one of the devices deploy a single clip, making the use of several devices eventually necessary in order to solve the clinical situation for which clips are being used.

The first device was developed by Olympus (Olympus Corporation, Tokyo, Japan), being actually available a reusable model (Ez Clip™) and a single-use device (Quickclip™). The Ez Clip™ is a commonly used device in Asian countries. It is provided with several arm lengths from an ultrashort device (4 mm) to a standard one of 9 mm length. The Quickclip™ and the latter Quickclip2™ are manufactured in several lengths (short, standard, long), with a range of opening from 90°C to 135°C, and a jaw length from 7 to 9 mm for the Quickclip™, and a opening width from 9 to 11 mm for the Quickclip2™. Quickclip2™ is also available in a length enough to be



used in enteroscopy procedures.

The Resolution clip™ (Boston Scientific, Natick, Massachusetts, USA) offers the advantage that can be opened and closed several times before the detachment of the clips, allowing reposition of the device in order to deploy it at the best position possible. Other advantage is a width of jaw opening of 11 mm.

The Triclip™ (Cook Medical Inc, Bloomington, Indiana, USA) has the unique characteristic to have a triple arm clip, with an opened width of 12 mm. The improvement in the technique provided by this clip is that the three arms guarantee a theoretically better grasping of the lesion.

All of the previous devices have only one clip each device, so repetition of the procedure forces the endoscopist to insert a new device through the working channel of the endoscope each time. This event has been attempted to be solved by the introduction of a catheter including several clips, named Multiclip™ (InScope Inc, Cincinnati, Ohio, USA). This device offers 4 pre-loaded, 2 arms clips.

A different concept of clip, closer to the endoscopic suturing systems, is the over-the-scope clip (OTSC™) (Ovesco, Tübingen, Germany). This clip, attached to the tip of the endoscope, due to its greater compressive force, and its ability to grasp deeper tissue, offers the advantage to close wider defects than the other clips are able to. The mechanism of deployment is also different from the other one, being similar to that used in band ligation.

There is lack of data regarding comparison between different clips in different situations. The vast majority of studies have been related to the Olympus clips, but there is no clear recommendation about which clip is better in each clinical situation, making the decision according local availability, costs and/or endoscopist preferences and experience. The OTSC seems to be an exception, existing growing data about its usefulness in perforations and leakages, as well as in cases of failure in achieving hemostasis with other conventional methods. These data are discussed below.

INDICATIONS OF HEMOCLIPS

Non-variceal acute upper gastrointestinal bleeding

The first papers regarding the use of endoscopic hemoclips showed cases in which hemostasis had to be achieved. In 1988, Hachisu *et al* described a hemostatic rate of 84% in 51 patients with several bleeding lesions^[1]. Some studies have evaluated the efficacy of clips in the achievement of bleeding cessation of acute bleeding peptic ulcers in the gastrointestinal tract, comparing it with several thermal or injection hemostatic methods. Two studies compared clips placement versus heater probe thermocoagulation, with disparity of results^[2,3]. Several studies assessed comparison between clips and injection of several substances to achieve hemostasis in peptic bleeding ulcers, such as epinephrine^[4,5], ethanol^[6], polidocanol^[7], or distilled water^[8]. Initial hemostasis showed a higher efficacy of clips when compared with distilled water, but they did not demonstrate to be superior than polidocanol or ethanol. Nevertheless, the rate of initial success of clips in these studies was higher than 90%. When compared with epinephrine, clips, alone or in combination with epinephrine, did not show statistical significance in achieving initial hemostasis, but an hemostatic gain was shown to be attributed to clips^[5,9]. This agrees with the recommendations of international guidelines regarding the use of combination endoscopic methods to treat acute nonvariceal gastrointestinal bleeding^[10].

In 2007, Kirschniak *et al* published the first data about a new and promising clipping device, the Over-the-scope clip (OTSC™) in 11 patients suffering from gastrointestinal bleeding, achieving

hemostasis without complications and without rebleeding in all the cases^[11]. The same group increased the number of patients treated posteriorly, but in this case, two out of 27 patients rebled^[12]. Recently, OTSC™ demonstrated its efficacy as an option in treating patients who failed to conventional hemostatic therapies, including “classic” clips, achieving a 97% rate of success^[13]. It is soon to establish the real place of OTSC™ in the treatment of gastrointestinal bleeding lesions, but the results shown are promising.

Lower gastrointestinal bleeding

Clips have been used for the treatment of bleeding promoted by Dieulafoy lesions. Chung *et al* studied several methods for treating Dieulafoy lesions. Although it was a small series of patients, they concluded that mechanical methods were superior in efficacy than injection methods^[14]. Although it is not yet well established which is the best method for treating Dieulafoy lesions, clips have been compared with endoscopic band ligation, showing no differences in efficacy between both methods^[15,16].

Diverticular bleeding is another source of lower gastrointestinal bleeding which therapy can be challenging. Kaltenbach *et al* recently demonstrated how clips placement in acute diverticular bleeding can resolve the clinical problem in 75% patients, with a low rate of long term rebleeding^[17]. These results agreed with a previous study showing both a high immediate and long term result when acute diverticular bleeding was treated with clips placement (with or without epinephrine injection)^[18]. Nevertheless, when compared with other mechanical hemostatic methods, clips therapy were not superior than endoscopic band ligation at achieving initial hemostasis, but the rebleeding rate was higher in the clips group^[19]. Clips can be placed in the margin of the diverticulum, closing the diverticulum itself or over a visible vessel. Clips placement confers also the theoretical advantage of being a radiopaque marker for further therapy if needed. Small studies have also showed benefit for clips placement in other colonic bleeding diseases, such as rectal ulcer^[20]. The small incidence of these entities does not allow to have carried out comparative studies between several hemostatic methods.

Postpolypectomy bleeding

Bleeding events are one of the potential severe complications after endoscopic polypectomy, occurring both immediately after polypectomy or delayed, corresponding to 1.5-2% of all polypectomies^[21]. In case of acute bleeding after endoscopic polypectomy, therapy with clips have shown high rates of efficacy^[22], but studies comparing clipping with other thermal or mechanical methods in stopping postpolypectomy bleeding have not been found.

In order to approach to a simple, effective, and without appreciable side effects, method to prevent postpolypectomy bleeding, clips have been studied. A retrospective Spanish study showed that clips placement prevented from delayed bleeding in 34 patients with big, pedunculated polyps^[23] (Figure 1 and 2). Recently, clips have shown to be able to prevent up to 97% bleeding events when placed prophylactically prior to a standard snare polypectomy^[24]. When compared with other techniques, clips appeared to have similar efficacy rates in preventing delayed postpolypectomy bleeding than endoloop-assisted polypectomy, growing as an alternative when endoloop is difficult or impossible to place^[25]. A greek study compared hemorrhagic events after endoscopic polypectomy assisted with epinephrine alone or with combination method with clip and endoloop, observing how up to a 12.5% of the patients treated with adrenaline alone bled versus only a 3.2 % in the clip-endoloop group^[26].

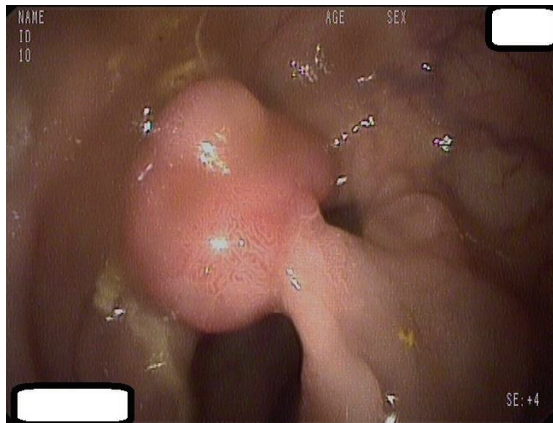


Figure 1 Pedunculated, big stalked polyp.

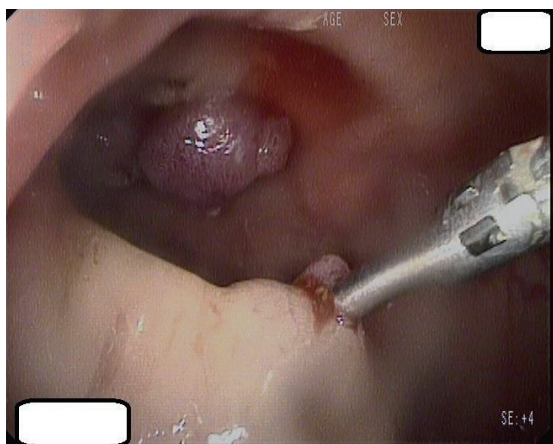


Figure 2 Clip placed after polypectomy to prevent postpolypectomy bleeding.

One argument against generalized use of prophylactic clips to prevent postpolypectomy bleeding may be, not only the lack of comparative data available, but other factors such cost, time-consumption, technical difficulties at clip placement or availability of clips worldwide. The same way, the relative low incidence of postpolypectomy bleeding has made endoscopists to question the real place of clips in the prevention of this complication. To clarify this fact, factors affecting postpolypectomy bleeding have been assessed, arguing that both polyp size and anticoagulant/antiplatelet therapy were risk factors for severe postpolypectomy bleeding^[27]. This way, patients with big polyps or patients under anticoagulation/antiplatelet therapy might achieve the highest benefit in preventing postpolypectomy bleeding when using clips^[28,29]. Our group carried out a study comparing clips placement versus adrenaline injection in big polyps, with result favoring the clip group. In our study, a subgroup of patients under anticoagulant/antiplatelet therapy was included, working out that it is necessary to treat 10 anticoagulated patients with clips to prevent a major bleeding episode, while the number needed to be treated in the non-anticoagulated group was 17, achieving statistical significance^[30].

Closure of perforations

In the last years of the 20th century, clips were first used to close colonic iatrogenic perforations by Japanese endoscopists^[31]. Several case reports led to clinical trials in animal models, showing efficacy of clips in closing colonic ruptures^[32,33]. Human studies did not delay, and in 2008, Magdeburg *et al* were able to manage conservatively with clips 25 out of 27 patients with iatrogenic colonic perforation, being able to avoid surgery and showing excellent outcomes^[34].

Similar results have been described recently in two retrospective Korean study^[35,36] (Figure 3).

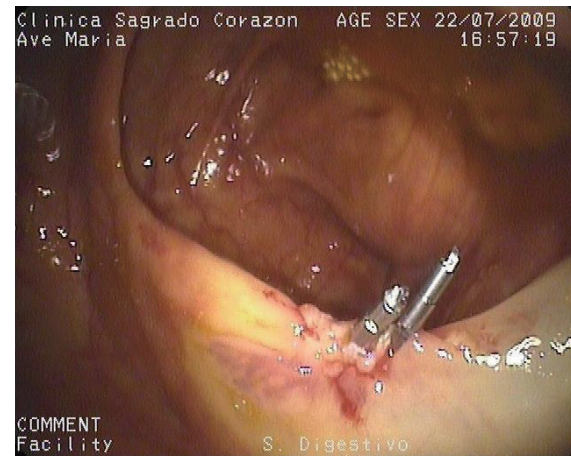

Figure 3 Satisfactory closure of a small iatrogenic perforation after an EMR performed to resect a sessile polyp at the cecum.

NOTES techniques need safe, reliable and versatile devices in order to close surgical accesses or iatrogenically induced perforations during the procedure. OTSCTM clips were able to fulfill these requisites. This way, OTSCTM showed efficacy and safety in closing surgically induced gastrotomies for NOTES procedures in animal models^[37,38]. In fact, OTSCTM showed to be superior to “conventional” clips in closing gastrotomies^[39].

These data on NOTES techniques led to carry out studies on OTSCTM usefulness in closing endoscopic perforations. Von Rentein *et al* carried out two experimental studies in pigs, comparing the efficacy and safety of OTSCTM in upper and lower gastrointestinal tract induced perforations, concluding that OTSCTM and surgery procedures outcomes are comparable^[40,41]. Clinical studies in humans did not take long to come, and OTSCTM showed efficacy and safety in endoscopically closing perforations in 10 patients^[42]. All these data took us to carry out studies in order to demonstrate if OTSCTM can avoid emergency surgery in selected cases, delivering a positive answer^[43]. The same way, postsurgical fistulas and leakages have been treated successfully with OTSCTM^[44,45]. Nevertheless, the future will lead us to establish the real role of OTSCTM in these situations.

CONCLUSIONS

Clips have become an essential device in endoscopy rooms, having demonstrated to be powerful, efficient, and versatile for the treatment of several clinical situations, such as bleeding, perforations, fistulas and for the prevention of postpolypectomy bleeding. Nevertheless, comparative studies, as well as cost-effectiveness data, are awaited in order to establish the best device to be used in each situation. Technological development of new clips, such as the OTSCTM, makes the future inspiring in order to offer the best available therapy to our patients.

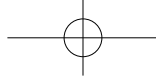
CONFLICT OF INTERESTS

There are no conflicts of interest with regard to the present study.

REFERENCES

- 1 Hachisu T. Evaluation of endoscopic hemostasis using an improved clipping apparatus. *Surg Endosc* 1988; 2: 13-17
- 2 Lin HJ, Hsieh YH, Tseng GY et al. A prospective, randomized trial of endoscopic hemoclip versus heater probe ther-

- mocoagulation for peptic ulcer bleeding. *Am J Gastroenterol* 2002; **97**: 2250-2254
- 3 Cippolletta L, Bianco MA, Marmo R *et al.* Endoclips versus heater probe in preventing early recurrent bleeding from peptic ulcer: a prospective and randomized trial. *Gastrointest Endosc.* 2001; **53**: 147-151
 - 4 Gevers AM, De Goede E, Simoens M *et al.* A randomized trial comparing injection therapy with hemoclip and with injection combined with hemoclip for bleeding ulcers. *Gastrointest Endosc* 2002; **55**: 466-469
 - 5 Chung IK, Ham JS, Kim HS *et al.* Comparison of the hemostatic efficacy of the endoscopic hemoclip method with hypertonic saline-epinephrine injection and a combination of the two for the management of bleeding peptic ulcers. *Gastrointest Endosc* 1999; **49**: 13-18
 - 6 Shimoda R, Iwakiri R, Sakata H *et al.* Evaluation of endoscopic hemostasis with metallic hemoclips for bleeding gastric ulcer: comparison with endoscopic injection of absolute ethanol in a prospective, randomized study. *Am J Gastroenterol* 2003; **98**: 2198-2202
 - 7 LJubicic N, Supanc V, Vrsalovic M. Efficacy of endoscopic clipping for actively bleeding peptic ulcer: comparison with polidocanol injection therapy. *Hepatogastroenterology* 2004; **51**: 408-412
 - 8 Chou YC, Hsu PI, Lai KH *et al.* A prospective, randomized trial of endoscopic hemoclip placement and distilled water injection for treatment of high-risk bleeding ulcers. *Gastrointest Endosc* 2003; **57**: 324-328
 - 9 Lo CC, Hsu PI, Lo GH *et al.* Comparison of hemostatic efficacy for epinephrine injection alone and injection combined with hemoclip therapy in treating high-risk bleeding ulcers. *Gastrointest Endosc* 2006; **63**: 767-773
 - 10 Barkun AN, Bardou M, Kuipers EJ *et al.* International consensus recommendations on the management of patients with nonvariceal upper gastrointestinal bleeding. *Ann Intern Med* 2010; **152**: 101-113
 - 11 Kirschniak A, Kratt T, Stüker D *et al.* A new endoscopic over-the-scope clip system for treatment of lesions and bleeding in the GI tract: first clinical experiences. *Gastrointest Endosc* 2007; **66**: 162-167
 - 12 Kirschniak A, Subotova N, Zieker D *et al.* The Over-The-Scope Clip (OTSC) for the treatment of gastrointestinal bleeding, perforations, and fistulas. *Surg Endosc* 2011; **25**: 2901-2905
 - 13 Manta R, Galloro G, Mangiavillano B *et al.* Over-the-scope clip (OTSC) represents an effective endoscopic treatment for acute GI bleeding after failure of conventional techniques. *Surg Endosc* 2013; **27**: 3162-3164
 - 14 Chung IK, Kim EJ, Lee MS *et al.* Bleeding Dieulafoy's lesions and the choice of endoscopic method: comparing the hemostatic efficacy of mechanical and injection methods. *Gastrointest Endosc* 2000; **52**: 721-724
 - 15 Park CH, Joo YE, Kim HS *et al.* A prospective, randomized trial of endoscopic band ligation versus endoscopic hemoclip placement for bleeding gastric Dieulafoy's lesions. *Endoscopy* 2004; **36**: 677-681
 - 16 Ahn DW, Lee SH, Park YS *et al.* Hemostatic efficacy and clinical outcome of endoscopic treatment of Dieulafoy's lesions: comparison of endoscopic hemoclip placement and endoscopic band ligation. *Gastrointest Endosc* 2012; **75**: 32-38
 - 17 Kaltenbach T, Watson R, Shah J *et al.* Colonoscopy with clipping is useful in the diagnosis and treatment of diverticular bleeding. *Clin Gastroenterol Hepatol* 2012; **10**: 131-137
 - 18 Yen EF, Ladabaum U, Muthusamy VR *et al.* Colonoscopic treatment of acute diverticular hemorrhage using endoclips. *Dig Dis Sci* 2008; **53**: 2480-2485.
 - 19 Setoyama T, Ishii N, Fujita Y. Endoscopic band ligation (EBL) is superior to endoscopic clipping for the treatment of colonic diverticular hemorrhage. *Surg Endosc* 2011; **25**: 3574-3578
 - 20 Oku T, Maeda M, Ihara H *et al.* Clinical and endoscopic features of acute hemorrhagic rectal ulcer. *J Gastroenterol* 2006; **41**: 962-970
 - 21 Sorbi D, Norton I, Conio M *et al.* Postpolypectomy lower GI bleeding: descriptive analysis. *Gastrointest Endosc* 2000; **51**: 690-696
 - 22 Parra-Blanco A, Kaminaga N, Kojima T *et al.* Hemoclippping for postpolypectomy and postbiopsy colonic bleeding. *Gastrointest Endosc* 2000; **51**: 37-41
 - 23 Sobrino-Faya M, Martínez S, Gómez Balado M *et al.* Clips for the prevention and treatment of postpolypectomy bleeding (hemoclips in polypectomy). *Rev Esp Enferm Dig* 2002; **94**: 457-462
 - 24 Boo SJ, Byeon JS, Park SY *et al.* Clipping for the prevention of immediate bleeding after polypectomy of pedunculated polyps: a pilot study. *Clin Endosc* 2012; **45**: 84-88
 - 25 Luigiano C, Ferrara F, Ghersi S *et al.* Endoclip-assisted resection of large pedunculated colorectal polyps: technical aspects and outcome. *Dig Dis Sci* 2010; **55**: 1726-1731
 - 26 Kouklakis G, Mpoumpouaris A, Gatopoulou A *et al.* Endoscopic resection of large pedunculated colonic polyps and risk of postpolypectomy bleeding with adrenaline injection versus endoloop and hemoclip: a prospective, randomized study. *Surg Endosc* 2009; **23**: 2732-2737
 - 27 Sawhney MS, Salfiti N, Nelson DB *et al.* Risk factors for severe delayed postpolypectomy bleeding. *Endoscopy* 2008; **40**: 115-119
 - 28 Katsinelos P, Fasoulas K, Chatzimavroudis G *et al.* Prophylactic clip application before endoscopic resection of large pedunculated colorectal polyps in patients receiving anticoagulation or antiplatelet medications. *Surg Laparosc Endosc Percutan Tech* 2012; **22**: e254-e258
 - 29 Parikh ND, Zanicco K, Keswani RN *et al.* A Cost-efficacy Decision Analysis of Prophylactic Clip Placement After Endoscopic Removal of Large Polyps. *Clin Gastroenterol Hepatol.* 2013. doi:pii: S1542-3565(13)00132-8. 10.1016/j.cgh.2012.12.044. [Epub ahead of print].
 - 30 Sánchez-Muñoz D, Ortiz Moyano C, Gómez Rodríguez B. Usefulness of hemoclips in the prevention of postpolypectomy bleeding in patients with high bleeding risk polyps. *Endoscopy* 2011;**43** (Suppl I): A336
 - 31 Yoshikane H, Hidano H, Sakakibara A *et al.* Endoscopic repair by clipping of iatrogenic colonic perforation. *Gastrointest Endosc* 1997; **46**: 464-466
 - 32 Raju GS, Pham B, Xiao SY *et al.* A pilot study of endoscopic closure of colonic perforations with endoclips in a swine model. *Gastrointest Endosc* 2005;**62**: 791-795
 - 33 Raju GS, Ahmed I, Brining D *et al.* Endoluminal closure of large perforations of colon with clips in a porcine model (with video). *Gastrointest Endosc* 2006; **64**: 640-646
 - 34 Magdeburg R, Collet P, Post S *et al.* Endoclippping of iatrogenic colonic perforation to avoid surgery. *Surg Endosc* 2008; **22**: 1500-1504
 - 35 Cho SB, Lee WS, Joo YE *et al.* Therapeutic options for iatrogenic colon perforation: feasibility of endoscopic clip closure and predictors of the need for early surgery. *Surg Endosc* 2012; **26**: 473-479
 - 36 Kim JS, Kim BW, Kim JI *et al.* Endoscopic clip closure versus surgery for the treatment of iatrogenic colon perforations developed during diagnostic colonoscopy: a review of 115,285 patients. *Surg Endosc* 2013; **27**: 501-504
 - 37 Kratt T, Küper M, Traub F *et al.* Feasibility study for secure closure of natural orifice transluminal endoscopic surgery gastrotomies by using over-the-scope clips. *Gastrointest En-*



- dosc* 2008; **68**: 993-996
- 38 Voermans RP, van Berge Henegouwen MI, Bemelman WA et al. Novel over-the-scope-clip system for gastrotomy closure in natural orifice transluminal endoscopic surgery (NOTES): an ex vivo comparison study. *Endoscopy* 2009; **41**: 1052-1055
- 39 von Renteln D, Vassiliou MC, Rothstein RI. Randomized controlled trial comparing endoscopic clips and over-the-scope clips for closure of natural orifice transluminal endoscopic surgery gastrotomies. *Endoscopy* 2009; **41**: 1056-1061
- 40 von Renteln D, Schmidt A, Vassiliou MC et al. Endoscopic closure of large colonic perforations using an over-the-scope clip: a randomized controlled porcine study. *Endoscopy* 2009; **41**: 481-486
- 41 von Renteln D, Rudolph HU, Schmidt A et al. Endoscopic closure of duodenal perforations by using an over-the-scope clip: a randomized, controlled porcine study. *Gastrointest Endosc* 2010; **71**: 131-138
- 42 Parodi A, Repici A, Pedroni A et al. Endoscopic management of GI perforations with a new over-the-scope clip device. *Gastrointest Endosc* 2010; **72**: 881-886
- 43 Hagel AF, Naegel A, Lindner AS et al. Over-the-scope clip application yields a high rate of closure in gastrointestinal perforations and may reduce emergency surgery. *J Gastrointest Surg* 2012; **16**: 2132-2138
- 44 Arezzo A, Verra M, Reddavid R et al. Efficacy of the over-the-scope clip (OTSC) for treatment of colorectal postsurgical leaks and fistulas. *Surg Endosc* 2012; **26**: 3330-3333
- 45 von Renteln D, Denzer UW, Schachschal G et al. Endoscopic closure of GI fistulae by using an over-the-scope clip. *Gastrointest Endosc* 2010; **72**: 1289-1296

Peer reviewers: Hiroto Kita, Professor and Chair, Department of Gastroenterology, Director of Endoscopy, Saitama Medical University International Medical Center, 1397-1, Yamane, Hidaka, Saitama, 350-1298, Japan; Hoon Jai Chun, MD, PhD, Professor, Division of Gastroenterology and Hepatology, Department of Internal Medicine, Institute of Digestive Disease and Nutrition, Korea University College of Medicine, 126-1, 5-Ga, Anam-Dong, Seongbuk-Gu, Seoul, 136-705, Korea; Kim JH, MD, PhD, Professor, Department of Gastroenterology, Ajou University School of Medicine, San 5, Woncheon-dong, Yeongtong-gu, Suwon 442-380, Korea.