

Rsf-1/HBXAP Predicts Poor Prognosis in HBV Related Hepatocellular Carcinoma Patients after Curative Resection

Yang Xu, Bin Guan, Qing-Feng Zhu, Hai-Xiang Sun, Mehtab Khan, Hai-Bo Bai, Xin-Rong Yang, Yun-Fan Sun, Bo Hu, Ie-Ming Shih, Jia Fan, Robert A Anders

Yang Xu, Hai-Xiang Sun, Xin-Rong Yang, Yun-Fan Sun, Bo Hu, Jia Fan, Liver Cancer Institute, Zhong Shan Hospital and Shanghai Medical School, Fudan University, Key Laboratory for Carcinogenesis & Cancer Invasion, The Chinese Ministry of Education, Shanghai, 200032, China

Yang Xu, Bin Guan, Qing-Feng Zhu, Hai-Xiang Sun, Mehtab Khan, Hai-Bo Bai, Ie-Ming Shih, Robert A Anders, The Sol Goldman Pancreatic Cancer Research Center, Departments of Pathology, Johns Hopkins University School of Medicine, Baltimore, Maryland, the United States

Bin Guan, Ie-Ming Shih, The Sol Goldman Pancreatic Cancer Research Center, Departments of Oncology, Johns Hopkins University School of Medicine, Baltimore, Maryland, the United States

Bin Guan, Ie-Ming Shih, The Sol Goldman Pancreatic Cancer Research Center, Departments of Gynecology, Johns Hopkins University School of Medicine, Baltimore, Maryland, the United States

Qing-Feng Zhu, Hai-Xiang Sun, Jia Fan, Institute of Biomedical Sciences, Fudan University, Shanghai, China

Correspondence to: Jia Fan, Liver Cancer Institute, Zhong Shan Hospital and Shanghai Medical School, Fudan University, Key Laboratory for Carcinogenesis & Cancer Invasion, The Chinese Ministry of Education, Shanghai, 200032, China.

Email: jiafan99@yahoo.com

Telephone: +1-508-856-3158

Fax: +1-508-856-5981

Received: September 17, 2013

Revised: October 11, 2013

Accepted: October 18, 2013

Published online: January 21, 2014

ABSTRACT

AIM: To illustrate the prognostic significance of RSF1 (also known as Hepatitis B X antigen-associated protein (HBXAP)) and its mechanism in hepatocellular carcinoma (HCC) patients.

METHODS: RSF1 expression was detected in tumor tissue microarrays of 254 HCC patients who underwent curative surgical resection during 2/2004 to 12/2005. Prognostic significance was assessed using Kaplan-Meier survival estimates and log-rank tests. The effects of RSF1 on cell proliferation and migration were tested in RSF1 knockdown and inducible systems in HCC cells.

RESULTS: RSF1 expression in HCC tissues was significantly related to tumor relapse in HCC patients after curative resection and

was significantly related to HBV infection and MMP9 expression. Knockdown (or over expression) of RSF1 in HCC cells significantly inhibited (or enhanced) HCC proliferation and invasion in vitro. RSF1 could also be shown to control the expression of MMP9 in HCC cells. **CONCLUSION:** RSF1 over expression is associated with poor prognosis in HBV HCC patients after curative resection and appears to regulate MMP9 expression.

© 2014 ACT. All rights reserved.

Key words: Hepatocellular carcinoma; RSF1/HBXAP; MMP9

Xu Y, Guan B, Zhu QF, Sun HX, Khan M, Bai HB, Yang XR, Sun YF, Hu B, Shih IM, Fan J, Anders RA. Rsf-1/HBXAP Predicts Poor Prognosis in HBV Related Hepatocellular Carcinoma Patients after Curative Resection. *Journal of Gastroenterology and Hepatology Research* 2014; 3(1): 945-954 Available from: URL:<http://www.ghrnet.org/index.php/joghr/article/view/587>

INTRODUCTION

Hepatocellular carcinoma (HCC) is the third leading cause of cancer worldwide^[1,2]. Unfortunately the prognosis, even in developed countries, is grim with a survival rate of 50% and 10% at one and five years, respectively^[3]. With incidences increasing in many regions of the world^[4], there is desperate need for effective treatments. Radiation and chemotherapy are not effective, and while novel therapies, such as the tyrosine kinase inhibitor, sorafenib, are being explored, surgical treatment predominates today^[5]. Surgical resection or liver transplantation is a patient's best hope for long term survival; however, this option is available only for a small number of patients and post-resection recurrence is common, with a five-year survival rate of 65%^[6]. Knowing which patients are at risk for early recurrence after curative resection would enable clinicians to stratify patients or prompt more intensive therapy. Therefore, preventing postoperative cancer relapse is the most significant target for improving curative surgical therapies.

To that end, we explored the prognostic significance of the chromatin remodeling protein, Rsf-1. Expression of Rsf-1 is associated with decreased overall survival in aggressive high grade serous ovarian cancers^[7-9]. Rsf-1 was also identified as a poor

prognostic factor when over expressed in ovarian^[10,11], non-small cell lung^[12], nasopharyngeal^[13,14], gallbladder^[15] and breast carcinoma^[16]. In addition, Rsf-1 (HBXAP) was identified as a binding partner of the oncogenic HBX protein^[17] and as a component of the ISWI-containing remodeling and spacing factor (RSF)^[18]. Rsf-1 is a plant homeodomain (PHD) finger protein that remodels chromatin^[18], regulates transcription and functions as a histone chaperone^[17,19]. Rsf-1's chromatin remodeling activity manifests by repositioning nucleosomes that lead to modulation of transcription^[20], promote DNA replication^[21] and cell cycle progression^[22].

Given Rsf-1's close association with the HBX oncogene and frequent amplifications of genes neighboring the Rsf-1 locus at 11q13 in HCC^[23-25], we explored its biological significance and clinical implication in HCC. We found that Rsf-1 expression in HCC is a poor prognostic factor with shorter time to recurrence (TTR) and an independent predictive factor of TTR. Furthermore, we examined how over expression and inhibition of Rsf-1 influences key parameters of HCC tumor progression in vitro. These results begin to establish the prognostic significance of Rsf-1 expression in liver cancer.

METHODS

Patients and Specimens

Tumor specimens used in tissue microarrays (TMAs) were obtained from 254 HCC patients who underwent surgical resection at the Liver Cancer Institute, Zhong Shan Hospital, Fudan University from February 15, 2004 to December 15, 2005. Tumor specimens were taken from viable areas of the tumors while necrotic tissues were avoided. The inclusion criteria of all patients in this study were as follows: (1) confirmed histopathological diagnosis of HCC based on the WHO criteria^[26]; (2) no prior therapy; (3) an "intent-to-cure" surgical resection—defined as the complete resection of all tumor nodules and the margins being free of cancer by histological examination^[27]; (4) suitable formalin-fixed, paraffin-embedded tissues; and (5) demographic and clinicopathological follow-up data. Tumor differentiation was defined according to the Edmondson grading system^[28] while staging was defined according to the sixth edition of TNM classification of UICC. Liver function was assessed by the Child-Pugh classification. The clinicopathological characteristics of all the patients are summarized in table 3. Ethical approval for human subjects was obtained from the research ethics committee of Zhong Shan Hospital and the Johns Hopkins University Institutional Review Board.

Follow-up and Tumor Recurrences

Patients were followed up every two months during the first postoperative year and at least every 3-4 months afterward. Follow-up was continued until March 30, 2011. All patients were prospectively monitored by serum AFP (alpha-fetoprotein), abdominal ultrasonography and chest X-ray every 1-6 months in the postoperative period. A computed-tomography (CT) scan of the abdomen was performed every six months. Bone scan or magnetic resonance imaging (MRI) was done if localized bone pain was reported. If recurrence was suspected, CT scan or MRI was performed immediately. Most patients died from recurrence, metastasis, or complicated liver cirrhosis. Patients with confirmed recurrence received further treatment, which followed the same protocol based on the size, site, number of tumor nodules and liver function. Briefly, if the recurrent tumor was localized, a second liver resection, radiofrequency ablation (RFA), or percutaneous ethanol injection (PEI) was performed; if the recurrent tumor was multiple or diffuse, then transcatheter arterial chemoembolization (TACE) was the choice.

External radiotherapy was given if lymph node or bone metastasis was found. Otherwise, symptomatic treatment was provided. Overall survival (OS) was defined as the interval between surgery and death or the last observation taken. The data were censored at the last follow-up for living patients. Time to recurrence (TTR) and time to death (TTD) were measured from the date of resection until the detection of recurrent tumor (or death) and data were censored for patients without signs of recurrence (or death). Tumor recurrence was grouped as "early" or "late" recurrence with 2 years as the cutoff period.

Tissue Microarray and Immunostaining

TMA was constructed as previously described^[29]. Briefly, all the HCC and peritumoral liver tissues were reviewed by two pathologists, and representative areas free from necrotic and hemorrhagic materials were pre-marked in the paraffin blocks. Two core biopsies of 1mm in diameter were taken from the donor blocks and transferred to the recipient paraffin block at defined array positions. Two HCC and 2 respective peritumoral liver TMA blocks were constructed. Consecutive sections of 4- μ m thickness were taken on 3-aminopropyltriethoxysilane (APES)-coated slides (Shanghai Biochip Co., Ltd., Shanghai, P.R.China). The mouse monoclonal antibody for RSF1 was purchased from Upstate, NY (No.05-727, diluted 1:100), and Rabbit polyclonal antibodies to LT β R and E-cadherin were purchased from Abcam, CA (No. ab70063 and ab53033, all diluted 1:100). Immunohistochemistry was carried out using a two-step protocol (Novolink Polymer Detection System, Novocastra, Newcastle, UK) as previously described^[29,30]. Briefly, after microwave antigen retrieval, tissues were incubated with primary antibodies for 60 min at room temperature or overnight at 4°C. Following 30 min incubation with secondary antibody (No. A0545, sigma; No. A11001, Invitrogen), the sections were developed in DAB solution under microscopic observation and counterstained with hematoxylin. Negative control slides with the primary antibodies omitted were included in all assays.

Evaluation of Immunohistochemical Variables

A positive reaction of RSF1 was defined as discrete localization of the brown chromogen in the nuclei. The staining extent score was based on a scale of 0-4, corresponding to the percentage of immunoreactive tumor cells (0%, 1-5%, 6-25%, 26-75%, and 76-100%, respectively). Staining intensity was scored as negative (0), weak (1), or strong (2). A score ranging from 0 to 8 was calculated by multiplying the staining extent score by the intensity score, resulting in a negative (0-4) or positive (5-8) expression value for each specimen. Cases with two different scorings were scored by a third investigator and the final score was determined by the majority scores. The duplicate of spots for each tumor showed relative homogeneity for stained cell percent and intensity. The higher score was considered as a final score in case of a difference between duplicate tissue cores.

Cell culture

97H and 97L human HCC cell lines which were used in these studies were provided by Dr. Xin-Wei Wang from U.S. National Cancer Institute with the permission of Prof. Zhao-You Tang of Liver Cancer Institute, Fudan University, China. All cell lines were routinely maintained at 37°C and 5% CO₂ in DMEM supplemented with 10% fetal bovine serum (FBS) and 1% penicillin/streptomycin.

QRT-PCR and western blot

Total RNA was prepared using Trizol (Invitrogen) from which cDNA was synthesized using the Superscript First-Strand Synthesis system (Invitrogen). Quantitative real time (qRT-PCR) amplification was performed using the QuantiTect SYBR Green PCR kit (QIAGEN)

on a StepOnePlus PCR System (Applied Biosystems). qRT-PCR was done in triplicate, using beta-actin (assay ID Mm01205647, reference sequence ID NM_001101.2) as a housekeeping control. Relative mRNA levels were calculated based on the 2^{-ΔΔCT} method. The primers are as listed (RSF-Forward 5'-cagttcgaaagcgggg ccga-3', reverse 5'-gccgttgccgggatggttgc-3'; MMP9 Forward 5'-acgcagacatcgtcatccagttt-3',reverse 5'-ccacaactcgtcatcgcgaat-3').-

For western blot analysis, total protein was isolated from the cells. Immunoblotting experiments were performed according to standard procedures^[31] with mouse monoclonal anti-human RSF1 (No.05-727, Upstate, NY, diluted 1:500), and rabbit polyclonal antibodies to MMP9 (No.10737, Santa Cruz Biotechnology diluted 1:200), rabbit polyclonal anti-human GAPDH (No.G9545, Sigma, MO, diluted 1:1000).

Rsf1 Overexpression and Gene Knockdown Using Small Hairpin RNA

The coding sequence of Rsf1 gene was cloned into the pLenti4/TO/V5 vector, which was constructed by removing the DEST fragment between the two EcoRV sites in the pLenti4/TO/V5-DEST vector (Invitrogen). 97L cells were infected with lentiviral particles produced with pLenti4/TO/V5 (denoted as 97L-VEC in figures) or pLenti4/TO/V5-Rsf1 (denoted as 97L-R)in 293FT cells (Invitrogen) using the 2nd generation packaging system pSPAX2 and pMD2.G (Addgene plasmids 12260 and 12259). The introduced Rsf-1 protein is tagged at the carboxy terminus with a V5 tag.

97H cell line was used in Rsf1 knockdown assays. Rsf1 knockdown was done by transduction of 2 small hairpin RNAs (shRNA) with the knockdown efficiency evaluated by Western blot analysis. The antibody specificity was indicated by reduced protein expression corresponding to Rsf1 after the gene knockdown based on Western blot analysis using the same anti-Rsf1 antibody used in immunohistochemistry. We used a lentivirus carrying the Rsf1 shRNA sequence templates: CCGGCCAGTTCTGAACCTTGAAG ATCTCGAGATCTTCAAAGTTCAGAACT; CCGGCTTCTGAG ACAAAGGGTCTACTCGAGTAGAACCCCTTGTCTCAGA and a control shRNA sequence template, which were inserted into the lentiviral plasmid (pLKO.1-puro). Cells were washed and harvested 24 hours after transfection. Three clones of cells (Knockdown cell line 97-R-sh1, and 97H-R-sh2, control cell line 97H-SCR) were selected and the efficiency of Rsf1 knockdown was confirmed by Western blot and qRT-PCR.

In vitro Growth, Wound Healing Assay and Matrigel Invasion Assay

Cell proliferation was assessed using the MTT assay. Cells were seeded at a density of 2000 cells per well and allowed to grow overnight. Cell viability was measured after 24, 48, 72, 96 and 120 hours.

The method used for the wound healing assay has been previously described (15). Briefly, the cells were plated onto 6-well plates and incubated in DMEM containing 10% FBS until they reached subconfluence. Scratches were introduced to the subconfluent cell monolayer using a plastic pipette tip. The cells were then cultured with DMEM containing 10% FBS at 37°C. After 24 hours, the scratch area was photographed using a light microscope. The wound distance between edge to edge was measured and averaged from 5 points per 1 wound area. Two wound areas were evaluated in each experiment which were done in triplicate.

For the cell invasion assay cells were seeded onto a matrigel-coated filter (No.3458, Corning) and incubated for 8 hours at 37°C. The cells that actively migrated to the lower surface of the filters were stained and quantified. All assays were performed in triplicate.

Statistical Analysis

Statistical analyses were performed with SPSS 15.0 for Windows (SPSS, Chicago, IL). Cumulative survival time was calculated with the Kaplan-Meier method and analyzed by the log-rank test. Univariate and multivariate analyses were based on the Cox proportional hazards regression model. The chi-square test, Fisher’s exact probability and Student’s *t*-test were used for comparison between groups. *P*<0.05 was considered statistically significant.

RESULTS

Expressions of RSF1 and Relevance to Prognostic Factors

For the whole study population (*n*=254), the 5-year overall survival (OS) and relapse free survival (RFS) rates were 49.6% and 48.3%, respectively. On univariate analysis, significant poor predictors of OS included: serum GGT and AFP; tumor differentiation, encapsulation, size and number; vascular invasion; TNM and BCLC stage. Significant factors associated with TTR were serum AFP, tumor number; vascular invasion; BCLC stage and RSF1 expressions (Table 1). On multivariate analysis, serum GGT; tumor size and number and vascular invasion were independent factors associated with OS. Tumor size, vascular invasion and RSF1 expression were independent pre-

Table 1 Univariate analyses of factors associated with survival and recurrence (*n*=254).

Variables	OS		TTR	
	Hazard ratio (95% CI)	P Value	Hazard ratio (95% CI)	P Value
Sex (male vs. female)	1.16 (0.75-1.80)	0.513	1.04 (0.66-1.64)	0.863
Age, years (>52 vs ≤52)	0.99 (0.98-1.01)	0.452	1.00 (0.99-1.02)	0.872
HBsAg (positive vs negative)	0.79 (0.52-1.21)	0.280	1.05 (0.65-1.69)	0.858
HBeAg (positive vs negative)	1.08 (0.67-1.74)	0.753	1.05 (0.64-1.74)	0.843
HCV (positive vs negative)	1.33 (0.33-5.37)	0.692	0.57 (0.08-4.11)	0.581
Liver cirrhosis (yes vs no)	1.34 (0.89-2.02)	0.167	1.09 (0.68-1.73)	0.726
GGT (U/L) (>54 vs ≤54)	1.84 (1.27-2.66)	0.001	1.05 (0.75-1.57)	0.653
ALT (U/L) (>75 vs ≤75)	0.76 (0.43-1.34)	0.342	0.97 (0.55-1.73)	0.918
AFP(ng/mL) (>20 vs ≤20)	1.78 (1.21-2.63)	0.004	1.57 (1.05-2.36)	0.027
Tumor differentiation (III-IV vs I-II)	1.67 (1.14-2.44)	0.009	1.19 (0.77-1.85)	0.437
Tumor encapsulation (none vs complete)	1.49 (1.06-2.09)	0.021	1.25 (0.87-1.79)	0.233
Tumor size (cm) (>5 vs ≤5)	2.04 (1.45-2.87)	<0.001	1.34 (0.93-1.92)	0.119
Tumor number (multiple vs single)	2.00 (1.31-3.04)	0.001	1.87 (1.19-2.93)	0.006
Vascular invasion (yes vs no)	3.37 (2.38-4.76)	<0.001	2.07 (1.43-3.01)	<0.001
TNM stage (II+III vs I)	1.49 (1.05-2.10)	0.025	1.38 (0.95-2.00)	0.093
BCLC stage (II+III vs I)	2.41 (1.50-3.39)	<0.001	1.63 (1.05-2.54)	0.031
RSF1 (Low vs High)	1.38 (0.97-1.91)	0.078	1.58 (1.10-2.28)	0.016

Abbreviations: 95%CI, 95% confidence interval; TTR: time to recurrence; OS: overall survival; AFP: alpha-fetoprotein; RSF1: remodeling and spacing factor 1; GGT: gamma-glutamyl transpeptidase; ALT: alanine aminotransferase; TNM: tumor-node-metastasis; BCLC: the Barcelona Clinic Liver Cancer staging; Univariate analysis, Cox proportional hazards regression model.

dictive factors of TTR (Table 2). We examined RSF1 expression using immunohistochemical staining of a tissue microarray constructed from 254 patients who had undergone HCC resection with curative intent. The clinical and pathologic characteristics of this patient cohort revealed that 131 (51.6%) patients were over 52 years of age, 206 (81.1%) were men and 215 (84.6%) were infected with chronic hepatitis B. High expression of RSF1 was detected in 122 (48%)

Table 2 Multivariate analyses of factors associated with OS and TTR (n=254).

Variables	OS	
	Hazard ratio (95% CI)	P Value
GGT (U/l) (>54 vs ≤54)	1.90(1.29-2.80)	0.001
AFP(ng/ml) (>20 vs ≤20)	1.39(0.92-2.08)	0.116
Tumor differentiation (III-IV vs I-II)	1.13(0.76-1.67)	0.558
Tumor encapsulation (none vs complete)	1.03(0.72-1.47)	0.884
Tumor size (cm) (>5 vs ≤5)	1.59(1.12-2.27)	0.010
Tumor number (multiple vs. single)	1.79(1.17-2.75)	0.008
Vascular invasion (yes vs. no)	2.95(2.02-4.31)	<0.001
Variables	TTR	
AFP(ng/ml) (>20 vs ≤20)	1.27(0.98-2.06)	0.272
Tumor number (multiple vs. single)	1.53(0.96-2.42)	0.074
Vascular invasion (yes vs no)	1.87(1.27-2.75)	0.001
RSF1 (Low vs High)	1.42(0.98-2.06)	0.066

95%CI: 95% confidence interval; TTR: time to recurrence; OS: overall survival; AFP: alpha-fetoprotein; GGT: gamma-glutamyl transpeptidase; ALT: alanine aminotransferase; RSF1: remodeling and spacing factor 1; TNM: tumor-node-metastasis; BCLC: the Barcelona Clinic Liver Cancer staging; Multivariate analysis, Cox proportional hazards regression model. The clinicopathological variables were adopted for their prognostic significance by univariate analyses.

Table 3 The clinical/pathological characteristics of 254 cases of HCC.

Clinical and pathological indexes	Number	Percentage (%)
Age (y)	≤52	48.4
	>52	51.6
Sex	Female	18.9
	Male	81.1
Liver cirrhosis	No	18.5
	Yes	91.5
Child-Pugh	A	99.6
	B	0.4
HBsAg	Negative	17.3
	Positive	82.7
HBeAg	Negative	15.4
	Positive	84.6
HCV	Negative	98.8
	Positive	1.2
GGT (U/l)	≤54	35.8
	>54	64.2
ALT (U/l)	≤75	89.0
	>75	11.0
AFP	≤20 ng/mL	33.9
	>20 ng/mL	66.1
Tumor encapsulation ¹	Complete	55.9
	None	44.1
Tumor differentiation	I-II	78.3
	III-IV	21.7
Tumor size	≤5 cm	56.7
	>5 cm	43.3
Tumor number	Single	85.0
	Multiple	15.0
Vascular invasion	No	72.4
	Yes	27.6
TNM Stage	I	65.0
	II-III	35.0
BCLC	I	25.2
	II-III	74.8
RSF1	Low	52.0
	High	48.0

AFP: alpha-fetoprotein; ALT: alanine aminotransferase; GGT: gammaglutamyl transferase; TNM: tumor-node-metastasis; BCLC: the Barcelona Clinic Liver Cancer staging; RSF1: remodeling and spacing factor 1.

HCC tumor samples (Table 3). The expression of RSF1 was significantly elevated in tumor tissue samples compared with the non-tumor counterparts ($P<0.01$). Staining was relatively homogenous within a neoplasm, excluding necrotic, hemorrhagic and fibrotic regions. Compared to control staining (Figure 1A and 1B), RSF1 was detected predominantly in the nuclei of tumor cells. RSF1 expression in tumor tissue correlated with serum HBsAg and HBeAg expressions (Table 4). Patients with RSF1 high-expressing tumors had significantly reduced mean TTR ($P<0.001$, Figures 1C) and 5y-RFS (21.4% vs. 30.6%, $P=0.016$, Figures 1D) compared to those with low RSF1 expression. The significant prognostic role of RSF1 was also apparent in early recurrence (recurrence time less than 24m, $P=0.008$, Figure S1A and S1B), negative serum AFP ($P=0.027$, Figure S1C and S1D) and late stage HCC patients (TNM II-III, $P=0.001$, Figure S1E and S1F).

Table 4 Correlation between RSF1 expression in tumor and other factors (n=254).

Factors	RSF1-Low	RSF1-High	P Value
Age (y)	≤52	64	0.258
	>52	58	
Sex	Female	21	0.526
	Male	101	
Liver cirrhosis	No	28	0.105
	Yes	94	
HBsAg	Negative	15	0.047
	Positive	107	
HBeAg	Negative	8	<0.001
	Positive	114	
HCV	Negative	121	1.000
	Positive	1	
GGT (U/l)	≤54	50	0.438
	>54	72	
ALT (U/l)	≤75	107	0.554
	>75	15	
AFP (ng/ml)	≤20	35	0.112
	>20	87	
Tumor encapsulation	Complete	64	0.313
	None	58	
Tumor differentiation	I-II	97	0.761
	III-IV	25	
Tumor size (cm)	≤5	74	0.254
	>5	48	
Tumor number	Single	100	0.219
	Multiple	22	
Vascular invasion	No	74	0.238
	Yes	48	
BCLC stage	0+A	31	1.000
	B+C+D	91	
TNM stage	I	83	0.512
	II-III	40	

AFP: alpha-fetoprotein; GGT: gamma-glutamyl transpeptidase; ALT: alanine aminotransferase; TNM: tumor-node-metastasis; RSF1: remodeling and spacing factor 1; BCLC: the Barcelona Clinic Liver Cancer staging; Pearson Correlation analysis.

RSF1 Gene Relates to HCC Proliferation and Invasion

RSF1 expression was detected by western blot and qRT-PCR. The highly metastatic HCC cell line, 97H, showed significantly higher protein and RNA expression levels of RSF1 than the low metastatic HCC cell line, 97L (Figure 2A & 2B). Two stable clones, 97H-R-sh1 and 97H-R-sh1, were generated using small hairpin RNA directed against the RSF1 gene in the 97H cell line. We found lower RSF1 protein and mRNA expression level in these clones compared to control cells, 97H-SCR (Figure 2C and 2D).

Stable transfectants, 97L-R, was established using RSF1/V5 lentivirus, and showed significantly higher RSF1 protein and RNA expression level than the control, 97L-VEC (Figure 2E and 2F, $*p<0.05$, $**p<0.01$).

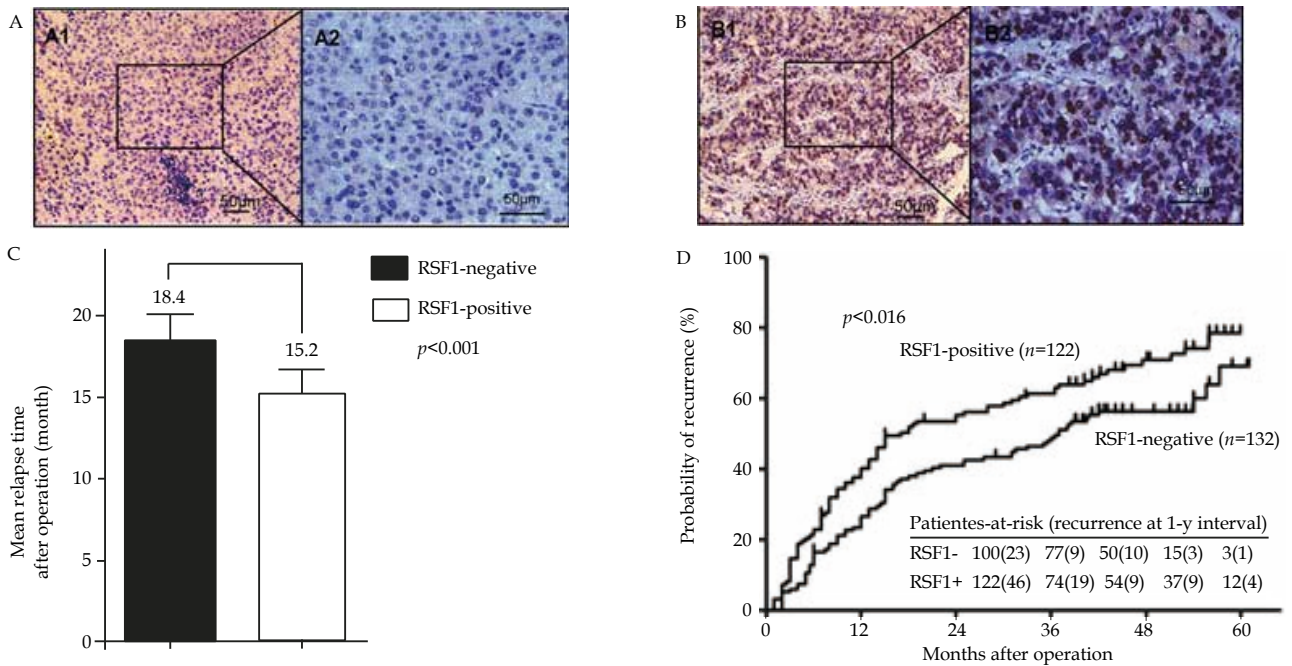
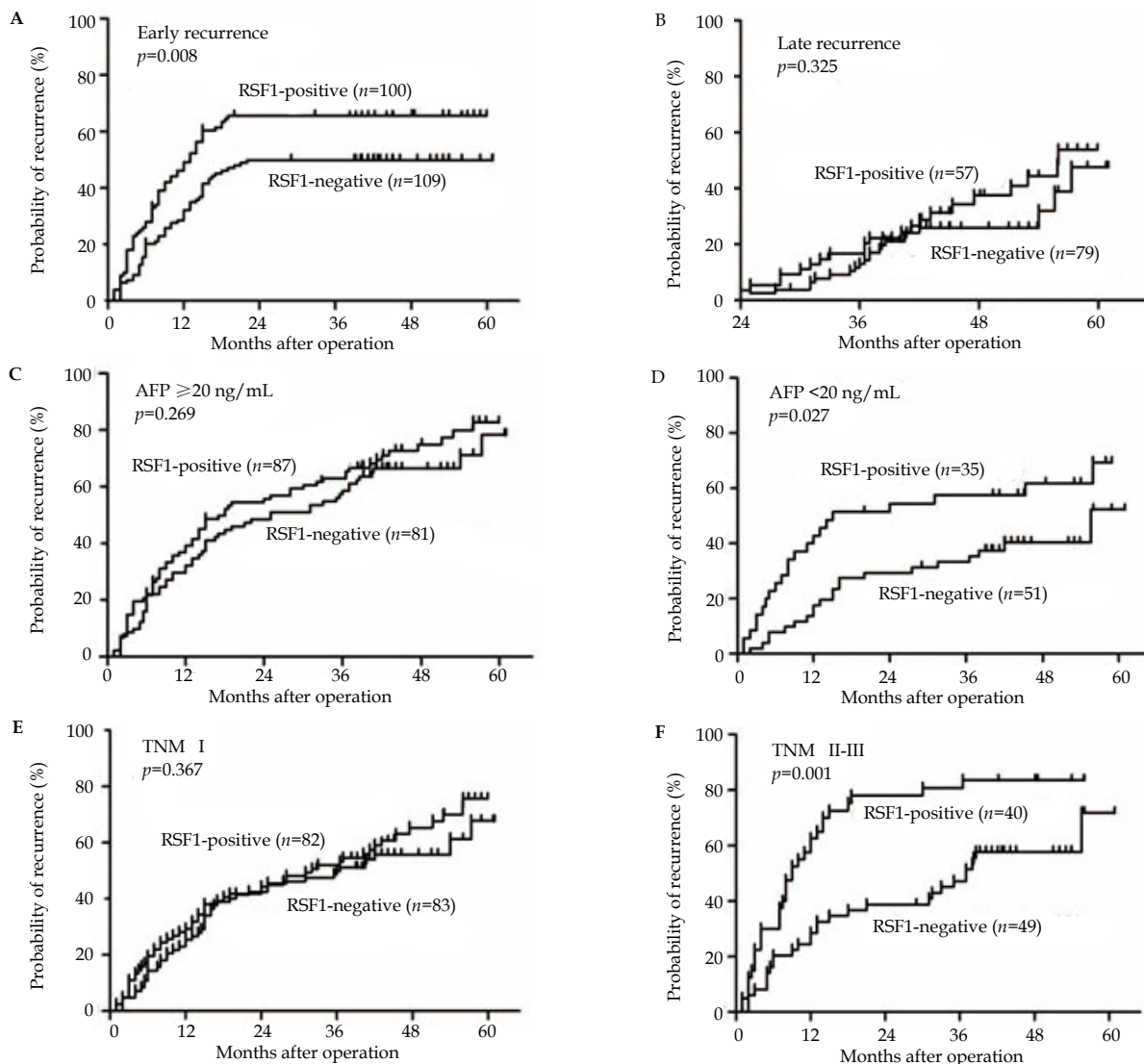


Figure 1 Rsf-1 expression in HCC patients. Representative negative (A1 & A2) and positive (B1 & B2) immunohistochemical staining with anti-Rsf-1 antibody from TMAs containing 254 patients with HCC. (C) Mean relapse time for each patient was calculated and compared between HCC's that do and do not express Rsf-1. (D) Kaplan-Meier analysis showed that high expressing Rsf-1 HCCs correlate with a significantly higher rate of tumor recurrence.



Supplemental Figure 1 Rsf-1 expression in HCC patients. Kaplan-Meier analysis showed that high expressing Rsf-1 HCCs correlate with a significantly higher rate of tumor recurrence especially in patients with early recurrence(A, B). These trends are also marked in patients with (C, D) negative serum AFP (<20ng/mL) and (E, F) advanced stage (TNM II-III) cancers.

Next, we determined if RSF1 gene expression could effect in vitro growth of HCC cell lines. Cell viability (MTT) assays showed that over-expression of RSF1 in 97L had a higher proliferation rate at 120h, but showed no significant difference compared to control cells (97L-R vs 97L-VEC, $P=0.262$, figure 3A). However, RSF1 knockdown significantly decreased the proliferation of 97H cells (97H-R-sh1 or 97H-R-sh2 vs 97H-SCR, $P<0.001$, figure 3B). A wound healing assay indicated that over-expression of RSF1 increased the migration of 97L cells, but showed no significant difference com-

pared to control cells ($P=0.251$, figure 3C and 3D). RSF1 knockdown (97H-R-sh1 97H-R-sh2) significantly inhibited 97H cell migration cells compared to control cells (97H-SCR) ($P<0.001$ for all, Figure 3E and 3F). Cell invasion assay showed RSF1 over-expression (97L-R) significantly enhanced the invasion in compared to control (97L-VEC) cells ($P<0.001$, Figure 3G and 3I), and RSF1 knockdown (97H-R-sh1 and 97H-R-sh2) significantly inhibited the migration in cells compared to control (97H-SCR) cells ($P=0.027$, 0.013, Figure 3H and 3J).

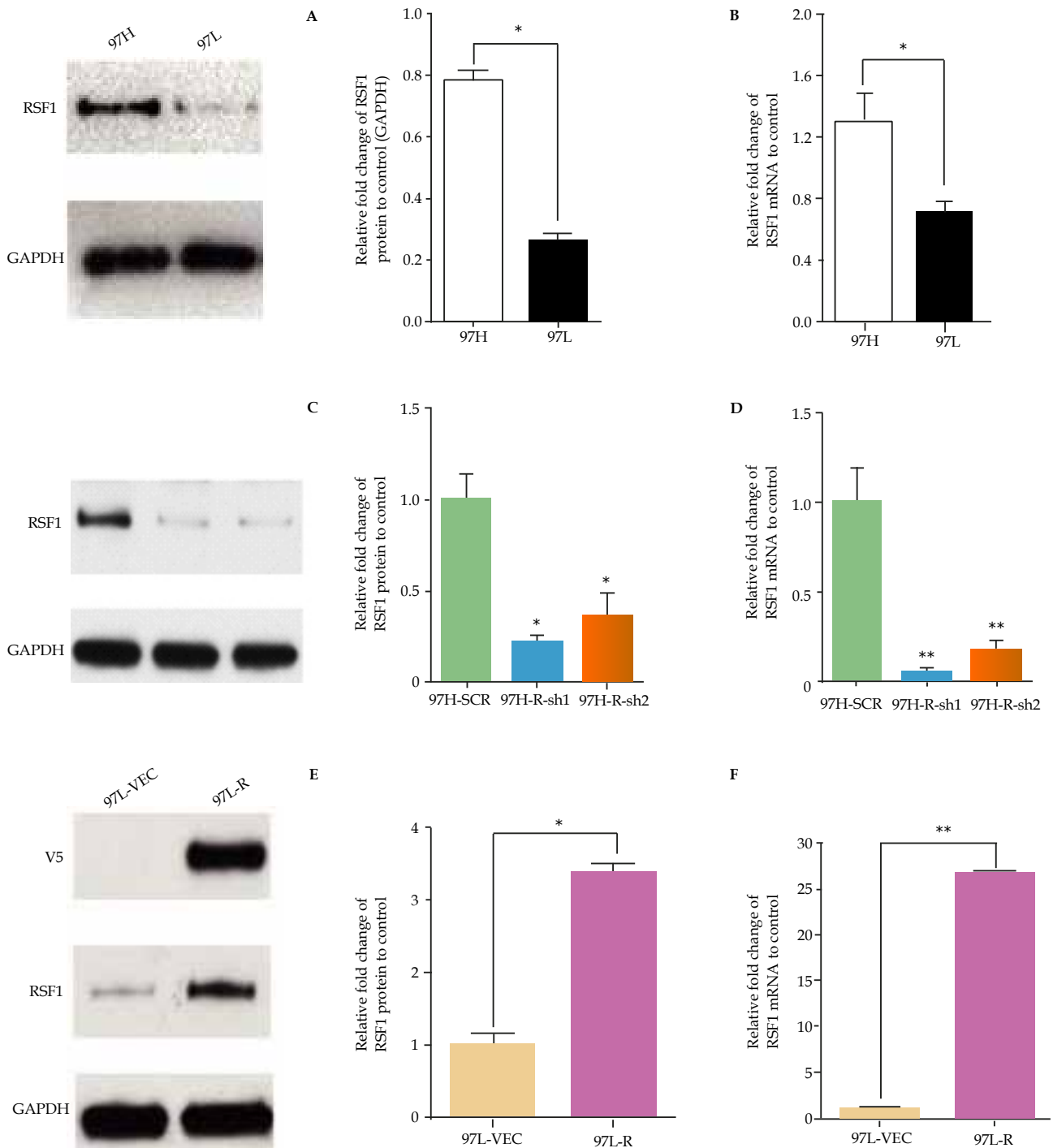


Figure 2 RSF1 gene knockdown and over-expression in HCC cell lines. RSF1 expression was detected with western blot (A, C, E) and qRT-PCR (B, D, F) in human HCC cell lines with high (97H) and low (97L) metastatic potential (A, B). RSF1 gene was knocked down using small hairpin RNA (R-sh1, R-sh2) in 97H (C, D) and compared to scrambled control RNA (SCR). An RSF1 over-expressing 97L cell (E, F) was established using RSF1/V5 lentivirus containing the RSF1 gene (R) or control vector (VEC) ($*p<0.05$, $**p<0.01$).

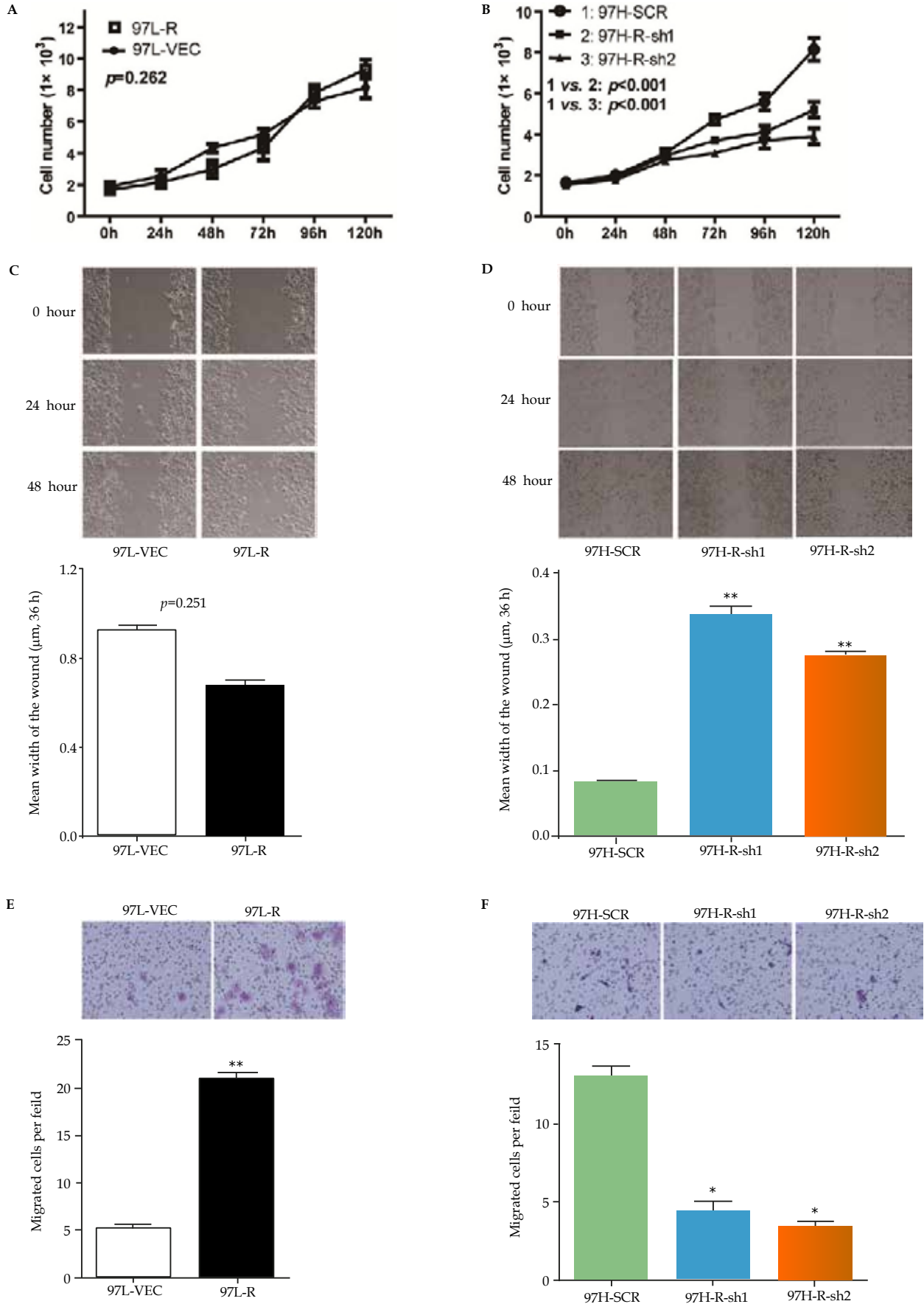


Figure 3 RSF1 gene relates to HCC proliferation and invasion. Cell viability (MTT) assay and wound healing assay showed no marked change between RSF1 over-expression cell line (97L-R) and the control cell line(97L-VEC) (A,C), but RSF1 knockdown cell lines(97H-R-sh1 and 97H-R-sh2) significantly inhibited both the proliferation and the wound healing speed compared to the control cell line(97H-SCR) (B,D). Cell invasion assay showed that RSF1 over-expression (or knockdown) significantly enhanced (or inhibited) the invasion of HCC cells ($*p<0.05$, $**p<0.01$) (E, F).

RSF1 Gene Regulates Genes Linked to HCC Recurrence

To identify the possible mechanism underlying how Rsf-1 upregulation attributed to early recurrence, we sought to modulate Rsf1 expression to identify genes shown to be important in HCC invasion and metastasis. MMP9 is associated with post operative recurrence^[32] and metastasis^[33]. Rsf1 over-expression significantly enhanced the RNA and protein expression of MMP9, detected by qRT-PCR ($P<0.001$, Figure 4A) and western blot (Figure 4C). Rsf1 knock-down significantly decreased the expression of MMP9 detected by qRT-PCR ($P<0.001$, Figure 4B).

DISCUSSION

HCC carries a significant global disease burden with few effective treatments. Surgical resection or liver transplantation is a patient's best hope for long term survival; however, this option is available only for a small number of patients and post-resection recurrence is common, Risk markers for tumor recurrence could direct adjuvant therapy or provide a new therapeutic target.

The prognostic significance of Rsf1 has been explored in many tumor types^[13-16]. Although originally found to be associated with the oncogenic hepatitis B viral X protein, Rsf-1 has not been correlated with clinical outcome in HCC patients. We found Rsf-1's expression in HCC tumors correlated with shorter time to recurrence, was an independent predictive factor in TTR, and played a particularly strong prognostic role in early recurrence. Moreover, expression of Rsf-1 has been shown to be a potent oncogene capable of modulating cell signaling, cell proliferation and anchorage independent growth.

One limitation of our study is the high percentage of HBV infected patients (82%). It is unclear if our findings would extend to HCC developing in a setting other than chronic HBV infection, and it is

important to note that chronic HBV infection is responsible for most of the world wide HCC disease burden^[34].

Targeting Rsf-1 could increase the effectiveness of chemotherapy in HCC since suppressed expression causes ovarian cancer sensitivity to paclitaxel therapy. At the same time Rsf-1 has been shown to interfere with NF-kB function which could render resistant to TNF alpha mediated apoptosis^[35].

Rsf-1 and other putative HCC oncogenes linked to HCC reside in the 11q13 region. DNA banding analysis shows that the 11q13 locus is amplified in a metastatic HCC cell line^[24]. Amplification of the cyclin D1 (CCND1) oncogene at 11q13.2-3 can be found in approximately 15% of human HCCs^[36] and is associated with large tumor size^[37,38]. The FGF19 gene located at 11q13.3 may be another driver of hepatocellular carcinogenesis and a potential biomarker for directing anti- FGF19 therapy^[39]. Here we show that enhanced Rsf-1 expression of another 11q13 oncogene is significantly increased in HCC. Over expression of Rsf-1 significantly increases cell invasion while inhibiting Rsf-1 reduces cell proliferation and potentially inhibits cell migration and invasion. First we sought to uncover if Rsf-1 modulates the expression of E-cadherin, which has been linked to HCC tumorigenesis and even has prognostic importance. Not only did we find E-cadherin is suppressed by Rsf-11, but we also found N-cadherin was up-regulated. These findings suggest Rsf-1 might be a regulator or EMT.

Lastly, we found that the matrix associated factor, MMP-9 was also significantly upregulated by Rsf-1. MMP-9 over-expression in HCC tumors compared to the same patient's non-tumor tissue is significantly associated with post-operative recurrence^[32] and may contribute to the prognostic significance of tumor microenvironment hypoxia^[40], matrix remodeling^[41] and metastasis^[42]. Furthermore, MMP-9 was specifically associated with HBV associated HCC tumorigenesis rather than HCC occurring in chronic HCV infection^[43].

Our results suggest Rsf-1 might be a proximal regulator or factor known to be prognostically and mechanistically linked to tumor metastasis. This gene might not only be a useful biomarker for predicting recurrent HCC, but also a promising potential therapeutic target.

ACKNOWLEDGMENTS

This study was supported by grants from Natural Science Foundation of China No. 81071661(Y.X), National Key Sci-Tech Project of the Ministry of Science and Technology of China 2012ZX10002011-004 and 2012ZX0930100-007(Y.X), National Institute of Health R01DK080736 (R.A.A.), R01DK081417 (R.A.A.), RO1CA129080 (IMS); Michael Rolfe Foundation for Pancreatic Cancer Research (R.A.A.).

REFERENCES

- 1 Llovet JM, Burroughs A, Bruix J. Hepatocellular carcinoma. *Lancet* 2003; **362**(9399): 1907-1917
- 2 McGlynn KA, London WT. The global epidemiology of hepatocellular carcinoma: present and future. *Clin Liver Dis* 2011; **15**(2): 223-243
- 3 Altekruse SF, McGlynn KA, Reichman ME. Hepatocellular carcinoma incidence, mortality, and survival trends in the United States from 1975 to 2005. *J Clin Oncol* 2009; **27**(9): 1485-1491
- 4 Shaw JJ, Shah SA. Rising incidence and demographics of hepatocellular carcinoma in the USA: what does it mean? *Expert Rev Gastroenterol Hepatol* 2011; **5**(3): 365-370

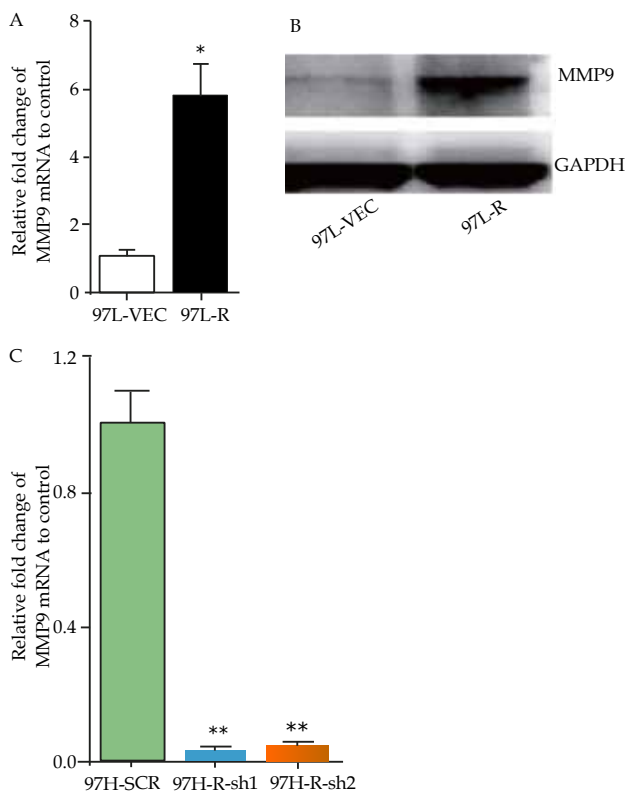


Figure 4 Rsf1 expression correlates with expression of MMP9 an HCC metastasis associated gene. MMP9 mRNA (A) and (B) protein expression level significantly increased after Rsf-1 over-expression (* $p<0.05$). MMP9 mRNA level significantly decreased after Rsf-1 knockdown (C) (** $p<0.01$).

- 5 Llovet JM, Ricci S, Mazzaferro V, Hilgard P, Gane E, Blanc JF, de Oliveira AC, Santoro A, Raoul JL, Forner A, Schwartz M, Porta C, Zeuzem S, Bolondi L, Greten TF, Galle PR, Seitz JF, Borbath I, Haussinger D, Giannaris T, Shan M, Moscovici M, Voliotis D, Bruix J, Sorafenib in advanced hepatocellular carcinoma. *N Engl J Med* 2008; **359**(4): 378-390
- 6 Yu L, Dai Z, Wang Z, Fan J, Zhou J, Prognostic indicators for tumor recurrence after liver transplantation in hepatocellular carcinoma and related molecular targeted therapy. *Oncology* 2011; **81 Suppl 1**: 116-122
- 7 Shih Ie M, Sheu JJ, Santillan A, Nakayama K, Yen MJ, Bristow RE, Vang R, Parmigiani G, Kurman RJ, Trope GG, Davidson B, Wang TL, Amplification of a chromatin remodeling gene, Rsf-1/HBXAP, in ovarian carcinoma. *Proc Natl Acad Sci U S A* 2005; **102**(39): 14004-14009
- 8 Nakayama K, Nakayama N, Jinawath N, Salani R, Kurman RJ, Shih Ie M, Wang TL, Amplicon profiles in ovarian serous carcinomas. *Int J Cancer* 2007; **120**(12): 2613-2617
- 9 Brown LA, Kalloger SE, Miller MA, Shih Ie M, McKinney SE, Santos JL, Swenerton K, Spellman PT, Gray J, Gilks CB, Huntsman DG, Amplification of 11q13 in ovarian carcinoma. *Genes Chromosomes Cancer* 2008; **47**(6): 481-489
- 10 Maeda D, Chen X, Guan B, Nakagawa S, Yano T, Taketani Y, Fukayama M, Wang TL, Shih Ie M. Rsf-1 (HBXAP) expression is associated with advanced stage and lymph node metastasis in ovarian clear cell carcinoma. *Int J Gynecol Pathol* 2011; **30**(1): 30-35
- 11 Kshirsagar M, Jiang M, Shih Ie M. DNA Damage Response is Prominent in Ovarian High-Grade Serous Carcinomas, Especially Those with Rsf-1 (HBXAP) Overexpression. *J Oncol* 2012; **2012**: 621685
- 12 Li Q, Dong Q, Wang E, Rsf-1 is overexpressed in non-small cell lung cancers and regulates cyclinD1 expression and ERK activity. *Biochem Biophys Res Commun*, 2012.
- 13 Tai HC, Huang HY, Lee SW, Lin CY, Sheu MJ, Chang SL, Wu LC, Shiue YL, Wu WR, Lin CM, Li CF. Associations of Rsf-1 overexpression with poor therapeutic response and worse survival in patients with nasopharyngeal carcinoma. *J Clin Pathol* 2012; **65**(3): 248-253
- 14 Fang FM, Li CF, Huang HY, Lai MT, Chen CM, Chiu IW, Wang TL, Tsai FJ, Shih Ie M, Sheu JJ. Overexpression of a chromatin remodeling factor, RSF-1/HBXAP, correlates with aggressive oral squamous cell carcinoma. *Am J Pathol* 2011; **178**(5): 2407-2415
- 15 Chen TJ, Huang SC, Huang HY, Wei YC, Li CF. Rsf-1/HBXAP overexpression is associated with disease-specific survival of patients with gallbladder carcinoma. *APMIS* 2011; **119**(11): 808-814
- 16 Mao TL, Hsu CY, Yen MJ, Gilks B, Sheu JJ, Gabrielson E, Vang R, Cope L, Kurman RJ, Wang TL, Shih Ie M. Expression of Rsf-1, a chromatin-remodeling gene, in ovarian and breast carcinoma. *Hum Pathol* 2006; **37**(9): 1169-1175
- 17 Shamay M, Barak O, Doitsh G, Ben-Dor I, Shaul Y. Hepatitis B virus pX interacts with HBXAP, a PHD finger protein to coactivate transcription. *J Biol Chem* 2002; **277**(12): 9982-9988
- 18 Loyola A, Huang JY, LeRoy G, Hu S, Wang YH, Donnelly RJ, Lane WS, Lee SC, Reinberg D. Functional analysis of the subunits of the chromatin assembly factor RSF. *Mol Cell Biol* 2003; **23**(19): 6759-6768
- 19 Shamay M, Barak O, Shaul Y. HBXAP, a novel PHD-finger protein, possesses transcription repression activity. *Genomics* 2002; **79**(4): 523-529
- 20 Vignali M, Hassan AH, Neely KE, Workman JL. ATP-dependent chromatin-remodeling complexes. *Mol Cell Biol* 2000; **20**(6): 1899-1910
- 21 Flanagan JF, Peterson CL. A role for the yeast SWI/SNF complex in DNA replication. *Nucleic Acids Res* 1999; **27**(9): 2022-2028
- 22 Cosma MP, Tanaka T, Nasmyth K. Ordered recruitment of transcription and chromatin remodeling factors to a cell cycle- and developmentally regulated promoter. *Cell* 1999; **97**(3): 299-311
- 23 Yuan BZ, Zhou X, Zimonjic DB, Durkin ME, Popescu NC. Amplification and overexpression of the EMS 1 oncogene, a possible prognostic marker, in human hepatocellular carcinoma. *J Mol Diagn* 2003; **5**(1): 48-53
- 24 Wen JM, Huang JF, Hu L, Wang WS, Zhang M, Sham JS, Xu JM, Zeng WF, Xie D, Liang LJ, Guan XY. Establishment and characterization of human metastatic hepatocellular carcinoma cell line. *Cancer Genet Cytogenet* 2002; **135**(1): 91-95
- 25 Kusano N, Shiraishi K, Kubo K, Oga A, Okita K, Sasaki K. Genetic aberrations detected by comparative genomic hybridization in hepatocellular carcinomas: their relationship to clinicopathological features. *Hepatology* 1999; **29**(6): 1858-1862
- 26 Ishak KG, Anthony PP, Sobin LH. Nonepithelial tumors. In: Ishak KG (ed): *Histological typing of tumors of the liver*. World Health Organization International Classification of tumors. (ed 2). Berlin: Springer 1994; 22-27
- 27 Poon RT, Ng IO, Lau C, Yu WC, Yang ZF, Fan ST, Wong J. Tumor microvessel density as a predictor of recurrence after resection of hepatocellular carcinoma: a prospective study. *J Clin Oncol* 2002; **20**(7): 1775-1785
- 28 Wittekind C. Pitfalls in the classification of liver tumors. *Pathologe* 2006; **27**(4): 289-293
- 29 Gao Q, Qiu SJ, Fan J, Zhou J, Wang XY, Xiao YS, Xu Y, Li YW, Tang ZY. Intratumoral balance of regulatory and cytotoxic T cells is associated with prognosis of hepatocellular carcinoma after resection. *J Clin Oncol* 2007; **25**(18): 2586-2593
- 30 Cai XY, Gao Q, Qiu SJ, Ye SL, Wu ZQ, Fan J, and T. ZY. Dendritic cell infiltration and prognosis of human hepatocellular carcinoma. *J Cancer Res Clin Oncol* 2006; **132**(5): 293-301
- 31 Yang XR, Xu Y, Shi GM, Fan J, Zhou J, Ji Y, Sun HC, Qiu SJ, Yu B, Gao Q, He YZ, Qin WZ, Chen RX, Yang GH, Wu B, Lu Q, Wu ZQ, Tang ZY. Cytokeratin 10 and cytokeratin 19: predictive markers for poor prognosis in hepatocellular carcinoma patients after curative resection. *Clin Cancer Res* 2008; **14**(12): p. 3850-3859.
- 32 Jiang YF, Yang ZH, Hu JQ. Recurrence or metastasis of HCC: predictors, early detection and experimental antiangiogenic therapy. *World J Gastroenterol* 2000; **6**(1): 61-65
- 33 Zhang M, Dai C, Zhu H, Chen S, Wu Y, Li Q, Zeng X, Wang W, Zuo J, Zhou M, Xia Z, Ji G, Saiyin H, Qin L, Yu L. Cyclophilin A promotes human hepatocellular carcinoma cell metastasis via regulation of MMP3 and MMP9. *Mol Cell Biochem* 2011; **357**(1-2): 387-395
- 34 Jemal A, Bray F, Center MM, Ferlay J, Ward E, Forman D. Global cancer statistics. *CA Cancer J Clin* 2011; **61**(2): 69-90
- 35 Huang JY, Shen BJ, Tsai WH, Lee SC. Functional interaction between nuclear matrix-associated HBXAP and NF-kappaB. *Exp Cell Res* 2004; **298**(1): 133-143
- 36 Zhan YJ, Jiang W, Chen CJ, Lee CS, Kahn SM, Santella RM, Weinstein IB. Amplification and overexpression of cyclin D1 in human hepatocellular carcinoma. *Biochem Biophys Res Commun* 1993; **196**(2): 1010-101
- 37 Tanaka Y, Kanai F, Tada M, Tateishi R, Sanada M, Nannya Y, Ohta M, Asaoka Y, Seto M, Shiina S, Yoshida H, Kawabe T, Yokosuka O, Ogawa S, Omata M. Gain of GRHL2 is associated with early recurrence of hepatocellular

- carcinoma. *J Hepatol* 2008; **49(5)**: 746-757
- 38 Zhang YJ, Chen SY, Chen CJ, Santella RM. Polymorphisms in cyclin D1 gene and hepatocellular carcinoma. *Mol Carcinog* 2002; **33(2)**: 125-129
- 39 Sawey ET, Chanrion M, Cai C, Wu G, Zhang J, Zender L, Zhao A, Busuttill RW, Yee H, Stein L, French DM, Finn RS, Lowe SW, Powers S. Identification of a therapeutic strategy targeting amplified FGF19 in liver cancer by Oncogenomic screening. *Cancer Cell* 2011; **19(3)**: 347-358
- 40 Dai CX, Gao Q, Qiu SJ, Ju MJ, Cai MY, Xu YF, Zhou J, Zhang BH, Fan J. Hypoxia-inducible factor-1 alpha, in association with inflammation, angiogenesis and MYC, is a critical prognostic factor in patients with HCC after surgery. *BMC cancer* 2009; **9**: 41
- 41 Li J, Lau GK, Chen L, Dong SS, Lan HY, Huang XR, Li Y, Luk JM, Yuan YF, Guan XY. Interleukin 17A promotes hepatocellular carcinoma metastasis via NF-kB induced matrix metalloproteinases 2 and 9 expression. *PLoS one* 2011; **6(7)**: e21816
- 42 Yeh MH, Kao ST, Hung CM, Liu CJ, Lee KH, Yeh CC. Hesperidin inhibited acetaldehyde-induced matrix metalloproteinase-9 gene expression in human hepatocellular carcinoma cells. *Toxicol Lett* 2009; **184(3)**: 204-210
- 43 Lee CF, Ling ZQ, Zhao T, Lee KR. Distinct expression patterns in hepatitis B virus- and hepatitis C virus-infected hepatocellular carcinoma. *World J Gastroenterol* 2008; **14(39)**: 6072-6077

Peer reviewer: Cerwenka R Herwig, Department of Surgery, Medical University of Graz, Auenbruggerplatz 29, A-8036 Graz, Austria.