

## Metastatic Hepatocellular Carcinoma on Single Agent Sorafenib: A Case Report

Mohamed Shanshal, Rami Haddad, Rami Y Haddad, Mark F Conneely

Mohamed Shanshal, Rami Haddad, Rosalind Franklin university, division of hematology/Oncology 4444 green bay Road, North Chicago, IL 6008, the United States

Rami Y Haddad, Affiliated Oncologists, LLC. Assoc. Professor of Medicine, CMS, Cancer Institute at Advocate Christ Medical Center and Advocate South Suburban Hospital, the United States

Mark F Conneely, Staff Radiologist, Captain James A. Lovell, Federal Health Care Center, Associate Professor of Radiology, Chicago Medical School, Rosalind Franklin University of Science and Medicine, Chicago, the United States

Correspondence to: Mohamed Shanshal, Rosalind Franklin university, division of hematology/Oncology 4444 green bay Road, North Chicago, IL 6008,

the United States. mohammedshanshal@yahoo.com

Telephone: +1-312-735-1995

Received: January 16, 2013      Revised: February 3, 2013

Accepted: February 12, 2013

Published online: June 21, 2013

### ABSTRACT

Despite the fact that hepatocellular carcinoma is the most common tumor in males worldwide, with approximately 1 million new cases reported annually, no effective systemic therapy exists for patients with advanced disease. Sorafenib which is a multikinase inhibitor of the vascular endothelial growth factor receptor, the platelet-derived growth factor receptor, and Raf, which was proven in 2007 for the treatment of advanced hepatocellular carcinoma. We report a case of a patient who responded completely and remain disease free for the last 3 years by using a single agent sorafenib. The clinical, radiologic, pathologic and treatment features of this entity are discussed.

© 2013 ACT. All rights reserved.

**Key words:** Sorafenib; Hepatocellular carcinoma

Shanshal M, Haddad R, Haddad RY, Conneely MF. Metastatic Hepatocellular Carcinoma on Single Agent Sorafenib: A Case Report. *Journal of Gastroenterology and Hepatology Research* 2013; 2(6): 658-660 Available from: URL: <http://www.ghrnet.org/index.php/joghr/article/view/411>

### INTRODUCTION

Hepatocellular carcinoma (HCC) is the fifth most common cancer, and the third leading cause of cancer death worldwide<sup>[1]</sup>. Cure rate for HCC is less than 5% of all patients, with a median survival from time of diagnosis is generally 6 months.

The incidence of HCC is highest in developing countries and around 80% of HCC occur in Sub-Saharan Africa, Southeast Asia, while in developed countries, e.g. in North America 6.8 cases per 100000 person-years for men; 2.2 cases per 100000 person-years for women<sup>[9]</sup>.

It frequently arises in the setting of cirrhosis, appearing 20-30 years following the initial insult to the liver. However, 25% of patients have no history or risk factors for the development of cirrhosis. The extent of hepatic dysfunction limits treatment options, and as many patients die of liver failure as from tumor progression.

A significant reduction in the incidence of hepatocellular carcinoma came from the vaccination strategies for hepatitis B virus (HBV) infection, in addition to screening and treatment for hepatitis C virus (HCV) infections, and from the reduction of alcoholic liver disease. However, because the latency period from hepatic damage to hepatocellular carcinoma development is very long (20 years), it may be many years until the incidence of hepatocellular carcinoma decreases as a result of these interventions.

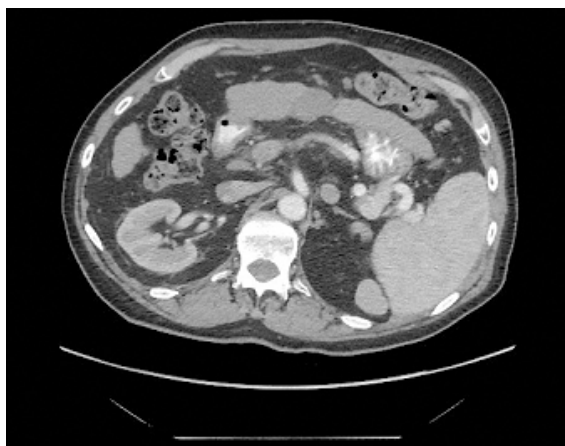
Recently, the rapid rise in obesity and diabetes is also thought to be contributing to the increased incidence of hepatocellular carcinoma. Fatty liver and nonalcoholic steatorrheic hepatitis, especially in men, can lead to cirrhosis and hepatocellular carcinoma<sup>[2,10]</sup>.

The American Cancer Society published estimates in 2011 that 26190 new cases of hepatocellular carcinoma and intrahepatic bile duct cancers were diagnosed in 2011. An estimated 19590 patient were expected to die of hepatocellular carcinoma and intrahepatic bile duct cancer in 2011<sup>[3]</sup>.

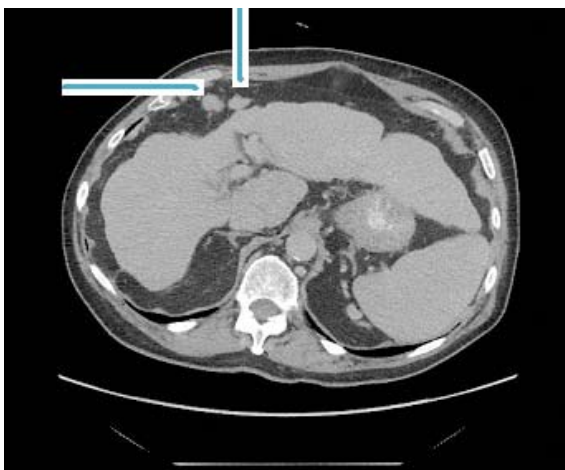
### CASE REPORT

A 76 Male with past medical history of liver cirrhosis secondary to chronic hepatitis C infection, diagnosed in 1988, came to the gastroenterology clinic for regular follow up.

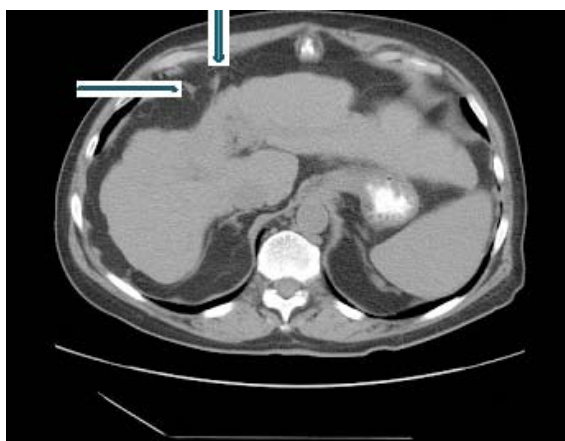
Work in 2008 showed elevated alpha fetoprotein level (AFP) and MRI revealed hepatic mass, liver biopsy confirmed the diagnosis of hepatocellular carcinoma.



**Figure 1** Portal venous phase post-contrast CT image demonstrating hypo-enhancing lesion at the site of prior radiofrequency ablation with no definite enhancement on arterial phase images to suggest local tumor recurrence.



**Figure 2** A more superior image demonstrating two omental nodules located anterior to the liver, suspicious for peritoneal metastatic nodules.



**Figure 3** Post treatment CT scan demonstrating marked interval decrease in size of the peritoneal nodules. The liver lesion had not significantly changed in size.

His lesion was unresectable because of his poor hepatic function and evidence of portal hypertension, and the patient was enrolled in a study which randomizes patients to standard therapies (including percutaneous radiofrequency ablation, chemoembolization, and radioembolization).

The patient underwent radiofrequency ablation in december 2009 but follow up scans revealed more disease in the liver with intra-peritoneal lymph node metastasis.

Patient was later on started on sorafenib 400 mg bidaily in December 2010, and was followed up in the oncology clinic on a monthly basis.

Patient tolerated the oral sorafenib therapy without significant side effects, other than of mild macular rash over the face.

Patient was followed every 3 months with repeated CT scans and AFP which showed a stable tumor size in the liver and significant decrease in AFP level to 3 from 1400 over 2010 to 2011.

## DISCUSSION

The treatment option of HCC vary according to the stage which in turn determines resectability of the disease<sup>[4]</sup>, screening for HCC in patients with cirrhosis is crucial, Since early detection offers the best opportunity for cure. Surveillance has to be based on ultrasound examination and AFP level. The recommended screening interval is 6 months. Diagnosis of HCC should be based on imaging techniques (MRI or contrast CT scans) and/or biopsy

Surgical resection of the tumor can achieve cure of HCC, particularly when the tumor is small (stage 1 or 2 TNM classification) and liver function is preserved. Liver transplantation is often the most effective treatment for HCC, if the tumor is.

Effective treatment for HCC is possible also in patients with more advanced disease. Trans-arterial chemoembolization (TACE), in which a chemotherapy mixture is injected directly into the tumor and its blood supply is interrupted, results in tumor death and is effective at controlling even larger tumors.

TACE is also useful to prevent tumors from growing while patients with smaller tumors are on the liver transplant waiting list. Radioembolization involves the injection of radiation-emitting beads into the tumor and is often an alternative option to TACE. Systemic chemotherapy in the form of the oral drug Sorafenib or clinical trials with newer drugs are also effective treatment options in advanced disease.

But in-spites of the multiple treatment modality, Treatment of hepatocellular carcinoma is different from that of other solid tumors, in that surgery plays a limited role while nonsurgical therapies are very instrumental. Sorafenib, is an oral kinase inhibitor, which was proved in 2007 after a phase III trial showed to prolong survival in patients with hepatocellular carcinoma<sup>[5]</sup>. This agent, which targets various pathways, including VEGFR, PDGFR, KIT, FLT-3, and RET, was compared to placebo in a trial of 602 patients. Median survival was prolonged significantly to 10.7 from 7.9 months, and time to progression was 5.5 months, compared with 2.8 in the placebo group. In HCC, the activation of the Raf-pathway in addition to high levels of VEGF was associated with enhanced tumor growth and survival by preventing apoptosis<sup>[6]</sup>.

Currently, this is the only FDA-approved antineoplastic for hepatocellular carcinoma. The revised National Comprehensive Cancer Network (NCCN) guidelines for hepatocellular carcinoma recommend sorafenib as a treatment option at several points in the treatment algorithm<sup>[7]</sup>.

The benefit of sorafenib is also demonstrated in a study by Abou-Alfa *et al*, which shows a longer overall and progression-free survival with the addition of sorafenib to doxorubicin. The same study underlines the lack of efficacy of doxorubicin alone<sup>[8]</sup>. Still unanswered is the question of whether doxorubicin adds any benefit to treatment with sorafenib by itself.

## REFERENCES

- 1 Jemal A, Siegel R, Ward E, Hao Y, Xu J, Murray T, Thun MJ. Cancer statistics, 2008. *CA Cancer J Clin* 2008; **58**: 71–96
- 2 Yasui K, Hashimoto E, Komorizono Y, Koike K, Arai S, Imai Y, Shima T, Kanbara Y, Saibara T, Mori T, Kawata S, Uto H, Takami S, Sumida Y, Takamura T, Kawanaka M, Okanoue T. Characteristics of patients with nonalcoholic steatohepatitis who develop hepatocellular carcinoma. *Clin Gastroenterol Hepatol.* 2011; **9**: 428-433
- 3 Bosch FX, Ribes J, Diaz M, Cléries R. Primary liver cancer: worldwide incidence and trends. *Gastroenterology* 2004; **127**(5 Suppl 1): S5-S16
- 4 Mendizabal M, Reddy KR. Current management of hepatocellular carcinoma. *Med Clin Nor Am* 2009; **93**: 885-900
- 5 Llovet JM, Ricci S, Mazzaferro V, Hilgard P, Gane E, Blanc JF, de Oliveira AC, Santoro A, Raoul JL, Forner A, Schwartz M, Porta C, Zeuzem S, Bolondi L, Greten TF, Galle PR, Seitz JF, Borbath I, Häussinger D, Giannaris T, Shan M, Moscovici M, Voliotis D, Bruix J. Sorafenib improves survival in advanced hepatocellular carcinoma (HCC): results of a phase III randomized placebo-controlled trial (SHARP trial). *J Clin Oncol* 2007; **25**(suppl): 962s(abstract LBA1)
- 6 Huynh H, Nguyen TT, Chow KH, Tan PH, Soo KC, Tran E. Overexpression of the mitogen-activated protein kinase (MAPK) kinase (MEK)-MAPK in hepatocellular carcinoma: its role in tumor progression and apoptosis. *BMC Gastroenterol* 2003; **3**: 19
- 7 National Comprehensive Cancer Network. NCCN Hepatobiliary Cancers Clinical Practice Guidelines in Oncology (Version 2.2008).
- 8 Abou-Alfa GK, Johnson P, Knox JJ, Capanu M, Davidenko I, Lacava J, Leung T, Gansukh B, Saltz LB. Doxorubicin plus sorafenib vs doxorubicin alone in patients with advanced hepatocellular carcinoma: a randomized trial. *JAMA* 2010; **304**: 2154-2160
- 9 Ferlay J, Shin HR, Bray F, Forman D, Mathers C and Parkin DM. GLOBOCAN 2008, Cancer Incidence and Mortality Worldwide: IARC CancerBase No. 10 Lyon, France: International Agency for Research on Cancer [online], <http://globocan.iarc.fr> (2010)
- 10 Bugianesi E. Non-alcoholic steatohepatitis and cancer. *Clin Liver Dis* 2007; **11**: 191-207

**Peer reviewer:** Lin Jia, Department of Internal Medicine, Division of Hypothalamic Research, University of Texas Southwestern Medical Center at Dallas, 5323 Harry Hines Boulevard, Dallas, Texas, 75390, USA.