

Progressive Familial Intrahepatic Cholestasis Type 3: A Novel Mutation in a Saudi Child

Naglaa Mohamed Kamal-Alanani, Ayman Amin Bakar, Abdullah O Al-Harbi, Hamid El-Ghamdi, Mortada Hassan El-Shabrawi, Laila M Sherief

Naglaa Mohamed Kamal-Alanani, Associate Professor of Pediatrics, Pediatric Hepatology, Faculty of Medicine, Cairo University, Cairo, Egypt; Consultant Pediatrician, Al-Hada Armed Forces Hospital, Taif, Saudi Arabia

Ayman Amin Bakar, Consultant pediatrician, Al-Hada Armed Forces Hospital, Taif, Saudi Arabia

Abdullah O Al-Harbi, Consultant pediatrician, Director of pediatric department, Al-Hada Armed Forces Hospital, Taif, Saudi Arabia

Hamid El-Ghamdi, Consultant pediatrician, Director of Prince Mansour Military Hospital, Taif, Saudi Arabia

Mortada Hassan El-Shabrawi, Professor of Pediatrics, Head of Pediatric Hepatology, Faculty of Medicine, Cairo University, Cairo, Egypt

Laila M Sherief, Professor of Pediatrics, Faculty of Medicine, Zagazig University, Egypt.

Correspondence to: Naglaa Mohamed Kamal-Alanani, MD, Associate Professor of Pediatrics, Pediatric Hepatology Unit, Faculty of Medicine, Cairo University, Egypt. Nagla.kamal@kasralainy.edu.eg

Telephone: +201141991114 Fax: +96627543120

Received: January 15, 2013 Revised: January 29, 2013

Accepted: February 23, 2013

Published online: June 21, 2013

ABSTRACT

Progressive familial intrahepatic cholestasis type 3 (PFIC3) is caused by defects in ABCB4 gene. Liver histology although important, but is nonspecific, and molecular genetic testing is essential for diagnosis. To report PFIC3 in a Saudi male child and determine the pathogenetic role of a novel of ABCB4 in one of them. Liver biopsy, immunohistochemical analysis for MDR3 protein expression and molecular genetic analysis were done for the patient. Liver biopsy showed extensive ductular reaction with portal and periportal fibrosis. Immunohistochemical analysis revealed absence of MDR3 protein expression at the canalicular pole. Molecular genetic analysis revealed a novel mutation in ABCB4: the c.1783 C > T (p.Arg595X) mutation in exon 15 in homozygous state. A novel loss-of-function mutation has been identified. Molecular genetic testing is essential and conclusive for diagnosis.

Key words: Progressive familial intrahepatic cholestasis type 3; ABCB4 gene mutations; Children; Saudi Arabia

Kamal-Alanani NM, Bakar AA, Al-Harbi AO, El-Ghamdi H, El-Shabrawi MH, Sherief LM. Progressive Familial Intrahepatic Cholestasis Type 3: A Novel Mutation in a Saudi Child. *Journal of Gastroenterology and Hepatology Research* 2013; 2(5): 655-657 Available from: URL: <http://www.ghrnet.org/index.php/joghr/article/view/410>

INTRODUCTION

PFIC refers to heterogeneous group of autosomal recessive disorders of childhood that disrupt bile formation and present with pruritus and cholestasis of hepatocellular origin^[1,2].

Three distinct forms are described: PFIC1 or Byler disease^[3] [OMIM211600] and PFIC2 or bile salt export pump (BSEP) disease^[4] [OMIM 601847], that are caused by impaired bile salt secretion and are associated with a low or normal serum gamma glutamyl transpeptidase (GGT) activity, and PFIC3 or multidrug resistance protein 3 (MDR3) disease^[5] [OMIM 171060], impair biliary phospholipid (PL) secretion and is associated with a high serum GGT activity.

PFIC1 and PFIC2 usually appear in the first months of life, whereas PFIC3 occurs later in infancy, in childhood or even during young adulthood. PFIC patients usually develop fibrosis and end-stage liver disease before adulthood^[1]. Death from liver failure usually occurs if LTx is not performed^[6].

Liver histology in PFIC1, is characterized by canalicular cholestasis and the absence of true ductular proliferation with only periportal biliary metaplasia of hepatocytes. Same findings are seen in PFIC2 but the liver architecture is more perturbed, with more pronounced hepatocellular necrosis, giant cell transformation, lobular and portal fibrosis and inflammation^[7-9]. In PFIC3, portal fibrosis and true ductular proliferation with mixed inflammatory infiltrate are the main characteristics^[1]. Cytokeratin immunostaining confirms the strong ductular proliferation within the portal tract. At a later stage, there is extensive portal fibrosis and a typical picture of biliary cirrhosis^[2].

MDR3 is expressed, almost exclusively, at the canalicular membrane of the hepatocytes. Its main role is the excretion of biliary PLs. In PFIC 3, there is malfunction of MDR3 resulting in

cholestasis which resulted from the toxicity of bile in which detergent bile salts are not neutralized by PLs, leading to bile canaliculi and biliary epithelium injuries. The absence of PLs in bile destabilize micelles and promote lithogenicity of bile with crystallization of cholesterol, leading to obstruction of small bile ducts and ductular reaction^[7-8].

In the present study we report a Saudi child with PFIC3 in whom liver histology showed extensive ductular reaction with portal and periportal fibrosis. Genotyping revealed a novel mutations in the PFIC3 gene, ABCB4 which is considered the 1st case with this mutation in KSA and the 2nd reported in literature after that reported by Giovannoni *et al*^[2].

CASE REPORT

SA is a 2-year-and 8-month old Saudi male child who was born to healthy first-degree Saudi cousins, at term with uneventful perinatal history and normal developmental history with negative family history of liver disease. His parents noticed generalized abdominal distension at the age of 1 year for which they sought medical advice but unfortunately was not investigated until he presented to us 4 months ago with mild jaundice and itching all over the body added to the existing chronic abdominal distension. On examination, there was tinge jaundice and hepatomegaly. Liver felt 4 cm in Rt MCL, 3 cm in midline with hepatic span 10.5 cm in the Rt MCL. It was firm in consistency with smooth surface. No splenic enlargement with unremarkable other body system review. Laboratory investigations revealed; mild cholestatic jaundice with total bilirubin 45 umol/L and direct bilirubin 35 umol/L, high transaminases with ALT: 569 IU/L (0-55) and AST: 526 IU/L (5-34), high GGT 333 IU/L (<55), and high alkaline phosphatase 1106 IU/L with normal synthetic functions. Serum total bile acids were high 185.6 umol/L (0-8) with high serum primary bile acids levels [Cholic Acid: 70.2 umol/L (10.0-24.0), Chenodesoxycholic Acid: 29.3 umol/L (29.0-46.0)], and low secondary serum bile acids levels [Deoxycholic Acid: 0.4 umol/L (2.5-15.0), and Lithocholic Acid: 0.0 umol/L (0.0-2.0)]. Phospholipid concentration was not available.

Liver biopsy was performed and was suggestive of advanced fibrosis (stage 3) and early cirrhotic changes. There was slightly altered hepatic architecture by the presences of focal bridging fibrosis, mild centrilobular fibrosis and micronodules with evidence of cholestatic hepatitis and giant cell transformation. Portal tracts showed inflammatory infiltrates with lymphocytes, polymorph nuclear leucocytes & eosinophils with bile ductular proliferation with normal small and large bile ducts with no evidence of bile ducts damage (Figure 1 A, B, C, D). In addition to histological processing, immunohistochemistry was performed for cytokeratin 7 & 19 and confirmed marked bile ductular proliferation (Figure 1 D, E).

Immunohistochemistry for MDR3 protein showed complete absence of canalicular immunostaining for MDR3 protein.

Genomic DNA was purified from peripheral blood and the coding exons 1-28 and the exon-intron boundaries of the ABCB4 gene (OMIM 171060) were amplified by polymerase chain reaction^[10], and sequenced directly. The resulting sequence data were compared with the reference sequence NM_000443.3. Sequencing analysis revealed at position c.1783 in exon 15 of the ABCB4 gene, the nucleotide exchange C to T homozygous state (c.1783C>T). This nonsense substitution truncates the protein at codon 595 (p.Arg595X), thus generating a presumably non-functional protein.

Thus our patient carries the mutation c.1783 C>T (p.Arg595X) in the ABCB4 gene in the homo-/hemizygous state.

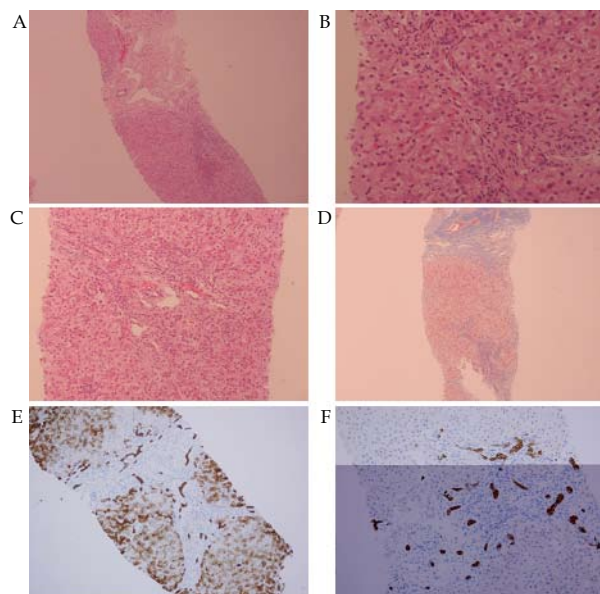


Figure 1 A: Core biopsy of the liver showing inflammation and fibrosis; B: HE; Cholestatic hepatitis with giant cell transformation and some eosinophilic necrotic hepatocytes. Portal zone; showing bile ductular proliferation and increased inflammatory cellular infiltrate; C: Lobular activity with active inflammation and focal necrosis; D: Trichrome stain; showing Lobular activity with active inflammation and focal necrosis, E and F: Cytokeratin immunostain showing increased number of periportal ductules and interlobular bile ducts and portal and pericellular fibrosis.

DISCUSSION

Both the clinical and pathological findings of PFIC 3 are not confirmatory alone. MDR3 immunostaining in the liver and ABCB4 testing are essential to confirm diagnosis. PFIC3 is caused by mutations of the ATP-binding cassette subfamily B (MDR/TAP) member 4 (ABCB4) gene, also known as MDR3. ABCB4 belongs to the superfamily of membrane transporters that contain an ATP-binding cassette (ABC-transporters)^[11] and hydrolyze ATP during translocation of a wide variety of molecules across membranes, a function that requires the concerted action of two ABC transmembrane domains and two ABC transporter domains^[12]. Specifically, the domains essential for organic molecule efflux are arranged along the ABCB4 protein sequence in the amino acid ranges 57-359 (1st ABC transmembrane transporter), 394-630 (1st ABC transporter), 711-999 (2nd ABC transmembrane transporter) and 1034-1279 (2nd ABC transporter) according to Prosite database^[2].

Most of the mutations identified in ABCB4 gene were described by Degiorgio and his colleagues 2007, table 1^[10]. The mutation identified in this study is the 1st novel mutation reported from KSA and the 2nd in literature after the report of Giovannoni *et al*^[2].

This mutation is predicted to generate proteins that are unable to carry out their transporter function, that is why liver immunohistochemistry did not show any canalicular staining for MDR3, suggesting that the mutant protein cannot reach the canalicular membrane.

On the other hand, normal or slightly reduced canalicular staining does not exclude the presence of MDR3 dysfunction^[13]. That is the reason why direct gene testing is mandatory^[2].

The current report presented a loss-of-function mutation in a Saudi child. Although occasionally described in Saudi Arabia, this report confirms that PFICs, in particular MDR3 deficiency, have a worldwide distribution^[14-15] and that are probably underestimated.

⁴ **Table 1** Mutations identified in ABCB4^[10].

Exons	cDNA locus ¹	Type of mutation ²		ABCB4-predicted domain	GenBank accession number ³
		Missense	Frameshift or nonsense		
Exon 6	c.377G>A	G126E		TM2	DQ861346
Exon 6	c.523A>G	T175A		ICD1	
Exon 6	c.475C>T		R159X	ICD1	DQ861347
Exon 8	c.748G>C	A250P		ICD2	DQ861349
Exon 9	c.837T>A		Y279X	ICD2	DQ861348
Exon 9	c.857C>T	A286V		ICD2	DQ861350
Exon 9	c.959C>T	S320F		TM5	
Exon 10	c.1069T>C	F357L		ICD3	DQ861351
Exon 10	c.1091C>T	A364V		ICD3	DQ861352
Exon 11	c.1135_1136insAA		S379KfsX413	ICD3	DQ861353
Exon 11	c.1207T>C	Y403H		NBD-NH2 A-loop	EF035007
Exon 13	c.1424T>C	V475A		NBD-NH2 ter	DQ861354
Exon 13	c.1531G>A	A511T		NBD-NH2 ter	DQ861355
Exon 14	c.1672G>A	E558K		NBD-NH2 ter	DQ861356
Exon 15	c.1769G>A	R590Q		NBD-NH2 ter	
Exon 15	c.1777A>G	T593A		NBD-NH2 ter	DQ861357
Exon 15	c.1888A>G	M630V		NBD-NH2 ter	DQ861358
Exon 17	c.2102T>C	L701P		Linker region	DQ861359
Exon 17	c.2144C>T	T175I		TM7	DQ861360
Exon 17	c.2168G>A	G723E		TM7	DQ861361
Exon 17	c.2169_2170insG		L724AfsX744	TM7	DQ861362
Exon 17	c.2176C>A	P726T		TM7	DQ861363
Exon 17	c.2210C>T	A737V		EC4	DQ861364
Exon 18	c.2284G>T		G762X	TM8	DQ861365
Exon 19	c.2324C>T	T775M		TM8	
Exon 21	c.2519C>A	A840D		TM9	DQ861366
Exon 21	c.2662G>T		E888X	ICD5	DQ861367
Exon 23	c.2860G>A	G954S		TM11	DQ861368
Exon 27	c.3577G>A	A1193T		NBD-COOH ter	DQ861369

¹ cDNA sequence is based on reference sequence GenBank NM_018849. The A of the ATG of the initiator Met codon is reported as nucleotide+1; ² The protein GenBank reference number is NP_061337; ³ Accession number of the new mutations; ⁴ Reproduced with license from Nature Publishing Group.

CONCLUSIONS

PFIC3 is probably less rare than usually thought. We present a case of Asian origin harbouring novel variant in ABCB4. Morphological studies alone are not sufficient for a firm diagnosis of MDR3 deficiency which requires direct gene testing.

REFERENCES

- Davit-Spraul A, Gonzales E, Baussan C, Jacquemin E. Progressive familial intrahepatic cholestasis. *Orphanet J Rare Dis* 2009; **8**; 4
- Giovannoni I, Santorelli FM, Candusso M, Di Rocco M, Bellacchio E, Callea F, Francalanci P. Two novel mutations in African and Asian children with progressive familial intrahepatic cholestasis type 3. *Dig Liver Dis* 2011; **43**: 567-570
- van Mil SW, Klomp LW, Bull LN, Houwen RH. FIC1 disease: a spectrum of intrahepatic cholestatic disorders. *Semin Liver Dis* 2001; **21**: 535-544
- Lam P, Soroka CJ, Boyer JL. The bile salt export pump: clinical and experimental aspects of genetic and acquired cholestatic liver disease. *Semin Liver Dis* 2010; **30**(May):125-33 [Review].
- Gonzales E, Davit-Spraul A, Baussan C, Buffet C, Maurice M, Jacquemin E. Liver diseases related to MDR3 (ABCB4) gene deficiency. *Front Biosci* 2009; **14**: 4242-4256
- Shneider BL. Progressive intrahepatic cholestasis: mechanisms, diagnosis and therapy. *Pediatr Transplant* 2004; **8**: 609-612
- Chen HL, Chang PS, Hsu HC, Ni YH, Hsu HY, Lee JH, Jeng YM, Shau WY, Chang MH. FIC1 and BSEP defects in taiwanese patients with chronic intrahepatic cholestasis with low gammaglutamyltranspeptidase levels. *J Pediatr* 2002; **140**: 119-124
- Lykavieris P, van Mil S, Cresteil D, Fabre M, Hadchouel M, Klomp L, Bernard O, Jacquemin E. Progressive familial intrahepatic cholestasis type 1 and extrahepatic features: no catch-up of stature growth, exacerbation of diarrhea, and appearance of liver steatosis after liver transplantation. *J Hepatol* 2003; **39**: 447-452
- Jacquemin E. Progressive familial intrahepatic cholestasis. Genetic basis and treatment. *Clin Liver Dis* 2000; **4**: 753-763
- Degiorgio D, Colombo C, Seia M, Porcaro L, Costantino L, Zazzeron L, Bordo D, Coviello DA. Molecular characterization and structural implications of 25 new ABCB4 mutations in progressive familial intrahepatic cholestasis type 3 (PFIC3). *Eur J Hum Genet* 2007; **15**: 1230-1238
- Trauner M, Fickert P, Wagner M. MDR3 (ABCB4) defects: a paradigm for the genetics of adult cholestatic syndromes. *Semin Liver Dis* 2007; **27**: 77-98 [Review].
- Rosmorduc O, Poupon R. Low phospholipid associated cholelithiasis: association with mutation in the MDR3/ABCB4 gene. *Orphanet J Rare Dis* 2007; **2**: 29 [Review].
- Davit-Spraul A, Gonzales E, Baussan C, Jacquemin E. The spectrum of liver diseases related to ABCB4 gene mutations: pathophysiology and clinical aspects. *Semin Liver Dis* 2010; **30**: 134-146
- Jacquemin E, De Vree JM, Cresteil D, Sokal EM, Sturm E, Dumont M, Scheffer GL, Paul M, Burdelski M, Bosma PJ, Bernard O, Hadchouel M, Elferink RP. The wide spectrum of multidrug resistance 3 deficiency: from neonatal cholestasis to cirrhosis of adulthood. *Gastroenterology* 2001; **120**: 1448-1458
- Chen HL, Chang PS, Hsu HC, Lee JH, Ni YH, Hsu HY, Jeng YM, Chang MH. Progressive familial intrahepatic cholestasis with high gamma-glutamyltranspeptidase levels in Taiwanese infants: role of MDR3 gene defect? *Pediatr Res* 2001; **50**: 50-55

Peer reviewer: Seyed Mohsen Dehghani, MD, Associate Professor of Pediatric Gastroenterology, Gastroenterohepatology Research Center, Shiraz Transplant Research Center, Nemazee Hospital, Shiraz University of Medical Sciences, Shiraz, 71937-11351, Iran.