

Giant Splenic Cyst with Hypersplenism: Laparoscopic Splenectomy

Mohamed E Abd Ellatif

Mohamed E Abd Ellatif, General Surgical Department, Faculty Of Medicine, Mansoura University, Mansoura, Egypt

Correspondence to: Mohamed E Abd Ellatif, MD, General Surgical Department, Faculty Of Medicine, Mansoura University, Mansoura, Egypt. surg_latif@hotmail.com

Received: September 27, 2012 Revised: November 2, 2012

Accepted: November 6, 2012

Published online: April 21, 2013

ABSTRACT

Splenic cysts are rare lesions with approximately 800 cases reported in the world literature. Splenic cysts associated with hypersplenism are even rarer and only few cases have been described. They have been classified as "true" or "pseudo" cysts based on the presence or absence of an epithelial lining. We report a case of giant true splenic cyst. A 29-year-old Saudi woman presented with one year history of abdominal pain and sensation of fullness in her left upper abdomen. She gave a vague history of abdominal trauma one year back. Abdominal ultrasonography and Computed Tomography (CT) revealed a giant splenic cyst almost replacing the splenic parenchyma and abutting the splenic hilum. Laboratory tests revealed a picture of hypersplenism. She was treated successfully by laparoscopic splenectomy. The pathological examination confirmed a true cyst with epithelial lining. Postoperative recovery was uneventful, and the blood count returned normal.

© 2013 ACT. All rights reserved.

Key words: Epithelial cyst; Hypersplenism; Laparoscopic splenectomy

Abd Ellatif M. Giant Splenic Cyst with Hypersplenism: Laparoscopic Splenectomy. *Journal of Gastroenterology and Hepatology Research* 2013; 2(4): 549-551 Available from: URL: <http://www.ghrnet.org/index./joghr/>

INTRODUCTION

Splenic cysts have been classified as "true" or "pseudo" cysts based on the presence or absence of an epithelial lining. True cysts have a cellular lining that can be caused by congenital events or parasitic infection (*Echinococcus*). Pseudocysts have no cellular lining and

may be of hemorrhagic, serous, inflammatory, or degenerative origin. Congenital nonparasitic cysts of the spleen are rarely met in clinical practice, representing approximately 10% of all splenic cysts^[1]. They are also called true, congenital, epidermoid or epithelial cysts. We report the case of a giant epithelial cyst of the spleen, which was diagnosed before surgery as pseudocyst.

CASE REPORT

A 29-year-old Saudi woman presented to our clinic with one year history of a progressively painful lump and sensation of fullness in the left upper quadrant of the abdomen which increased mainly among the last 3-months. A vague history of trauma to abdomen was present. On examination, the patient was pale and all vital parameters were stable. A mass measuring 10-15 cm with smooth surface and cystic consistency was palpated in left hypochondrium. Laboratory investigations showed thrombocytopenia (81×10^3), leukopenia (2.6×10^3) and anaemia (Hb=8.2 gm%). Peripheral smear showed pancytopenia and a reticulocyte count of 2.5%. Bone marrow was hypercellular with erythroid hyperplasia. *Echinococcus* IgG antibody test was negative and oesophago-gastric-duodenoscopy did not show any evidence of portal hypertension.

Ultrasonography (US) and Computed tomography (CT) indicated the presence of a normal sized spleen with a cyst located on the medial surface and upper pole of the spleen (Figure 1). The mass was well circumscribed and homogeneous. The pancreas and both kidneys were normal. Polyvalent pneumococcal vaccine was administered.

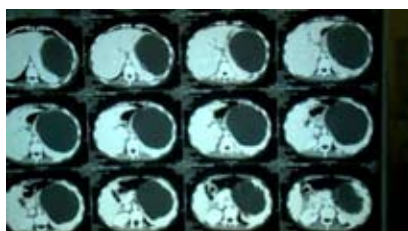


Figure 1 Computed Tomographic image of the upper abdomen demonstrating a very large, homogeneous splenic cyst.

The procedure started placing the patient in right semi-lateral position and 30° right lateral table tilt and reverse Trendelenberg position. Three ports were placed (Figure 2). There was a giant cyst at the medial surface and the upper pole of the spleen, involving

the hilum, separable from stomach and pancreas. Plenty of thick adhesions between the cyst and the parietal peritoneum were present. Aspiration of the cyst was necessary and yield 1 400 mL of yellowish thick fluid (Figure 3).

We chose the “infero-lateral approach”, dividing the phrenocolic, splenocolic and lino-renal ligaments using Ligasure instrument followed by dissection of the gastro-splenic ligaments with short gastric vessels (Figure 4). Splenic vessels were ligated at the hilum with 2-0 Vicryl double ligature. A drain was placed and kept for one day. The spleen was taken out through 3-4 cm Pfannenstiel incision (Figures 5, 6).

Light-microscopical examination showed interior lining of tubulocolumnar, pseudostratified (mesothelial line) epithelium that was consistent with the diagnosis of an epithelial cyst (Figure 7). Fluid culture showed no growth. Postoperative recovery was uneventful, and blood parameters returned normal. The patient was discharged on postoperative day 3 .

DISCUSSION

Splenic cysts are rare lesions. Pathogenesis of the true cysts is not entirely clarified and there are many theories by different authors. It has been suggested that they are derived from inclusions of the mesothelial lining of the splenic surface in the splenic parenchyma during development^[2]. Patients with congenital splenic cysts are younger than those with false cysts, and marked

female preponderance is observed^[2,3]. They are usually discovered incidentally because of the lack of typical clinical symptoms, and are generally diagnosed after compression of neighboring organs. Diagnosis is easily made by noninvasive imaging. Cysts arising from adjacent organs, especially from the tail of the pancreas, can be differentiated by ultrasonic examination^[2,4,5].

Diagnosis of splenic cysts is generally based on radiological examination (US, CT, magnetic resonance imaging)^[5]. Aspiration of the cyst content will not further differentiate true from false cysts or subclassify the congenital cyst^[1]. By histology, it is possible to know whether the cyst is primary or secondary (no cellular lining) and to determine its precise nature.

Surgery is primarily recommended for the prevention or treatment of complications. Decisions about the exact surgical procedure are based on the size of the cyst, its relation to the splenic hilar vessels and parenchyma, and the amount of healthy splenic tissue remaining^[6].

The recent options of management consist of percutaneous aspiration or percutaneous drainage^[7], partial splenectomy with a stapler or with harmonic scalpel, total cystectomy, marsupialization

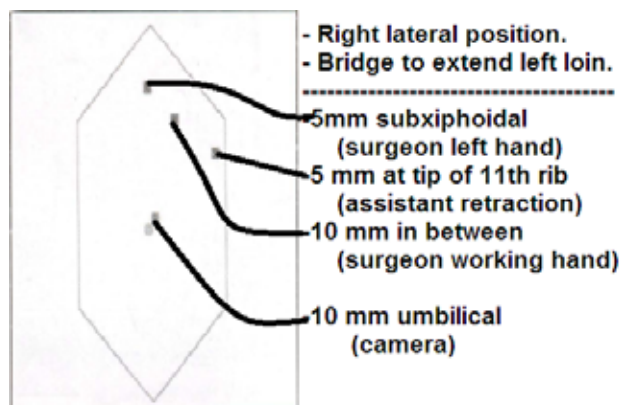


Figure 2 Port position and theatre layout.



Figure 3 Intraoperative image of the large spleen after initial aspiration.

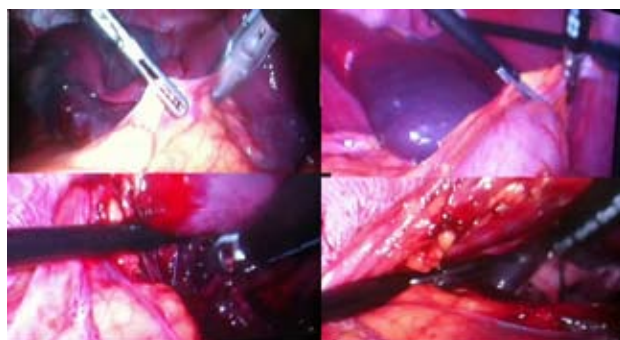


Figure 4 Infero-lateral approach.

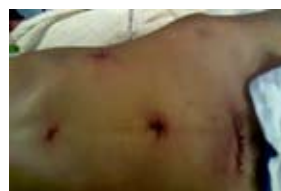

Figure 5 Image of the 4 ports and Pfannenstiel incision.

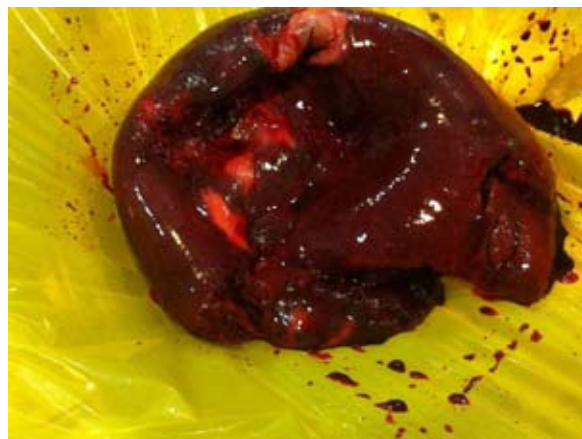

Figure 6 Specimen after retrieval.

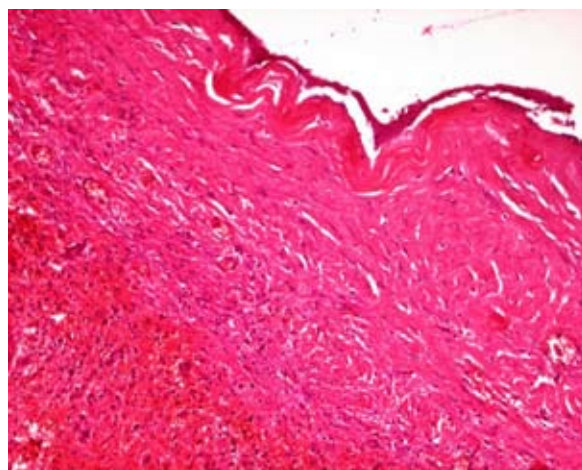


Figure 7 Interior lining of tubulocolumnar, pseudostratified (mesothelial line) epithelium.

or cyst decapsulation (unroofing)^[8], laparoscopic puncture and creation of a cyst peritoneal window^[4]. Access can be either via laparotomy or laparoscopy. Partial splenectomy should preserve more than 25% of the splenic parenchyma, which is the minimal splenic tissue to ensure immunologic protection without increasing the risk of recurrences^[9].

Although literature offers the possibility of providing conservative or semiconservative treatment, in our case, the cyst was bigger than the residual splenic parenchyma, which was reduced to a small remnant, so it would have been impossible to perform a simple cystectomy or partial splenectomy to preserve the spleen. Furthermore, the cyst encompassed the hilum of the spleen. Total splenectomy, vaccination, and long-term antibiotic prophylaxis is a viable alternative when needed.

Few cases of hypersplenism associated with true splenic cyst have been reported. Increased destruction of red blood cells and pooling of blood in the enlarged spleen are considered responsible for hypersplenism associated with cyst of spleen^[10].

Our case suggests that laparoscopic splenectomy is an effective method of management for such cyst involving the hilar region of the spleen or almost replacing the splenic parenchyma. Intraoperative suction of such cysts under laparoscopic guidance greatly facilitates laparoscopic splenectomy. The use of Pfannenstiel incision for specimen retrieval significantly reduces operating time as compared to piecemeal removal of the specimen by enlarging one of the ports.

CONCLUSIONS

Laparoscopic splenectomy is an effective method of management for cysts involving the hilar region of the spleen or almost replacing the splenic parenchyma.

REFERENCES

- 1 Erlich P, Jameison CG. Nonparasitic splenic cyst: a case report and review. *Can J Surg* 1990; **33**: 306-308
- 2 Morgenstern L. Nonparasitic splenic cysts: pathogenesis, classification, and treatment. *J Am Coll Surg* 2002; **19**: 306-314
- 3 Birmole BJ, Kulkarni BK, Vaydia MM, Borwanker SS. Splenic cysts. *J Postgrad Med* 1993; **39**: 40-41
- 4 Daga G, Mittal V, Singh RJ, Sood N. Epithelial cyst of the spleen. *J Indian Assoc Pediatr Surg* 2011; **16**(1): 18-20
- 5 Gorg C, Schwerk WB. Sonographic investigation in the diagnosis of intrasplenic fluid collections. *Bildgebung* 1991; **58**: 76-82
- 6 Kalinova K. Giant pseudocyst of the spleen: A case report and review of the literature. *J Indian Assoc Pediatr Surg* 2005; **10**(3): 176-178
- 7 López Cano A, Muñoz Benvenuty A, Méndez Pérez C, Herrera M, Ortiz Acero I, Benvenuty Espejo R. Treatment of non-parasitic splenic cyst with percutaneous injection of alcohol. *Gastroenterol Hepatol* 2001; **24**(4): 199-201
- 8 Matsutani T, Uchida E, Yokoyama T, Matsushita A, Matsuda A, Sasajima K. Laparoscopic Unroofing of a Large Pseudocyst of the Spleen: Report of a Case. *J Nippon Med Sch* 2009; **76**: 319-322
- 9 Hansen MB, Moller AC. Splenic cysts. *Surg Laparosc Endosc Percutan Tech* 2004; **14**: 316-322
- 10 Marterre WF Jr, Sugerman HJ. True splenic cyst associated with hypersplenism. *Arch Surg* 1986; **121**(7): 859

Peer reviewer: Gianluca Pellino, MD, General Surgery Unit, Second University of Naples, Via Giotto, 60, 81031, Aversa (CE), Italy.