

Journal of Gastroenterology and Hepatology Research

Online Submissions: <http://www.ghrnet.org/index./joghr/>
doi: 10.17554/j.issn.2224-3992.2022.11.1046

Journal of GHR 2022 April 21; **11(2)**: 3700-3705
ISSN 2224-3992 (print) ISSN 2224-6509 (online)

ORIGINAL ARTICLE

Effect of Acemannan Sponge on Implant Stability for Implant Assisted Overdenture

Ibrahim Ahmed Dahab¹, Akira Yagi², Mohammed Hassan Esmail³

1 Lecturer of Prosthodontics, Faculty of Dentistry, Tanta University, Egypt;

2 Special advisor of Japan Aloe Science Association, Editor in-Chief of Journal of Gastroenterology and Hepatology Research; Emeritus Professor, Fukuyama University, Hiroshima, Japan;

3 Lecturer of Removable Prosthodontics, Faculty of Dental Medicine, King Salman International University, South Sinai, Egypt.

Conflict-of-interest statement: The authors declare that there is no conflict of interest regarding the publication of this paper.

Open-Access: This article is an open-access article which was selected by an in-house editor and fully peer-reviewed by external reviewers. It is distributed in accordance with the Creative Commons Attribution Non Commercial (CC BY-NC 4.0) license, which permits others to distribute, remix, adapt, build upon this work non-commercially, and license their derivative works on different terms, provided the original work is properly cited and the use is non-commercial. See: <http://creativecommons.org/licenses/by-nc/4.0/>

Correspondence to: Akira Yagi, 2-10-1 Hanagaura-ku, Kasuyamachi, Kasuya-gun, Fukuoka-ken, Japan 811-2310.

Email: 0131akirayagi@gmail.com

Telephone: +81-92-938-2717

Received: January 26, 2022

Revised: February 23, 2022

Accepted: February 26, 2022

Published online: April 21, 2022

ABSTRACT

AIM: The present study was conducted to evaluate the effect of aloe vera gel on implant stability for implant assisted overdenture.

MATERIAL AND METHODS: Aloe vera gel high molecular weight fractions (AHM) containing native ingredients of polysaccharide (acemannan) and glycoprotein (verectin) were obtained by using the patented hyper dry system after washing out colored materials with running water from aloe vera gel slurry. Ten completely edentulous male patients aged from sixty to seventy years were selected from patients attending outpatient clinic of Prosthodontics department. Each patient had received two implants in the canine region for

implant assisted overdenture. The study was conducted as split mouth study design in which the comparison was done between **Group I:** the right side of the patient in which the implant is inserted in the osteotomy site in conventional way and **Group II:** the left side of the patient in which aloe vera sponge was inserted in the osteotomy site before implant placement. All cases were received the overdenture at time of implant placement as immediate loading protocol and the implant stability was recorded and compared between Group I and Group II by OSSTELL device at time of insertion, six months, twelve months follow up periods.

RESULTS: There was an increase in the numerical implant stability quotient (ISQ) values for Group II over Group I during the follow-up period. However, the difference was statistically non-significant as P value was ≥ 0.005 .

CONCLUSION: Aloe vera sponge shows promising results in its effect on the osseointegration and implant stability for immediate loading implant assisted overdenture that appear ISQ values during the follow up period.

Key words: Acemannan sponge; Aloe vera gel; Implant assisted overdenture; Implant stability

© 2022 The Authors. Published by ACT Publishing Group Ltd. All rights reserved.

Dahab IA, Yagi A, Esmail MH. Effect of Acemannan Sponge on Implant Stability for Implant Assisted Overdenture. *Journal of Gastroenterology and Hepatology Research* 2022; **11(2)**: 3700-3705 Available from: URL: <http://www.ghrnet.org/index.php/joghr/article/view/3284>

INTRODUCTION

For completely edentulous patients, the continuous alveolar ridge resorption leads to volumetric and anatomical changes in the denture foundation area. The bone loss of the posterior mandible eventually causes prominent mylohyoid ridge covered by thin movable unattached mucosa. Anteriorly, the residual ridge continues to resorb altering the position of superior genial tubercles. These problems make challenge for the prosthodontist to manage^[1].

The use of dental implants under complete dentures has been a turning point that greatly improved their performance. The term over-

denture emerged to describe a complete or partial removable denture assisted by retained roots, teeth or implants. The data from several randomized studies confirm that implant assisted overdentures provide a better outcome than conventional dentures. Overdentures improve patient satisfaction and increase the chewing ability and therefore the general health of the patient^[2].

Successful osseointegration has been viewed as a direct structural and functional connection existing between ordered, living bone and the surface of the implant^[3]. Under a light microscope, histologic appearance resembled a functional ankylosis with no intervention of fibrous or connective tissue between bone and implant surface^[4]. Osseointegration is also a measure of implant stability, which can occur at two different stages: primary and secondary stability. Primary (mechanical) stability of an implant mostly comes from mechanical engagement with cortical bone. Secondary (biological) stability, on the other hand, offers biological stability through bone regeneration and remodeling^[5].

Several studies have been published, suggesting the positive clinical and radiographic outcomes of immediately loaded implants that used for implant assisted overdenture and seem to be a viable alternative to conventional loading^[6].

Acemannan, an extract from the aloe vera gel, has been shown to enhance rat bone marrow stromal cell proliferation, vascular endothelial growth factor (VEGF), and alkaline phosphatase activity^[7]. Another study demonstrated higher bone mineralization with accelerated healing by the incorporation of an oral dosage of acemannan^[8]. There is a study that analyze the efficacy of acemannan on in vitro osteoblast cell attachment and differentiation and in vivo early stage bone formation and osseointegration in a rat distal femur model^[9].

In dentistry, *Aloe vera* is used in periodontal therapy, acute mouth lesions are improved by direct application of it on herpetic viral lesions, aphthous ulcers, canker sores, and cracks occurring at the corners of the lips^[10]. It can also be used around dental implants and in ill-fitting denture base to control any bacterial and fungal infection^[11]. Also, *Aloe vera* added to toothpaste due to its bleaching properties^[12]. Also, some researchers use the aloe vera sponge in the pulp therapy for primary molars and compare its antimicrobial effect with the another materials^[13].

In this study, we try to focus on the effect of aloe vera in stimulation of new bone around the implant that help in the osseointegration of the implant and increase the implant stability.

MATERIAL AND METHODS

This study was conducted as a clinical trial, it was carried out at prosthodontics Department, Faculty of Dentistry, Nahda University. This study was carried out on ten male patients aged from sixty to seventy years old, they were selected from patients attending outpatient clinic of prosthodontics department. Approval for this research was obtained from Faculty of Dentistry, Nahda University Research Ethics Committee. The purpose of the present study was explained to the patients and informed consents were obtained according to the guidelines on human research adopted by the Research Ethics Committee Faculty of Dentistry, Nahda University.

The study was carried out with 10 completely edentulous patients who were edentulous at least one year ago. Patients included in this study were evaluated by taking a full medical history as well as special laboratory investigations to ensure that all selected patients were free from any systemic diseases that might influence the osseointegration process. They had adequate maxillomandibular space. The excluded patients were those undertaking radiation therapy, who

were psychologically unstable, heavy smokers, alcoholic, and/or drug abusers, patients with poor oral hygiene. Clinical examination of oral and para-oral structures was made including visual and digital examination to evaluate the mucosa covering the edentulous ridge. Also, the width and the height of the mandibular residual ridge in the inter-foraminal region were roughly evaluated by palpating the ridge between the thumb and index fingers. The width should be not less than 6 mm and the height not less than 17 mm.

For patients who were eligible for the study, cone beam computed tomography (CBCT) scans were made with the mandibular denture clear duplicate to evaluate the potential implant sites prior to implant placement. Gutta percha radiopaque markers were incorporated into the duplicate before the scan to assess the proper implant site and the relevant anatomical structures of the mandible. The clear duplicate used as surgical guide during the surgical procedures.

Preparation of acemannan sponge

Aloe vera polysaccharide fraction: Fresh *Aloe vera* gel (100 g) was homogenized and centrifuges at 9×10^3 g for 10 min. The supernatant was dialyzed with molecular weight 8000 cut-off membrane against distilled water for 36 hours and the non-dialysate (1 g) was obtained as polysaccharides fraction after lyophilization, 0.4% acemannan solutions (w/v) were frozen at -80 C degree for 16 h and lyophilized overnight. Then the sponges are sterilized by gamma irradiation and tested for endotoxin contamination. The endotoxin level of the acemannan sponges are assessed using the Traditional Kinetic Limulus Amebocyte Lysate (LAL) assay kit (Lonza, Inc., Allendale, NJ, USA) following the manufacturer's instructions. The endotoxin level is measured using ELISA after mixing the sample with LAL reagent and comparing it to a standard curve. Endotoxin levels are 4.30 EU/mg sponge^[14]. Acemannan sponge, provided by Prof. Yagi A., Emeritus, Fukuyama University, Hiroshima, Japan.

Surgical procedures

Under aseptic conditions, the patient's head, neck, and body were covered with a sterile surgical gown. The circumoral skin was rubbed with betadine solution. Infiltration anesthesia was given to the patient by using ARTINIBSA 40mg/0.005 mg/ml solution for injection^[1], labially and lingually at the canine region.

The mandibular surgical template was firmly seated over the mandibular residual ridge (Figure 4) and the implant positions were marked using the positional cortical drill through the two channels of the template to perforate cortical bone through the mucosa in a flapless surgical procedure under profuse irrigation with normal saline 9%.

After removal of the template, the pilot drill was moved in a vertical up and down direction under profuse irrigation with normal saline 9% till depth of 14 mm. A paralleling pin was inserted in the first osteotomy site to ensure the parallelism during the drilling of the second site. Another paralleling pin was inserted in the second osteotomy site to ensure the parallelism (Figure 1). Sequential drills were used in the same manner to increase the diameter of the osteotomy site till the main drill (3.8 mm diameters) was used.

For the right side of the patient (Group I), the sterile fixture pack was opened, and the fixture was attached to the fixture mount and manually inserted into the osteotomy site and rotated clockwise until no longer rotated the implant (Figure 2). Then the fixture placement was completed with the ratchet until the implant top flushes with the alveolar bone surface.

For the left side (Group II), the prepared sterile aloe vera sponge (Figure 3) was inserted in the osteotomy site before the implant

fixture insertion. Then the complete placement of the implant fixture was done as in the right side.

After implant placement, the primary stability of the implants was evaluated. Implant stability was measured using resonance frequency analysis (RFA). The resonance frequencies were measured with the Osstell Monitor device^[2] and expressed with ISQ measurement scale (implant stability quotient).

Osstell device kit consists of Osstell instrument with large display, measurement probe and a main plug. Smart peg that attaches to the implant fixture while a measurement is being performed (Figure 4). It is easy to mount and need minimal space in the patient's mouth.

The manufacturer stated that the vibration of the magnetic post, which is excited by magnetic pulses from handheld computer, generates resonance frequencies, and the resulting RF value, in hertz, is converted automatically into implant stability quotient (ISQ). ISQ is a measurement scale ranges from 1 to 100 ISQ. The higher the ISQ value indicates high implant stability. For each implant four reading (buccal, lingual, mesial distal) are recorded to have the average value of ISQ^[15].

For implants the achieved the desired primary stability (Figure 5), the ball attachment was inserted in the fixture.

The prosthetic procedures

The metal housings were placed over their attachments and Block-out spacers were placed to block the undercut areas under the housing. A marking paste was placed to the intaglio surface of the overdenture and inserted into the mouth to mark areas into which the metal housings will be picked up. The marked areas were relieved by using acrylic bur and small vents are made in the polishing surface to

allow escape ways for the excess acrylic resin then the lower denture was tested intra-orally to verify sufficient clearance with maximum intercuspation.

The housing was connected intraorally using autopolymerized acrylic resin (Repair Material) through direct pick-up procedure. After complete polymerization, the mandibular denture was removed from the patient mouth and trimmed to remove the excess acrylic resin.

Occlusion and denture base adaptation were then checked and adjusted before dismissing the patient. Patients were instructed how

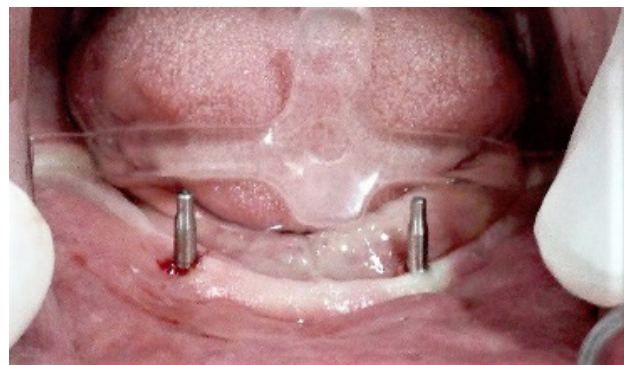


Figure 1 Paralleling pin during surgical procedure.

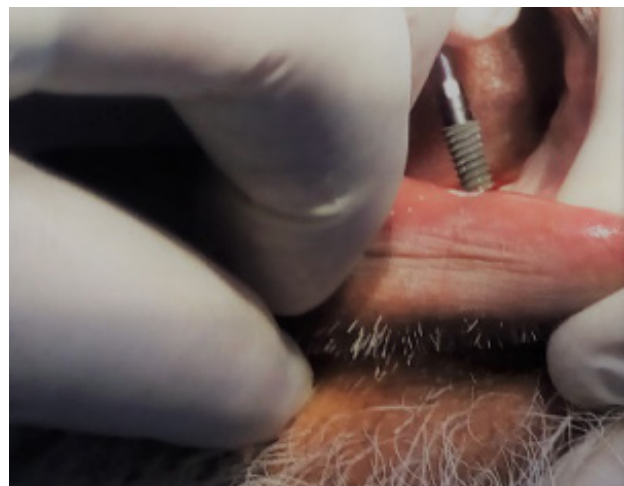

Figure 2 Implant placement.

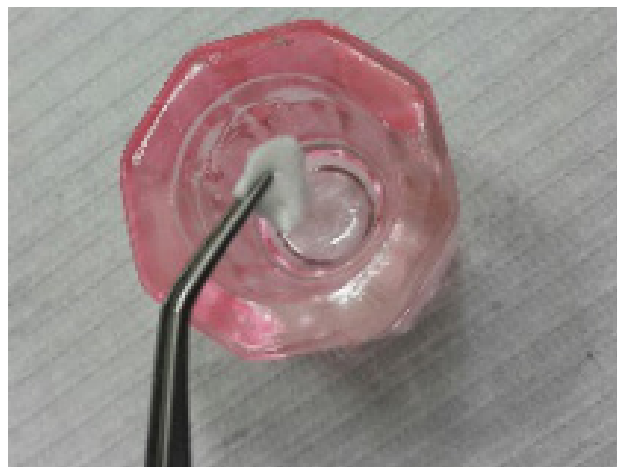

Figure 3 Aloe vera sponge in dappen dish.

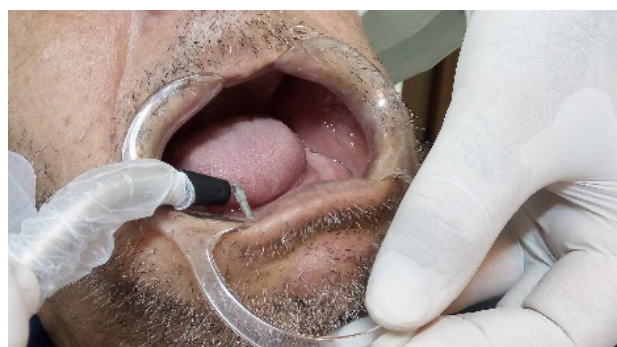

Figure 4 Smartpeg is connected to the fixture during measuring the implant stability.



Figure 5 Digital screen of osstell device reading the implant stability.

to insert and remove the prosthesis. The patients were informed about follow up visits to evaluate the implant stability at 6, 12 months by the same procedure at time of implant insertion. The ISQ records were collected and statistically analyzed applying suitable tests.

RESULTS

The following are the results of implant stability of group I (immediate loading implant without aloe vera gel) and group II (immediate loading implant with aloe vera gel). Data was collected, tabulated, and statistically analyzed by SPSS© 20 for windows. The data distribution of normality was done by using Kolmogorov - Smirnov test. The test showed normal distribution of data and independent t - test was used for comparison between groups while the comparison of ISQ level by time within each group was done by one Way ANOVA.

The four ISQ readings recorded for each implant at the two groups (buccal, lingual, mesial and distal surfaces) and the average readings were recorded. The mean ISQ values found for both the group I and group II are showed in Table 1.

ISQ readings around implants of both groups at baseline, the mean values of ISQ readings at group I was 60.1 with (SD) 8.01 and for group II was 62.1 with SD 7.54 (p value (0.572467).

Changes in ISQ readings around implants of both groups after 6 months of follow up period, the mean values of ISQ readings at group I was 68.8 with (SD) 5.98 and for group II was 70.6 with SD 7.01 (p value (0.572467). there is no significant difference with slight increase in the stability in group II.

Changes in ISQ value around implants of both groups after 12 months of follow up period, the mean values of ISQ values at group I was 78.8 with (SD) 5.24 and for group II was 79.8 with SD 4.37 (p value (0.495729). there is no significant difference slight increase in the ISQ values in group II.

Effect of time on implant stability quotient (ISQ)

Table 2 show the comparison between the ISQ values in each group during the follow up period. Although the ISQ value increase during the follow up period, the differences were statistically nonsignificant as P value was > 0.05.

DISCUSSION

The mandibular implant assisted overdenture is a treatment that has been proposed for edentulous patients as an alternative to removable or implant supported prosthesis. The improved retention and stability is an obvious advantage in comparison with conventional removable denture^[16].

The use of two implants to retain the denture significantly improve the prognosis of mandibular edentulism, some have considered a two implant assisted overdenture to be the standard of care for mandibular edentulism^[17].

The prognosis of any implant-assisted prosthesis depends primarily on successful osseointegration of the implants. Accordingly, strict measures were followed in this study to avoid potential factors that might increase the risk of implant failures^[18].

The criteria of patient's selection were carefully considered to ensure the standardization of the outcoming results. The selected patients had the same range of age, too old patients were excluded, as they have potentially longer healing time, more systematic health problems and have difficulty to adapt to new dental prosthesis, as well as less ability to maintain good oral hygiene which may lead to delayed osseointegration^[19].

Table 1 ISO values at time of insertion and at the follow up periods.

	Baseline	6 months	12months
G I	60.1 ± 8.01	68.8 ± 5.98	78.8 ± 5.24
G II	62.1 ± 7.54	70.6 ± 7.01	79.8 ± 4.37
P(T<=t) (two-tail)	0.572	0.496	0.535
t Critical (two-tail)	2.048	2.048	2.048
Significance	N.S	N.S	N.S

N.S: none significant.

Table 2 ISQ values for each group at the follow up periods.

Osstell evaluation	Baseline	After 6 months	After 12months	p-value	Significance
G I	60.1 ± 8.01	68.8 ± 5.98	78.8 ± 5.24	0.245	N.S
G II	62.1 ± 7.54	70.6 ± 7.01	79.8 ± 4.37	0.216	N.S

Only male patients were chosen to avoid any bone changes which may accompany the postmenopausal period in female^[20].

Flapless protocol for implant placement was chosen for this study to preserve maximum amount of blood supply to the bone, because reflection of flap will compromise part of blood supply to alveolar bone from the soft tissue^[21]. It was found that both the amount of osseointegration and bone height around the implants were significantly greater than in implants placed with flapless technique^[22]. Also, excellent peri-implant mucosal health was found after flapless implant surgery, as confirmed by low gingival and bleeding index scores.

The implants were immediately loaded in this study because it was reported that immediate loading of implants in anterior mandible shorten the treatment time and show comparable clinical success with the delay loading approach^[23], since the high degree of primary stability at implant insertion is considered to be a key prerequisite for obtaining a successful osseointegration as shown in a systematic review^[24].

The chair side "pick up" of the matrices was done in this study to allow the attachment to be in a passive loaded environment, to ensure complete seating of the denture on the underlying tissues, to avoid potential distortions associated with the clinical and laboratory procedures during overdenture fabrication and to ensure acceptable fit of the overdenture. However, if this step is not correctly performed; it can negatively influence overdenture fit or contribute to the dislodgement of the matrix from the overdenture^[25].

OSSTELL ISQ device was used as it is highly reliable, easy utilized, and measurements are repeatable and reproducible^[26].

The results of this study revealed an increase in the ISQ value of both groups at the end of the follow up period; this is in agreement with several investigations which approved that; the ISQ value of a stable osseointegrated implants increases with time, suggesting an increase in the bone-implant contact area^[27,28]. Although Aloe vera is a promising material in the dental field because its biological effect, comparing the current findings to literature's data directly was not possible because of lack of similar studies.

The increase in ISQ can be attributed to the nature of bone, in which bone remodeling whether it is bone deposition or bone resorption, is induced by bone stimulations. This supported by Koyama et al, in which it was stated that when functional loading has been initiated, the bony structures adapt to the load by improving the quality of the bone; replacing preexisting, necrotic and/or initially formed more primitive woven bone with mature, viable lamellar bone^[29].

CONCLUSIONS

When the two groups compared together during the same period of follow up, numerically implant stability was higher in group II than group I but this difference was statistically non-significant. These results can be explained by the biological effect of acemannan as it may increase bone formation by increasing cell proliferation, osteoblast differentiation, growth factor and extracellular matrix secretion, and mineralization^[8]. Moreover, the anti-inflammatory and immunomodulatory effects of acemannan have been reported. This polysaccharide will facilitate the inflammatory reaction through macrophage activation and the release of cytokines and growth factors. Interleukins, tumor necrosis factor alpha, transforming growth factor beta, platelet-derived growth factor, endothelial growth factor, bone morphogenetic proteins, and vascular endothelial growth factor have been associated with bone repair and regeneration. With the limitation of this study, it is possible to conclude that acemannan sponge could positively affect the osseointegration between implant and bone and increase the implant stability in immediate loaded implant assisted overdenture.

ACKNOWLEDGMENT

The authors express deep appreciation to Prof. Amal Kabbash, who has great effort to give us the opportunity to use the Acemannan in this study.

REFERENCE

- Jainkittivong A, Aneksuk V, Langlais RP. Oral mucosal lesions in denture wearers. *Gerodontology*. 2010; **27(1)**: 26-32. [DOI: 10.1111/j.1741-2358.2009.00289.x]
- Allen F, McMillan A. Food selection and perceptions of chewing ability following provision of implant and conventional prostheses in complete denture wearers. *Clin Oral Implants Res* [Internet]. 2002; **13(3)**: 320-6. [DOI: 10.1034/j.1600-0501.2002.130313.x]
- Menezes HHM, Naves MM, Costa HL, Barbosa TP, Ferreira JA, Magalhães D, et al. Effect of surgical installation of dental implants on surface topography and its influence on osteoblast proliferation. *Int J Dent*. 2018; 2018. [DOI: 10.1155/2018/4089274]
- Buser D, Broggin N, Wieland M, Schenk RK, Denzer AJ, Cochran DL, et al. Enhanced bone apposition to a chemically modified SLA titanium surface. *J Dent Res*. 2004; **83(7)**: 529-33. [DOI: 10.1177/154405910408300704]
- Tseng C-C, Pang I-C, Wen M-J, Huang K-C, Chang J-C. Clinical Effectiveness of International Team for Oral Implantology Dental Implant Treatment in Taiwan: A Seven-Year Longitudinal Study. *Implant Dent* [Internet]. 2009; **18(1)**. [DOI: 10.1097/ID.0b013e31818c591d]
- Zygiannis K, Aartman I, Parsa A, Tahmaseb A, Wismeijer D. Implant Mandibular Overdentures Retained by Immediately Loaded Implants: A 1-Year Randomized Trial Comparing the Clinical and Radiographic Outcomes Between Mini Dental Implants and Standard-Sized Implants. *Int J Oral Maxillofac Implants*. 2017; **32(6)**. [DOI: 10.11607/jomi.5981]
- Godoy DJD, Chokboribal J, Pauwels R, Banlunara W, Sangvanich P, Jaroenporn S, et al. Acemannan increased bone surface, bone volume, and bone density in a calvarial defect model in skeletally-mature rats. *J Dent Sci*. 2018; **13(4)**: 334-41. [DOI: 10.1016/j.jds.2018.06.004]
- Chantarawatit P, Sangvanich P, Banlunara W, Soontornvipart K, Thunyakitpisal P. Acemannan sponges stimulate alveolar bone, cementum and periodontal ligament regeneration in a canine class II furcation defect model. *J Periodontal Res*. 2014; **49(2)**. [DOI: 10.1111/jre.12090]
- Banerjee D, Bose S. Effects of aloe vera gel extract in doped hydroxyapatite-coated titanium implants on in vivo and in vitro biological properties. *ACS Appl Bio Mater*. 2019; **2(8)**: 3194-202. [DOI: 10.1021/acsabm.9b00077]
- Tuna D, Ölmez A. Clinical long-term evaluation of MTA as a direct pulp capping material in primary teeth. *Int Endod J*. 2008; **41(4)**. [DOI: 10.1111/j.1365-2591.2007.01339.x]
- Mangaiyarkarasi SP, Manigandan T, Elumalai M, Cholan PK, Kaur RP. Benefits of Aloe vera in dentistry. *J Pharm Bioallied Sci*. 2015 Apr; **7(Suppl 1)**: S255-9. [DOI: 10.4103/0975-7406.155943].
- Rutherford RB, Wahle J, Tucker M, Rueger D, Charette M. Induction of reparative dentine formation in monkeys by recombinant human osteogenic Protein-1. *Arch Oral Biol*. 1993; **38(7)**. [DOI: 10.1016/0003-9969(93)90121-2]
- Gonna S, Ghouraba RF, Eissa R, Kabbash A, Yagi A, Metwally NM. Clinical, Radiographical and Antibacterial Evaluation of Acemannan Sponge and Tri-Mix Used in Treatment of Non Vital Primary Molars. *Journal of Gastroenterology and Hepatology Research*. 2021 Oct 21; **10(5)**: 3577-86. [DOI: 10.17554/j.issn.2224-3992.2021.10.1028]
- Jittapiromsak N, Sahawat D, Banlunara W, Sangvanich P, Thunyakitpisal P. Acemannan, an extracted product from Aloe vera, stimulates dental pulp cell proliferation, differentiation, mineralization, and dentin formation. *Tissue Eng Part A*. 2010; **16(6)**: 1997-2006. [DOI: 10.1089/ten.TEA.2009.0593]
- Becker W, Hujuel P, Becker BE. Resonance frequency analysis: Comparing two clinical instruments. *Clin Implant Dent Relat Res*. 2018; **20(3)**: 308-12. [DOI: 10.1111/cid.12598]
- Kapur KK, Soman SD. Masticatory performance and efficiency in denture wearers. *J Prosthet Dent*. 2006; **95(6)**: 407-11. [DOI: 10.1016/j.prosdent.2006.03.012]
- Thomason JM, Feine J, Exley C, Moynihan P, Müller F, Naert I, Ellis JS, Barclay C, Butterworth C, Scott B, Lynch C. Mandibular two implant-supported overdentures as the first choice standard of care for edentulous patients-the York Consensus Statement. *British dental journal*. 2009 Aug; **207(4)**: 185-6. [DOI: 10.1038/sj.bdj.2009.728]
- Wood MR, Vermilyea SG. A review of selected dental literature on evidence-based treatment planning for dental implants: Report of the Committee on Research in Fixed Prosthodontics of the Academy of Fixed Prosthodontics. *Journal of Prosthetic Dentistry*. 2004.92. [DOI: 10.1016/j.prosdent.2004.08.003]
- Meijer HJA, Batenburg RHK, Raghoobar GM. Influence of patient age on the success rate of dental implants supporting an overdenture in an edentulous mandible: a 3-year prospective study. *Int J Oral Maxillofac Implants*. 2001; **16(4)**. [PMID: 11515999]
- Misch CE. Contemporary implant dentistry-E-Book. St Louis Elsevier Heal Sci. 2007;
- Al-Juboory MJ, Jassan A. Comparison of flapless and conventional flap and the effect on crestal bone resorption during a 12-week healing period. *Dent Implantol Update*. 2012; **23(2)**: 9-16. [PMID: 22338850]
- Jeong S-M, Choi B-H, Li J, Kim H-S, Ko C-Y, Jung J-H, et al. Flapless implant surgery: an experimental study. *Oral Surgery, Oral Med Oral Pathol Oral Radiol Endodontology*. 2007; **104(1)**: 24-8. [DOI: 10.1016/j.tripleo.2006.11.034]
- Attard NJ, Zarb GA. Immediate and early implant loading protocols: a literature review of clinical studies. *J Prosthet Dent*. 2005; **94(3)**: 242-58. [DOI: 10.1016/j.prosdent.2005.04.015]
- Xu L, Wang X, Zhang Q, Yang W, Zhu W, Zhao K. Immediate versus early loading of flapless placed dental implants: a systematic review. *J Prosthet Dent*. 2014; **112(4)**: 760-9. [DOI: 10.1016/j.prosdent.2014.01.026]
- Shor A, Goto Y, Shor K. Mandibular two-implant-retained overdenture: prosthetic design and fabrication protocol. *Compend Contin Educ Dent* (Jamesburg, NJ 1995). 2007; **28(2)**: 80-8.

[PMID: 17319179]

26. Herrero-Climent M, Santos-García R, Jaramillo-Santos R, Romero-Ruiz MM, Fernández-Palacin A, Lázaro-Calvo P, et al. Assessment of Osstell ISQ's reliability for implant stability measurement: A cross-sectional clinical study. *Med Oral Patol Oral Cir Bucal*. 2013; **18**(6): e877 [DOI: 104317/medoral.19120]
27. Karakoca-Nemli S, Aydin C, Yilmaz H, Sarisoy Ş. Stability measurements of craniofacial implants by means of resonance frequency analysis: 1-year clinical pilot study. *Int J Oral Maxillofac Implants*. 2012; **27**(1). [PMID: 22299096]
28. Rasmusson L, Kahnberg K, Tan A. Effects of implant design and surface on bone regeneration and implant stability: an experimental study in the dog mandible. *Clin Implant Dent Relat Res*. 2001; **3**(1): 2-8. [DOI: 10.1111/j.1708-8208.2001.tb00123.x]
29. Koyama S, Sasaki H, Yokoyama M, Yamamoto M, Sato N, Reisberg D, et al. Changes in bone metabolism around osseointegrated implants under loading. *Implant Dent Most Promis Discip Dent Intech, Croat*. 2011; 203-18.