

Penetration of Single-dose Levofloxacin into Intestinal Tissue

Takashi Nakajima, Yoko Kaji, Makoto Miyawaki, Nobuyuki Obinata, Kousuke Hosoya, Yuichi Kinoshita, Yoshichika Oishi, Yoshihito Yoshida, Ryo Morita, Ryuichi Abiko, Yohei Yanagida, Nobuyoshi Miyajima, Akiko Isogai, Takahiro Sasaki

Takashi Nakajima, Yoko Kaji, Makoto Miyawaki, Nobuyuki Obinata, Kousuke Hosoya, Yuichi Kinoshita, Yoshichika Oishi, Yoshihito Yoshida, Ryo Morita, Ryuichi Abiko, Yohei Yanagida, Nobuyoshi Miyajima, Akiko Isogai, Takahiro Sasaki, Department of Gastroenterology, St. Marianna University School of Medicine Toyoko Hospital, 3-432 Kosugi-cho, Nakahara-ku, Kawasaki-city, Kanagawa, 211-0063, Japan

Correspondence to: Takashi Nakajima, MD, PhD, Department of Gastroenterology, St. Marianna University School of Medicine Toyoko Hospital, 3-432 Kosugi-cho, Nakahara-ku, Kawasaki-city, Kanagawa, 211-0063, Japan. nakajima@marianna-u.ac.jp

Telephone: +081-44-722-2121 Fax: +081-44-711-3316

Received: October 10, 2012 Revised: November 22, 2012

Accepted: November 25, 2012

Published online: February 21, 2013

ABSTRACT

AIM: There is a trend toward severer peritonitis after perforation due to endoscopic submucosal dissection; however, the treatment regimen has not been fully established. This study investigated the indication of single-dose levofloxacin and its penetration ratio into the intestinal tissue.

METHODS: This retrospective study included 13 patients receiving a single 500 mg dose of levofloxacin oral administration (p.o.) once daily (q.d.) for 2 days prior to endoscopic submucosal dissection and at 3 hours before endoscopic submucosal dissection. Levofloxacin concentrations in plasma and in intestinal tissue were measured from blood samples immediately before endoscopic submucosal dissection and normal intestinal tissue in the resected intestinal specimens. The ratio of levofloxacin concentration in intestinal tissue against levofloxacin concentration in plasma was calculated for the assessment of levofloxacin penetration.

RESULTS: The mean drug concentrations in plasma and in intestinal tissue were 8.069 ± 2.724 $\mu\text{g/mL}$ at 262.8 ± 80.2 minutes and 9.181 ± 4.638 $\mu\text{g/g}$ at 338.2 ± 88.0 minutes. The intestinal tissue / plasma ratio was 1.173 ± 0.465 .

CONCLUSION: The penetration of a single 500 mg dose of levofloxacin p.o. q.d. to the intestinal tissue was relatively favorable. Since levofloxacin has a broad spectrum of activity, a single 500 mg dose of levofloxacin administration prior to endoscopic submucosal dissection might be effective in the prevention of penetration

peritonitis and the treatment of infectious enteritis.

© 2013 ACT. All rights reserved.

Key words: Levofloxacin; Peritonitis; Endoscopic submucosal dissection

Nakajima T, Kaji Y, Miyawaki M, Obinata N, Hosoya K, Kinoshita Y, Oishi Y, Yoshida Y, Morita R, Abiko R, Yanagida Y, Miyajima N, Isogai A, Sasaki T. Penetration of Single-dose Levofloxacin into Intestinal Tissue. *Journal of Gastroenterology and Hepatology Research* 2013; 2(2): 399-402 Available from: URL: <http://www.ghrnet.org/index./joghr/>

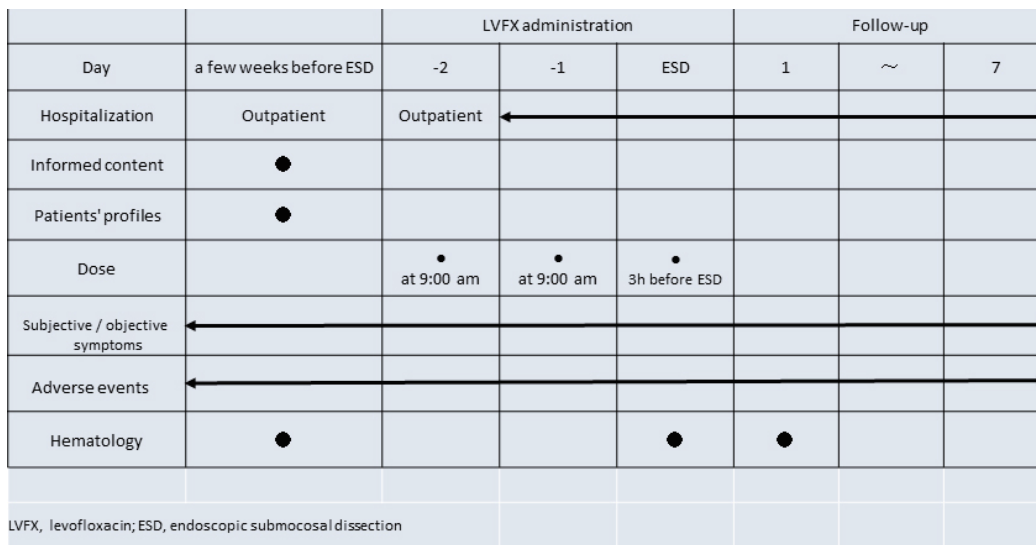
INTRODUCTION

The incidence of perforation due to endoscopic submucosal dissection (ESD) accounts for approximately 3.3%^[1], and ESD triggers critical peritonitis in some cases because of fluid leak. Preoperative and postoperative antibiotic therapy is vitally important for preventing peritonitis. At the Gastroenterology Center in the St. Marianna University School of Medicine Toyoko Hospital, aminoglycoside antibiotics, kanamycin sulfate capsules, would be administered to patients undergoing ESD because of its sustained high concentrations in the intestines. However, these patients had to take kanamycin 4 times a day (t.i.d.), resulting in relatively low drug compliance. Meanwhile, new quinolone antibiotics levofloxacin (LVFX) has a broad spectrum of activity. The dosage regimen of LVFX in Japan has been changed from 100 mg t.i.d. to a single 500 mg dose once daily (q.d.) since 2011 after the pharmacokinetic / pharmacodynamic theory was approved, which leads to better adherence to medications. Nowadays, patients in our hospital receive a single 500 mg dose of LVFX oral administration (p.o.) q.d. 2 days prior to colon ESD and colon polyp dissection. Particularly, antibiotic actions against pathogens and drug concentrations in the intestinal tissue play a crucial role in preventing infectious disease. One earlier study has reported the relatively high fecal drug concentration in the fecal microflora^[2]; however, sufficient data on drug concentrations in the intestinal tissue have not been presented yet. Here, the present study investigated and evaluated the penetration of LVFX into the intestinal tissue and drug concentrations in plasma and in intestinal tissue in patients who received a single 500 mg dose of LVFX p.o. q.d. before and after endoscopic resection of colorectal tumor.

Table 1 Patients' profiles.

P	G	Age	H(cm)	W(kg)	Complications	Duration (min)	Size (mm)	Pathology
1	M	52	170	73.0	None	96	30	Intramucosal cancer
2	M	68	164	77.4	Hypertension, alcoholic cirrhosis	94	35	Intramucosal cancer
3	M	30	175	60.0	None	45	15	Carcinoid
4	M	69	167	66.0	Hypertension, diabetes mellitus, hyperlipidemia	64	18	Intramucosal cancer
5	F	75	145	53.5	Hypertension, asthma, neurosis, depression, osteoporosis	162	50	Massively invasive submucosal cancer
6	F	82	138	34.0	Osteoporosis, constipation	103	40	Slightly invasive submucosal cancer
7	F	82	144.5	51.5	Hypertension, diabetes mellitus, chronic kidney disease, dry mouth	93	15	Slightly invasive submucosal cancer
8	M	72	158	60.0	Hypertension, diabetes mellitus, diabetic retinopathy	93	18	Intramucosal cancer
9	F	76	145	67.2	Hypertension, cardiomyopathy, osteoporosis, chronic gastritis	99	35	Adenoma
10	M	85	156	54.0	Hypothyroidism, iron-deficiency anemia, aortic dissection, asymptomatic cerebral infarction, obstructive ventilatory impairment	67	20	Adenoma
11	F	77	150	50.5	Osteoporosis, gallbladder polyp, hypertension, knee pain	49	18	Intramucosal cancer
12	M	67	164	53.0	Hyperlipidemia, diabetes mellitus	91	20	Adenoma
13	M	69	167	66.0	Hypertension, diabetes mellitus, hyperlipidemia	52	15	Adenoma

P: patients; G: gender; M: male; F: female; H: height; W: weight; Duration: surgical duration; Size: tumor size.



METHODS

This study included 13 patients who received endoscopic colorectal tumor dissection between August 2010 and November 2010. The dissections of all 13 tumors were performed by the same endoscopist. Patients with severe renal dysfunction, medical history of allergic disease, critical cardiac disease and those who had hypersensitivity to quinolone were excluded. This study was performed in accordance with the ethical principles set forth in the Declaration of Helsinki. The Ethics Committee of St. Marianna University School of Medicine also approved the study protocol (authorization number 1722). Written informed consent was obtained from all study patients prior to enrollment.

According to the study schedule (Figure 1), a single 500 mg dose of LVFX p.o. q.d. was administered to the study patients in the morning for 2 days prior to ESD and at 3 hours before ESD. LVFX concentrations in plasma and in intestinal tissue were measured from blood samples and normal intestinal tissue in the resected specimens. Blood samples were collected immediately before ESD, which was separated to obtain plasma from the blood cells. Intestinal tissue was stored in the freezer at -20°C until analysis. Drug concentration measurement was performed at Mitsubishi Chemical Medience Co. Ltd., (Tokyo, Japan). LVFX concentration in plasma was measured according to the high-pressure liquid chromatography method^[3];

LVFX concentration in intestinal tissue was measured according to the lipid chromatography – tandem mass spectrometry method^[4]. To evaluate drug concentration in intestinal tissue, the ratio of LVFX concentration in intestinal tissue against that in plasma (mean±SD) was calculated.

Investigated items and the study schedule are shown in figure 1. Patients' profiles included gender, age, height, weight and complications, tumor size and pathology (Table 1). Hematological examinations were performed 3 times, on the day when the patients were determined to undergo ESD, immediately before ESD and one day after ESD. Subjective and objective symptoms and adverse events were observed from 2 days before ESD until 7 days after ESD.

Drug concentration in intestinal tissue was measured at 3 hours after 3-day LVFX administration. The prevention effect of LVFX was determined by the presence / absence of perforation peritonitis during ESD. Adverse events were determined when patients had adverse changes in their health while receiving LVFX. Of these, side effects were determined when LVFX administration was closely associated with the events.

RESULTS

All study patients complied with the study schedule (Figure 1). This study included 8 men and 5 women; the mean age was 69.5±14.0

Table 2 Levofloxacin concentrations in plasma and intestinal tissue.

Patients	Time duration from LVFX administration to blood collection(min)	LVFX concentration in plasma ($\mu\text{g}/\text{mL}$)	Time duration from LVFX administration to intestinal tissue resection (min)	LVFX concentration in intestinal tissue ($\mu\text{g}/\text{g}$)	The intestinal tissue / plasma ratios
1	415	4.159	487	5.702	1.371
2	350	7.626	419	14.12	1.852
3	215	5.513	251	4.442	0.806
4	140	6.750	171	6.520	0.966
5	230	9.454	427	19.74	2.088
6	285	11.995	370	11.6	0.967
7	290	11.335	374	7.282	0.642
8	295	7.434	366	4.664	0.627
9	250	7.703	345	7.774	1.009
10	135	11.360	219	16.610	1.462
11	260	11.596	308	7.444	0.642
12	188	5.941	259	6.613	1.113
13	363	4.027	401	6.841	1.699

LVFX: levofloxacin.

years, the mean height was 157 ± 11.3 cm, the mean weight was 58.9 ± 10.9 kg, and the mean procedure time (mean endoscope insertion to removal time) was 85.3 ± 29.8 min. Of the study patients, 11 patients had complications, including 8 patients with hypertension, 5 patients with diabetes mellitus, 4 patients with osteoporosis and 3 patients with hyperlipidemia. The mean size of tumor was 25.3 ± 10.9 mm. Of the 13 dissected tumor specimens, 3 specimens were pathologically invasive submucosal cancers (massively invasive submucosal cancer, $n=1$; slightly invasive submucosal cancer, $n=2$), 5 were intramucosal cancer, 1 was carcinoid, and 4 were adenomas (Table 1). The patient with massively invasive submucosal cancer received another surgery for lymph node removal later.

Adverse reactions of LVFX include gastrointestinal disorders (nausea and diarrhea), nervous system disorders (headache and dizziness), blood system disorders (leucopenia), psychiatric disorders (insomnia), and liver dysfunction. Of the study patients, none had those reactions during/after administration. No patients had perforation peritonitis during ESD either.

Table 2 shows LVFX concentrations in plasma and in intestinal tissue. LVFX concentrations were measured at 262.8 ± 80.2 (135-415) minutes in plasma and at 338.2 ± 88.0 (171-487) minutes in intestinal tissue after blood and tissue collections. LVFX concentrations in plasma and in intestinal tissue were 8.069 ± 2.724 (4.027-11.995) $\mu\text{g}/\text{mL}$ and 9.181 ± 4.638 (4.442-19.740) $\mu\text{g}/\text{g}$. The ratio of LVFX concentration in intestinal tissue against that in plasma was 1.173 ± 0.465 (0.627-2.088).

DISCUSSION

Nowadays, ESD is widely used for the early detection of colon cancer. ESD has developed from endoscopic resection and allows en bloc resection even in a large tumor. ESD does not involve open surgery; therefore, it reduces the risk of surgical complications and provides faster recovery and earlier discharge from hospital. When perforation during ESD occurs, peritonitis becomes often critical. In our hospital, patients receive kanamycin or LVFX prior to ESD, although, the effective use of antibiotics for preventing infectious complications subsequent to ESD has not been established. Ishikawa *et al.*^[5] conducted a study on patients with polypectomy and/or hot-biopsy of the colon and/or rectum. Their study patients were randomly divided into two groups; one received antibiotics (oral kanamycin and intravenous clavulanic acid-ticarcillin) and the other not. No patients in the both groups had fever or stomach pain; however, the increases in white blood cells and neutrophil counts were significantly inhibited in the patients treated with antibiotics. In our hospital, the use of a single 500 mg dose of LVFX p.o. q.d. has been adopted because of favorable drug

compliance. In addition, LVFX, new quinolone antibiotics, has not only a broad spectrum of activity but also sufficient drug concentrations in the targeted area, suggesting that LVFX should have preventive effects against infectious diseases, such as perforation peritonitis. One study reported the relative permeability in the fecal microflora at 48 hours after single-dose 500 mg LVFX administration^[2]. Other studies also demonstrated maximum LVFX concentrations in blood at 1 to 2 hours^[6] and in gallbladder tissue at 3 to 4 hours after a single 500 mg dose of LVFX administration^[7]. Accordingly, we decided to administer LVFX to our patients at 3 hours before ESD. In the present study, the drug concentration in intestinal tissue was similar to that in plasma, resulting in favorable clinical response.

To date, many studies have reported clinical response of LVFX to each tissue^[7-12]. One study demonstrated that the mean level of LVFX at 3 to 4 hours after administration in the prostatic tissue was 6.442 ± 1.794 $\mu\text{g}/\text{g}$ and the tissue / plasma ratio was 1.162 ± 0.256 ^[8]. Another study also reported that the tissue / plasma ratio was 1.85 in the gallbladder tissue (17.93 mg/kg)^[9]. When LVFX at the dose of 100 mg or 200 mg was given, the tissue / plasma ratios were reported 1.63 ± 0.13 in testicular tissue^[10], 1.19 ± 0.13 in epididymis tissue^[10], 2.17 in lung tissue^[11] and 1.78-2.11 in palatine tonsils^[12], which was similar to the LVFX concentration in intestinal tissue in the present study.

The result of this study demonstrated a single 500 mg dose of LVFX p.o. q.d. contributed the favorable clinical response in the blood and intestinal tissue. The incidence of perforation during ESD causes the leakage of intestinal contents into the abdominal cavity, leading to the onset of peritonitis. When it occurs, additional administration of antibiotics is required, although, the preoperative administration of LVFX also provides the favorable clinical response in the blood and feces^[2]. Therefore, we presumed the preoperative administration of LVFX would decrease bacteria causing infection in the intestines and prevent the onset of perforation peritonitis. The result of this study demonstrated that a single 500 mg dose of LVFX p.o. q.d. might be useful in the treatment of infectious enteritis and penetrate well into the intentional tissues because of its broad spectrum of activity. Since this study included small study population, further studies with a larger study population are thus required for the establishment of drug therapy using a single dose of LVFX p.o. for preventing infectious enteritis after ESD.

ACKNOWLEDGMENTS

Dr. Takashi Nakajima has received a research grant from Daiichi Sankyo Co., Ltd. for the measurements of levofloxacin concentrations in plasma and intestinal tissue.

REFERENCES

- 1 Oka S, Tanaka S, Kanao H, Ishikawa H, Watanabe T, Igarashi M, Saito Y, Ikematsu H, Kobayashi K, Inoue Y, Yahagi N, Tsuda S, Simizu S, Iishi H, Yamano H, Kudo SE, Tsuruta O, Tamura S, Saito Y, Cho E, Fujii T, Sano Y, Nakamura H, Sugihara K, Muto T. Current status in the occurrence of postoperative bleeding, perforation and residual/local recurrence during colonoscopic treatment in Japan. *Dig Endosc* 2010; **22**: 376-380
- 2 Murata M, Irimagiri S, Nitta Y, Sagara Y, Yamaguchi T. Clinical trial of levofloxacin (DR-3355) and fecal drug concentration and change in the fecal microflora in infectious enteritis. *Chemotherapy* 1992; **40**: 170-187
- 3 Kees F, Naber KG, Schumacher H, Grobecker H. Penetration of fleroxacin into prostatic secretion and prostatic adenoma tissue. *Chemotherapy* 1988; **34**: 437-443
- 4 Covey TR, Lee ED, Henion JD. High-speed liquid chromatography/tandem mass spectrometry for the determination of drugs in biological samples. *Anal Chem* 1986; **58**: 2453-2460
- 5 Ishikawa H, Akedo I, Minami T, Shinomura Y, Tojo H, Otani T. Prevention of infectious complications subsequent to endoscopic treatment of the colon and rectum. *J Infect Chemother* 1999; **5**: 86-90
- 6 Shiba K, Fukase H, Sugiyama A. Phase I study of levofloxacin in healthy and elderly volunteers. *Jpn J Chemother* 2009; **57** (Supple2): 1-11
- 7 Hukagawa H, Noga K. A study on the concentrations of levofloxacin in the gallbladder tissue and bile of patients. *Jpn J Antibiot* 1992; **45**: 253-257
- 8 Yasuda M, Arakawa S, Ishihara S, Ito S, Hikosaka K, Minayoshi K, Hara S, Ito K, Kawai S, Nishimura H, Sakamoto S, Takahashi K, Fujisawa M, Deguchi T, Matsumoto T. Clinical response of levofloxacin 500mg qd to urogenital infection (in compliance with the new guidelines) and examination of penetration into the prostatic tissues. *Jpn J Chemother* 2011; **59**: 585-596
- 9 Swoboda S, Oberdorfer K, Klee F, Hoppe-Tichy T, von Baum H, Geiss HK. Tissue and serum concentrations of levofloxacin 500 mg administered intravenously or orally for antibiotic prophylaxis in biliary surgery. *J Antimicrob Chemother* 2003; **51**: 459-462
- 10 Saito I, Suzuki A, Saiko Y, Yokozawa M, Ono K, Miyata K, Miyamura R, Hamaya O, Kaneko K, Yamamoto T. Acute nongonococcal epididymitis--pharmacological and therapeutic aspects of levofloxacin. *Hinyokika Kyo* 1992; **38**: 623-628
- 11 Fujita A, Miya T, Tanaka R, Hirayama S, Isaka H, Ono Y, Koshiishi Y, Goya T. Levofloxacin concentrations in serum, sputum and lung tissue: evaluation of its efficacy according to breakpoint. *Jpn J Antibiot* 1999; **52**: 661-666
- 12 Baba S, Ito H, Yanai O, Shimada J, Miyake H. Study on the penetration of levofloxacin (DR-3355) into the otorhinolaryngeal tissues and discharges in patients. *Chemotherapy* 1992; **40**(Suppl 3): 326-333

Peer reviewer: Nasser hamed Mousa, Associate Professor, Tropical Medicine and Hepatology, Mansoura University, Mansoura City, 35516/20, Egypt.