

Adenocarcinoma of the Third Portion of the Duodenum with an Acute Cholecystitis

Hiromi Ono¹, MD; Hitoshi Yokoyama², MD, PhD; Haruyuki Yoshida², MD; Hiraku Fukushima², MD, PhD; Masato Kawakami², MD; Mikio Okamura³, MD; Takanori Aoki³, MD; Naoki Asakage³, MD; Yasushi Danjo⁴, MD, PhD; Kimimoto Nagashima⁵, MD; Hideyuki Hayashi⁶, MD, PhD; Hiroshi Nishihara⁶, MD, PhD; Yuichi Shimizu⁷, MD, PhD; Tsuyoshi Shimamura⁸, MD, PhD; Mitsuo Kusano⁹, MD, PhD

1 Department of Internal Medicine, Veritas Hospital, 2-23, 1-Chome, Shinden, Kawanishi, Hyogo 666-0125, Japan;

2 Department of Internal Medicine, Seiwa Memorial Hospital, 1-1, 1-Jo, 5-Chome, Kotoni, Nishi-ku, Sapporo, Hokkaido 063-0811, Japan;

3 Department of Surgery, Seiwa Memorial Hospital, 1-1, 1-Jo, 5-Chome, Kotoni, Nishi-ku, Sapporo, Hokkaido 063-0811, Japan;

4 Department of Surgery, Heiwa Hospital, 2-1, 2-Jo, 11-Chome, Heiwa, Nishi-ku, Sapporo, Hokkaido 063-0022, Japan;

5 Department of Anesthesiology, Shin-Sapporo Orthopedic Hospital, 2-32, 2-Chome, Atsubetsuminami, Atsubetsu-ku, Sapporo, Hokkaido 004-0022, Japan;

6 Genomics Unit, Keio Cancer Center, Keio University School of Medicine, 35 Shinanomachi, Shinjuku-ku, Tokyo 160-8582, Japan;

7 Division of Endoscopy, Hokkaido University Hospital, Kita 14, Nishi 5, Kita-ku, Sapporo, Hokkaido 060-8648, Japan;

8 Division of Organ Transplantation, Central Clinical Facilities, Hokkaido University Hospital, Kita 14, Nishi 5, Kita-ku, Sapporo, Hokkaido 060-8648, Japan;

9 Division of Internal Medicine, Hokkaido Social Welfare Corporation Yoichi Hospital, 19-1-1, Kurokawa-cho, Yoichi, Hokkaido 046-0003, Japan.

Conflict-of-interest statement: The authors declare that there is no conflict of interest regarding the publication of this paper.

Open-Access: This article is an open-access article which was selected by an in-house editor and fully peer-reviewed by external reviewers. It is distributed in accordance with the Creative Commons Attribution Non Commercial (CC BY-NC 4.0) license, which permits others to distribute, remix, adapt, build upon this work non-commercially, and license their derivative works on different terms, provided the original work is properly cited and the use is non-commercial. See: <http://creativecommons.org/licenses/by-nc/4.0/>

Correspondence to: Hiromi Ono, Department of Internal Medicine, Veritas Hospital, 2-23, 1-Chome, Shinden, Kawanishi, Hyogo 666-0125, Japan.

Email: kupz85728@zeus.eonet.ne.jp

Telephone: +81-72-793-7890

Received: November 21, 2020

Revised: December 5, 2020

Accepted: December 7, 2020

Published online: February 21, 2021

ABSTRACT

Primary adenocarcinoma of the third portion of the duodenum is rare. Therefore, few reports have investigated the diagnosis and treatment of this malignancy. In October 2012, a 52-year-old Japanese female was referred to our hospital complaining of epigastric pain due to acute cholecystitis. Subsequent esophagogastroduodenoscopy (EGD) revealed a depressed-type duodenal tumor 15mm in size on the third portion, while abdominal ultrasound and computed tomography scan revealed cholecystitis with a gallstone. Thereafter, partial duodenectomy and cholecystectomy was performed, with histological examination showing well- and moderately differentiated tubular adenocarcinoma without lymph node metastasis. According, a definitive diagnosis of T1N0M0, pStage IA duodenal adenocarcinoma was established according to the TNM classification of malignant tumors. The patient had an excellent recovery, with no duodenal carcinoma recurrence having been clinically diagnosed eight years post-surgery. The appreciation of the distal duodenum by EGD is important for the proper diagnosis and treatment of this rare early duodenal adenocarcinoma.

Key words: Early duodenal adenocarcinoma; Partial resection; Third duodenal portion

© 2021 The Authors. Published by ACT Publishing Group Ltd. All rights reserved.

Ono H, Yokoyama H, Yoshida H, Fukushima H, Kawakami M, Okamura M, Aoki T, Asakage N, Danjo Y, Nagashima K, Hayashi H, Nishihara H, Shimizu Y, Shimamura T, Kusano M. Adenocarcinoma of the Third Portion of the Duodenum with an Acute Cholecystitis. *Journal of Gastroenterology and Hepatology Research* 2021; **10(1)**: 3452-3455 Available from: URL: <http://www.ghrnet.org/index.php/joghr/article/view/3037>

INTRODUCTION

Primary adenocarcinoma of the duodenum (PDA) is a rare condition accounting for 0.5% of all gastrointestinal tract cancers^[1-5]. Adenocarcinomas are the most common histological type of malignant duodenal neoplasms, accounting for 50% of the cases, followed by carcinoid, leiomyosarcomas, and lymphomas^[4,6-8]. Most duodenal adenocarcinomas occur at the second portion of the duodenum (74%), followed by third (13%), fourth (9%), and first (4%) portions^[4]. This disease is often diagnosed late due to nonspecific and vague symptoms and signs, which are similar to those found in many benign conditions^[3,5,7,9]. In cases involving the third and fourth portions of the duodenum, the diagnosis may be even more delayed given the poor success rates of endoscopic examination of the distal duodenum^[9,10]. We herein report a case of a 52-year-old Japanese female with primary adenocarcinoma of the third portion of the duodenum who presented with epigastric pain due to acute cholecystitis with a gallstone.

CASE REPORT

A 52-year-old Japanese female with a body mass index of 22.7 kg/m² was referred to our hospital on October 2012 with acute cholecystitis. Physical examination revealed epigastric pain and a body temperature of 36.6°C. Laboratory finding showed a white blood cell count of 8,800/μL, C-reactive protein level of 0.30 mg/dL, Low density lipoprotein-cholesterol level of 192 mg/dL, triglyceride level of 281 mg/dL, carcinoembryonic antigen level of 3.9 ng/mL, and carbohydrate antigen 19-9 level of 35 U/mL. Abdominal ultrasound and computed tomography (CT) revealed cholecystitis with a gallstone. Thereafter, esophagogastroduodenoscopy (EGD) was performed, revealing a depressed-type duodenal tumor 15 mm in size on the third portion (Figure 1). India ink dye was then injected at two opposite sites close to the lesion, after which biopsies were performed. Histopathological examination confirmed a diagnosis of adenocarcinoma. After obtaining informed consent, partial duodenectomy and cholecystectomy were performed to relieve the pain. Macroscopic observation revealed a depressed-type duodenal tumor measuring 15×8 mm (Figure 2). The tumor exhibited submucosal invasion, 1000μm in depth (Figure 3). Histological examination showed a well-differentiated tubular adenocarcinoma partially comprising moderately differentiated tubular adenocarcinoma (Figure 4) without lymph node metastasis. A definitive diagnosis of T1N0M0, pStage IA duodenal adenocarcinoma was established according to the TNM classification of malignant tumors. The patient had an excellent recovery, with no duodenal carcinoma recurrence having been clinically diagnosed eight years post-surgery.

DISCUSSION

Primary adenocarcinoma of the duodenum (PDA), excluding that of the ampulla of Vater, is a rare condition first described in 1746 by Hamburgur^[7]. Various etiological and risk factors, such as familial adenomatous polyposis, Gardner's and Turcot's syndrome, Crohn's disease, celiac disease, polypoid lesions, and Lynch's syndrome, have been related to duodenal adenocarcinoma^[7,8,10]. Moreover, the extreme rarity and vagueness of presenting symptoms make duodenal adenocarcinoma challenging to diagnose. The most frequent signs and symptoms found in patients with duodenal adenocarcinoma have been abdominal pain, weight loss, nausea, anemia, and vomiting^[3,4,7]. Although abdominal pain was present in the current case, we considered this to have been caused by cholecystitis.

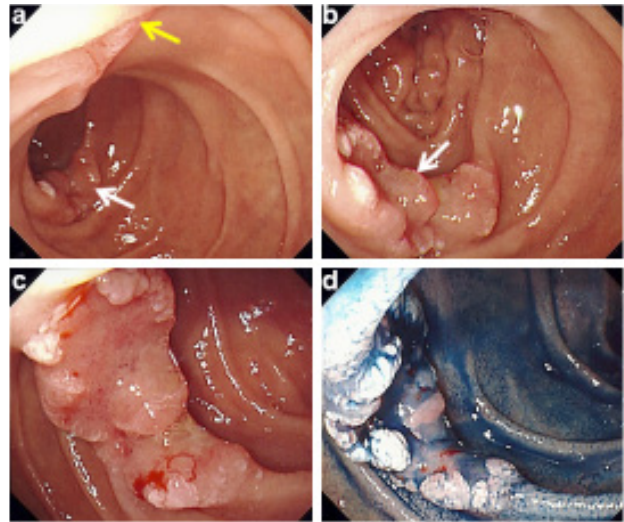


Figure 1 (a) Esophagogastroduodenoscopy (EGD) showing a small depressed tumor in the third portion of the duodenum (white arrow). The yellow arrow indicates the papilla of Vater. (b) The white arrow indicates the depressed tumor. (c) Image showing a depressed-type tumor 15 mm in size. (d) Image showing the tumor showed after an indigocarmine spray.




Figure 2 Macroscopy showing a tumor measuring 15×8 mm in size. Red lines indicate submucosal invasion.

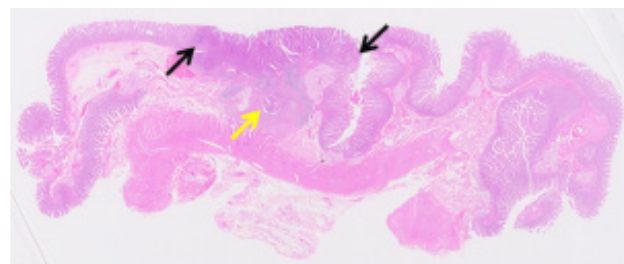


Figure 3 Adenocarcinoma with mucosal invasion (black arrows) at the low-power microscope and a tumor with partial submucosal invasion, 1000 μm in depth (yellow arrow).

Diagnostic methods may include barium meal, abdominal CT, EGD, double balloon enteroscopy (DBE), and capsule endoscopy. Barium meal radiography may also be extremely valuable in identifying large endoluminal lesions^[8-10], while CT can be useful for visualizing and staging the tumor^[8]. Although conventional endoscopy may diagnose proximal tumors, it is inadequate for distal duodenal tumors^[9]. DBE, first described by Yamamoto *et al.* in 2001, consists of an enteroscope, an overtube and a balloon pump controller^[11]. This

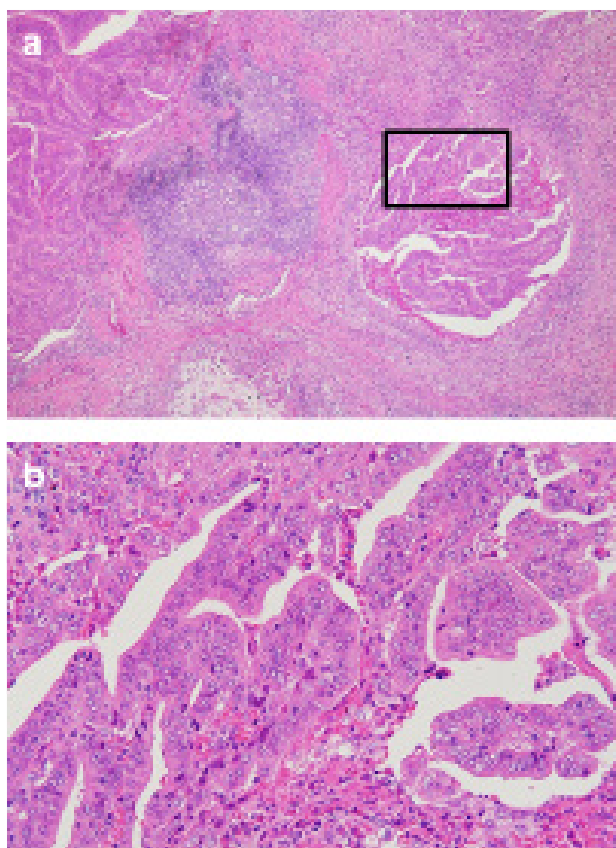


Figure 4 (a) Histological examination showing submucosal invasion (40×). (b) Enlarged boxed section of Figure a. Well-differentiated tubular adenocarcinoma partially comprising moderately differentiated tubular adenocarcinoma (200×) in hematoxylin and eosin-stained sections.

type of endoscope can be advanced by pushing it through the over-tube, allowing endoscopic visualization of the entire small bowel, biopsies, and therapeutic intervention^[12]. Capsule endoscopy can simplify the diagnosis of small bowel or duodenal adenocarcinoma^[13].

Some studies have reported that lymph node status, duodenum invasion, pancreas invasion, and tumor size can serve as predictors of survival in patients with duodenal adenocarcinoma who had undergone surgery^[2, 14-16]. Some studies have reported that radical resection offers good long-term results for locally advanced duodenal adenocarcinoma. Resected patients and nonresected patients with PDA had 5-year survival rates of 25-75% and 0%, respectively^[9, 14, 17]. Reports have shown 5-year survival rates of 100% and 52% for stage I and II disease and 45% and 0% for stage III and IV disease, respectively^[9].

Early stage duodenal carcinoma should be an indication for endoscopic mucosal resection. Patients with advanced-stage PDA who are medically fit to undergo surgery should be given the option of aggressive resection^[18]. Duodeno-cephalo-pancreatectomy (DCP) and segmental resection of the duodenum have also been employed for treating PDA^[19]. DCP remains the standard treatment for adenocarcinomas of the first and second portion of the duodenum, while segmental duodenectomy has been the preferred resection method for patients with adenocarcinoma of the third and fourth portions of the duodenum^[20].

Given that the present case suffered from a T1-stage, well-differentiated tubular adenocarcinoma without histological lymph node metastases around the pancreas, we opted for partial resection of the duodenum, which resulted in excellent recovery and no sign of recurrence eight years post-surgery.

CONCLUSION

The appreciation of the distal duodenum by EGD is important for the proper diagnosis and treatment of this rare early duodenal adenocarcinoma.

REFERENCES

1. Yildirim S, Culhaoglu AB, Ozdemir N. Carcinoma of the fourth part of the duodenum: report of a case. *Surg Today*. 1995; **25**(12): 1034-7. [PMID: 8645936]; [DOI: 10.1007/BF00311688]
2. Ryder NM, Ko CY, Hines OJ, Gloor B, Reber HA. Primary duodenal adenocarcinoma: a 40-year experience. *Arch Surg*. 2000; **135**(9): 1070-4. [PMID: 10982512]; [DOI: 10.1001/archsurg.135.9.1070]
3. Bakaeen FG, Murr MM, Sarr MG, Thompson GB, Farnell MB, Nagorney DM, Farley DR, van Heerden JA, Wiersema LM, Schleck CD, Donohue JH. What prognostic factors are important in duodenal adenocarcinoma? *Arch Surg*. 2000; **135**(6): 635-41. [PMID: 10843358]; [DOI: 10.1001/archsurg.135.6.635]
4. Abrahams NA, Halverson A, Fazio VW, Rybicki LA, Goldblum JR. Adenocarcinoma of the small bowel: a study of 37 cases with emphasis on histologic prognostic factors. *Dis Colon Rectum*. 2002; **45**(11): 1496-502. [PMID: 12432298]; [DOI: 10.1097/01.DCR.0000034134.49346.5E]
5. Tocchi A, Mazzoni G, Puma F, Miccini M, Cassini D, Bettelli E, Tagliacozzo S. Adenocarcinoma of the third and fourth portions of the duodenum: results of surgical treatment. *Arch Surg*. 2003; **138**(1): 80-5. [PMID: 12511157]; [DOI: 10.1001/archsurg.138.1.80]
6. DiSario JA, Burt RW, Vargas H, McWhorter WP. Small bowel cancer: epidemiological and clinical characteristics from a population-based registry. *Am J Gastroenterol*. 1994; **89**(5): 699-701. [PMID: 8172140]
7. Heniford BT, Iannitti DA, Evans P, Gagner M, Henderson JM. Primary nonampullary/periampullary adenocarcinoma of the duodenum. *Am Surg*. 1998; **64**(12): 1165-9. [PMID: 9843337]
8. Gill SS, Heuman DM, Mihas AA. Small intestinal neoplasms. *J Clin Gastroenterol*. 2001; **33**(4): 267-82. [PMID: 11588539]; [DOI: 10.1097/00004836-200110000-00004]
9. Santoro E, Sacchi M, Scutari F, Carboni F, Graziano F. Primary adenocarcinoma of the duodenum: treatment and survival in 89 patients. *Hepatogastroenterol*. 1997; **44**(16): 1157-63. [PMID: 9261617]
10. Fronticelli CM, Borghi F, Gattolin A, Ferrero A, Delsedime L. Primary adenocarcinoma of the angle of Treitz. Case report and review of the literature. *Arch Surg*. 1996; **131**(10): 1109-11. [PMID: 8857913]; [DOI: 10.1001/archsurg.1996.01430220103025]
11. Yamamoto H, Sekine Y, Sato Y, Higashizawa T, Miyata T, Ino S, Ido K, Sugano K. Total enteroscopy with a nonsurgical steerable double-balloon method. *Gastrointest Endosc*. 2001; **53**(2): 216-20. [PMID: 11174299]; [DOI: 10.1067/mge.2001.112181]
12. Yamamoto H, Kita H, Sunada K, Hayashi Y, Sato H, Yano T, Iwamoto M, Sekine Y, Miyata T, Kuno A, Ajibe H, Ido K, Sugano K. Clinical outcomes of double-balloon endoscopy for the diagnosis and treatment of small-intestinal diseases. *Clin Gastroenterol Hepatol*. 2004; **2**(11): 1010-6. [PMID: 15551254]; [DOI: 10.1016/s1542-3565(04)00453-7]
13. Schwartz GD, Barkin JS. Small-bowel tumors detected by wireless capsule endoscopy. *Dig Dis Sci*. 2007; **52**(4): 1026-30. [PMID: 17380403]; [DOI: 10.1007/s10620-006-9483-8]
14. Bucher P, Gervaz P, Morel P. Long-term results of radical resection for locally advanced duodenal adenocarcinoma. *Hepatogastroenterol*. 2005; **52**(66): 1727-9. [PMID: 16334766]
15. Kaklamanos IG, Bathe OF, Franceschi D, Camarda C, Levi

- J, Livingstone AS. Extent of resection in the management of duodenal adenocarcinoma. *Am J Surg.* 2000; **179**(1): 37-41. [PMID: 10737576]; [DOI: 10.1016/s0002-9610(99)00269-x]
16. Ohigashi H, Ishikawa O, Tamura S, Imaoka S, Sasaki Y, Kameyama M, Kabuto T, Furukawa H, Hiratsuka M, Fujita M, Hashimoto T, Hosomi N, Kuroda C. Pancreatic invasion as the prognostic indicator of duodenal adenocarcinoma treated by pancreatoduodenectomy plus extended lymphadenectomy. *Surgery.* 1998; **124**(3): 510-5. [PMID: 9736903]
 17. Hu JX, Miao XY, Zhong DW, Dai WD, Liu W, Hu W. Surgical treatment of primary duodenal adenocarcinoma. *Hepatogastroenterol.* 2006; **53**(72): 858-62. [PMID: 17153441]
 18. Hurtuk MG, Devata S, Brown KM, Oshima K, Aranha GV, Pickleman J, Shoup M. Should all patients with duodenal adenocarcinoma be considered for aggressive surgical resection? *Am J Surg.* 2007; **193**(3): 319-24. [PMID: 17320527]; [DOI: 10.1016/j.amjsurg.2006.09.013]
 19. Sista F, Santis GD, Giuliani A, Cecilia EM, Piccione F, Lancione L, Leardi S, Amicucci G. Adenocarcinoma of the third duodenal portion: Case report and review of literature. *World J Gastrointest Surg.* 2012; **4**(1): 23-6. [PMID: 22347539]; [DOI: 10.4240/wjgs.v4.i1.23]
 20. Lowell JA, Rossi RL, Munson JL, Braasch JW. Primary adenocarcinoma of third and fourth portions of duodenum. Favorable prognosis after resection. *Arch Surg.* 1992; **127**(5): 557-60. [PMID: 1349472]; [DOI: 10.1001/archsurg.1992.01420050081010]