

Recanalization of the Portal Vein with a six Years' Occlusion after Orthotopic Liver Transplantation with Cavoportal Hemitransposition: A Case Report

Lei JY, Yan LN, Wang WT

Lei JY, Yan LN, Wang WT, Liver Transplantation Center, West China Hospital of Sichuan University, Chengdu 610041, China
Correspondence to: Yan LN, MD, PhD, Liver Transplantation Center, West China Hospital of Sichuan University, Chengdu 610041, China. yanlunadoctor@163.com
Telephone: +086-28-85422867 Fax: +086-28-85422867
Received: September 13, 2012 Revised: October 2 2012
Accepted: October 6, 2012
Published online: December 21, 2012

ABSTRACT

We report herein a case with recanalization of the portal vein after the complete occlusion in an orthotopic liver transplantation (OLT) with cavoportal hemitransposition six years ago. The patient suffered from end-stage post-hepatitis C cirrhosis with diffused portomesenteric vein thrombosis (PVT), so the caval inflow to the graft was used as a salvage approach in this case. One month after OLT with cavoportal hemitransposition, the cavoportal anastomosis stoma and the inferior vena cava were occluded by the extensive thrombosis, the inferior vena cava developed recanalization with partial collateral circulation after thrombolysis therapy, but the cavoportal anastomosis stoma blockage lasted six years until 1 month ago the patient's abdominal enhanced CT indicated blood flow stream in the left and right branch of portal vein (Figure C). This case gives us confidence to practice the cavoportal hemitransposition and handle the thrombosis of the anastomotic stoma.

© 2012 Thomson research. All rights reserved.

Key words: Recanalization; Occlusion; Cavoportal hemitransposition; Liver transplantation

Lei JY, Yan LN, Wang WT. Recanalization of the Portal Vein with a six Years' Occlusion after Orthotopic Liver Transplantation with Cavoportal Hemitransposition: A Case Report. *Journal of Gastroenterology and Hepatology Research* 2012; 1(11): 332-334 Available from: URL: <http://www.ghrnet.org/index./joghr/>

CASE REPORT

A 38-years-old man suffered from post-hepatitis C cirrhosis and two

years before transplantation, he got pericardial devascularization: a surgery disconnect the nerves and vessels of the gastric wall and esophagus^[1,2]. He needed a transplantation for cirrhosis, severe chronic encephalopathy, intractable ascites and high risk for re-bleeding from large esophagogastric varices^[3]. Preoperative angiography suggested diffuse thrombosis in both the portal and the superior mesenteric veins. He underwent orthotopic liver transplantation in 2006, diffused PVT was confirmed during transplantation: the recipient portal vein was closed and a cavoportal anastomosis of the donor portal vein and the recipient infrahepatic inferior vena cava was performed, and the other procedure was routine. The patient and the transplanted liver recovered slowly. Bedside ultrasonography was performed everyday in the first week and twice a week in the first month, the flow of portal vein began to decline from the 27th day postoperation, meanwhile, the diameter of the hepatic artery dilated gradually from 3 mm on the first day to the 10 mm on the 30th day, and the velocity of hepatic artery increased gradually, the patient's condition was stable and without the liver and renal function abnormal, so no action was taken except rigorous observation. 32 days after transplantation, the ultrasonography detect no flow in the portal vein and the patient developed ascites and lower extremity edema, the angiography of inferior vena cava was performed immediately showing cavoportal anastomosis stoma and the inferior vena cava were occluded for the thrombosis (Figure 1). On the 33th days after transplantation, we performed percutaneous pulse spray thrombolysis with urokinase through a femoral vein access, but it did not work. Although this failure, the massive collateral circulation opened in the posterior belly 4 days after the thrombosis (Figure 2) and ascites and edema of lower extremity improved gradually to disappear. So the portal vein was completely occluded by the thrombus and the graft was supplied only by the hepatic artery and no blood in the portal vein. Suffered temporal liver dysfunction and ascites, without kidney dysfunction, the patient was discharged on the 57 days after transplantation (total bilirubin: 1.87ng/dL; creatinine: 0.67 ng/dL) with a good clinical status and took 100mg aspirin capsule. In the nearly 6 years, the patient went back to his work and accepted routinely follow-up twice a year, the patient feel good except the varicose veins of lower extremity. In the six years, no renal and liver dysfunction was observed (Figure 3A and 3B) except the last follow-up, the total bilirubin reached 3.64 ng/dL for his personal decrement of tacrolimus. The patient accepted

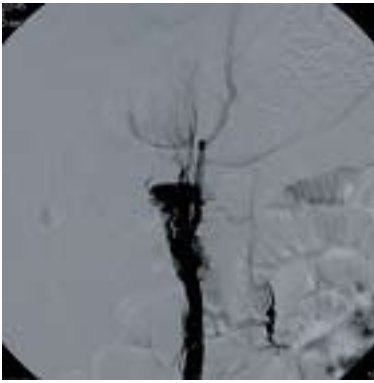


Figure 1 Angiography of inferior vena cava showing the cavoportal anastomosis and post-hepatic vena cava were occluded.

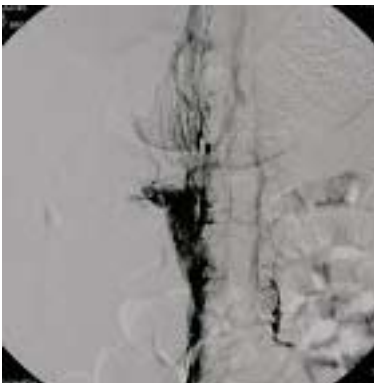


Figure 2 The formation of the massive collateral circulation in the posterior belly 4 days after the thrombosis.

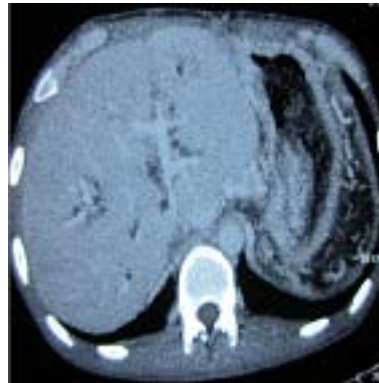


Figure 4 The enhance CT detect the blood flow in the intra-hepatic portal vein.

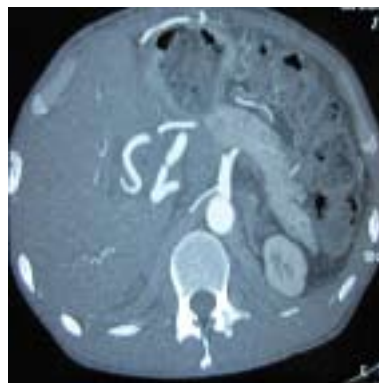


Figure 5 The diameter of the hepatic artery now is still bigger than normal.

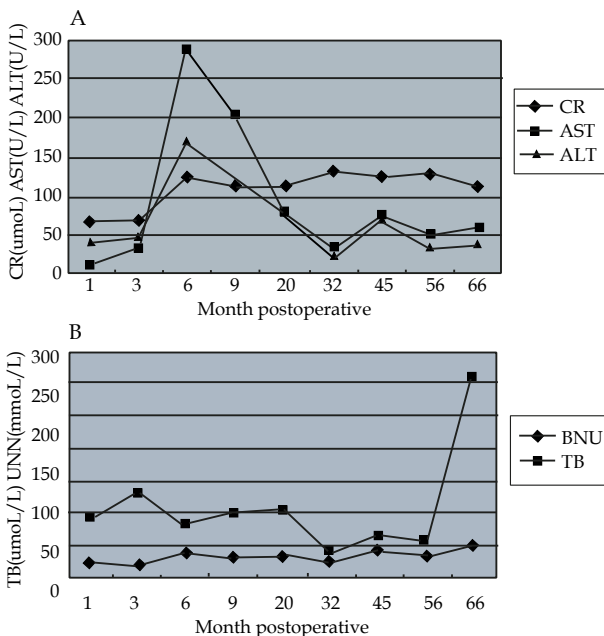


Figure 3 The changes of the renal and liver function in the 6 years follow-up.

routinely follow-up at the out-patients' department, no changes observed last follow-up half year ago, amazedly, the ultrasonography and the enhanced CT this time detected blood flow in the portal vein (Figure 4) but the cavoportal anastomosis stoma was still occluded by the thrombosis, no flow in the post-hepatic inferior vena cava. Meanwhile, the diameter of hepatic artery was still 8mm (Figure 5) bigger than normal and the 3D imaging CT showed the massive partial collateral circulation in the posterior belly (Figure 6).

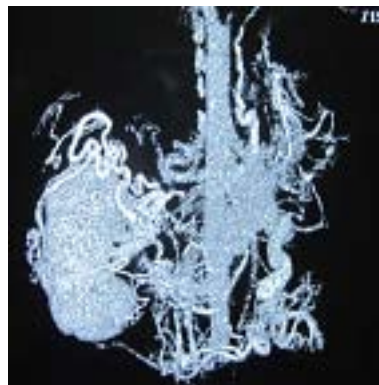

Figure 6 The massive collateral circulation in the posterior belly still exist now.

DISCUSSION

Portal vein thrombosis was once a contraindication for orthotopic liver transplantation^[4]. And the cavoportal hemitransposition was a surgical procedure that can be used in liver transplantation when the portal venous system was thrombosed and portal flow cannot be re-established from the mesenteric venous system^[5,6]. Besides ZR Shi^[7] reported firstly the cavoportal hemitransposition was used in adult-to-adult living donor liver transplantation. Although the cavoportal hemitransposition was used as the most useful way to solute this problem, the long term results had never been studied. Especially in this case, the graft was supplied only by the hepatic artery with the portal vein no-function for 6 years, the patient's survive was a miracle, 6 years without blood supply, the graft's portal vein got the blood supply again. The ultrasonography and enhanced CT both detected the cavaportal anastomosis stoma was still occluded by the thrombosis, where did the blood flow come from? The ultrasonography find there

were some small vein ranged 3 mm to 7 mm around the graft's portal vein and detected blood flow in the small vein flow into the portal vein, that could explain the recanalization of the portal vein.

What can we learn from this case? Six years occlusion, although the inferior vena cava was still obstructed and the liver perfused only by the hepatic artery without portal vein, the partial collateral circulation drained up the blood of inferior vena below the liver lead to the 6 years' survival; and the intra-hepatic portal vein's perfuse will support the patient's life.

REFERENCES

1. Li SY, Wu E, Liang ZJ, Yuan SJ, Yu B. Pericardial devascularization combined with preservation of Latarjet's nerves trunk in treatment of patients with portal hypertension. *Hepatobiliary Pancreat Dis Int* 2003; **2**: 66-68
2. Lin N, Liu B, Xu RY, Fang HP, Deng MH. Splenectomy with endoscopic variceal ligation is superior to splenectomy with pericardial devascularization in treatment of portal hypertension. *World J Gastroenterol* 2006; **12**: 7375-7379
3. FG Li, LN Yan, WT Wang. Extensive thrombosis of the portal vein and vena cava after orthotopic liver transplantation with cavoportal hemitransposition: a case report. *Transplantation Proceedings* 2008; **40**: 1777-1779
4. Azoulay D, Adam R, Castaing D, et al. Liver transplantation with cavoportal or renoportal anastomosis. A solution in cases of diffuse portal thrombosis. *Gastroenterol Clin Biol* 2001; **25**: 325
5. NV Jamieson. Changing perspectives in portal vein thrombosis and liver transplantation. *Transplantation* 2000; **69**: 1772-1774
6. JM Softeland, N Kvarnstrom, S Friman, M Olausson. Liver transplantation in the presence of diffuse of diffuse portal vein thrombosis: A 10 year experience with cavoportal hemitransposition: 2521: living liver donors and techniques. *Transplantation* 2010; **90**: 80
7. ZR Shi, LN Yan, WT Wang. Cavoportal hemitransposition in an adult-to-adult living-donor liver transplantation. *Dig Liver Dis* 2011; **43**: e2

Peer reviewers: Georg Roth, MD, Assistant Professor, Department of General Anesthesia and Critical Care, Medical University of Vienna, Waehringer Guertel 18-20, Vienna, A-1090, Austria; Ayse L. Mindikoglu, Assistant Professor Of Medicine, Department Of Medicine, Division Of Gastroenterology And Hepatology University Of Maryland School Of Medicine, 22 South Greene Street-N3w50, Baltimore, Maryland 21202, the United States.