

## Endoscopic Therapy for Chronic Recurrent Pancreatitis

Yoshiaki Kawaguchi, Tetsuya Mine

Yoshiaki Kawaguchi, Tetsuya Mine, Department of Gastroenterology, Tokai University School of Medicine, 143 Shimokasuya, Isehara, 259-1193, Japan

Correspondence: Yoshiaki Kawaguchi, MD, PhD, Department of Gastroenterology, Tokai University School of Medicine, 143 Shimokasuya, Isehara, 259-1193, Japan. [y711kawa@is.icc.u-tokai.ac.jp](mailto:y711kawa@is.icc.u-tokai.ac.jp)

Telephone: +81-463-93-1121 Fax: +81-463-93-7085

Received: July 1, 2012 Revised: August 30, 2012

Accepted: September 1, 2012

Published online: December 21, 2012

### ABSTRACT

Chronic recurrent pancreatitis develops as a result of pancreatic outflow disturbance associated with pancreatic duct stenosis or pancreatic stones in most cases. Therefore it is rational to reduce intrapancreatic ductal pressure by removing pancreatic outflow disturbance for treatment of chronic recurrent pancreatitis. Surgical procedures and endoscopic pancreatic stenting are available for decompression of the pancreatic duct. As endoscopic pancreatic stenting is less invasive, safe and effective method, this approach has spread rapidly. Comorbid pancreatic cancer should never be overlooked before stenting for chronic recurrent pancreatitis, because chronic recurrent pancreatitis carries a high risk of progressing to pancreatic cancer. In cases with a stone in the pancreatic duct, extracorporeal shock wave lithotripsy (ESWL) should be performed in combination with endoscopic pancreatic stenting. In this review we discuss the current status of endoscopic pancreatic stenting in the treatment of chronic recurrent pancreatitis.

© 2012 Thomson research. All rights reserved.

**Key words:** Chronic recurrent pancreatitis; Endoscopic pancreatic stenting (EPS); Extracorporeal shock wave lithotripsy (ESWL)

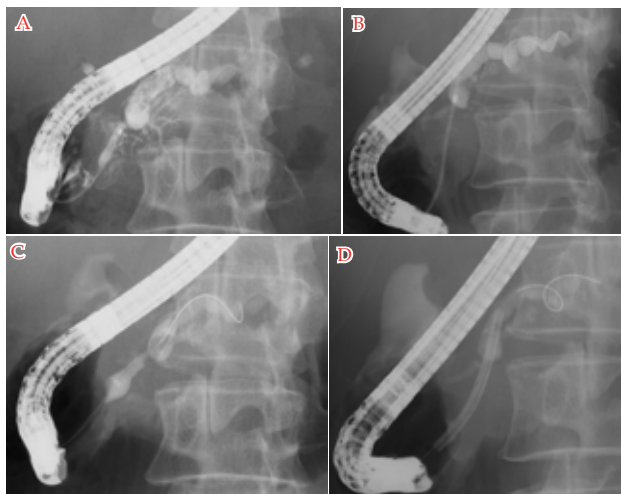
Kawaguchi Y, Mine T. Endoscopic Therapy for Chronic Recurrent Pancreatitis. *Journal of Gastroenterology and Hepatology Research* 2012; 1(11): 283-288 Available from: URL: <http://www.ghrnet.org/index./joghr/>

### INTRODUCTION

Chronic recurrent pancreatitis often develops as a result of increased pressure of the caudal pancreatic duct due to pancreatic duct stenosis caused by chronic inflammation of the pancreas or due to pancreatic outflow disturbance caused by pancreatic stones (calcifications)<sup>[1,2]</sup>. Increased pressure of the caudal pancreatic duct may complicate pancreatic cysts in the caudal pancreatic duct. Etiologically, chronic recurrent pancreatitis is most often associated with chronic alcohol abuse, and abstention from drinking is a key prerequisite for treatment of alcohol-related chronic recurrent pancreatitis. It is rational to reduce intrapancreatic ductal pressure by removing pancreatic outflow disturbance, in an effort to treat chronic recurrent pancreatitis. Two different approaches are available for decompression of the pancreatic duct: surgical procedures, such as pancreatectomy and pancreaticojejunostomy, and endoscopic pancreatic stenting (EPS). Cahen *et al*<sup>[3]</sup> conducted a randomized controlled trial comparing surgical treatment and EPS in the treatment of chronic recurrent pancreatitis and reported that surgical treatment was more effective than endoscopic treatment, but symptoms often persisted even after surgical treatment and approximately 60% of the patients treated had long-term clinical benefits from surgical interventions<sup>[4,5]</sup>. On the other hand, EPS has spread rapidly as a less invasive treatment for chronic recurrent pancreatitis<sup>[6]</sup>. According to previous data, the success rates for EPS range from 72% to 100%, and this procedure achieves a symptom improvement rate of 65-87%<sup>[7-12]</sup>. Among 61 patients with chronic recurrent pancreatitis who underwent endoscopic intervention at our hospital between April 2006 and July 2011, the success rate of EPS was 90% with a high symptom improvement rate of 93%. Nevertheless, treatment indications, stent selection, duration of stent placement, long-term clinical usefulness and safety, and limitations remain controversial<sup>[13]</sup>. Herein, we discuss the current status of EPS in the treatment of chronic recurrent pancreatitis.

### CONSIDERATIONS IN THE DIAGNOSIS OF CHRONIC RECURRENT PANCREATITIS

Since chronic recurrent pancreatitis is alcohol-related in most cases, it is relatively easy to diagnose based on history taking. However, when patients have no remarkable history of alcohol consumption, care should be taken in diagnosing chronic recurrent pancreatitis. Keeping familial or hereditary pancreatitis in mind, a family history should also



**Figure 1** A: Pancreatography showed main pancreatic duct stenosis; B: First the stenotic lesion was dilated using a dilation catheter with diameter of 7Fr; C: Secondly the stenotic lesion was dilated using a balloon catheter with diameter of 8mm; D: Finally a straight type pancreatic stent with diameter of 10 Fr was placed for pancreatic duct stenosis.

be obtained. Diagnostic imaging should be started with less invasive methods such as ultrasonography (US), computed tomography (CT) and magnetic resonance imaging (MRI). An appropriate combination of these various modalities enables identification of stenosis/dilation of the pancreatic duct, pancreatic pseudocysts, and stones. In particular, magnetic resonance cholangiopancreatography (MRCP) is a useful imaging technique allowing stenosis of the pancreatic duct to be identified and located. Chronic recurrent pancreatitis due to pancreas divisum should be taken into consideration particularly in cases of non-alcohol-related pancreatitis, though it is often difficult to diagnose, even based on MRCP. In such cases, endoscopic retrograde cholangiopancreatography (ERCP) is often required for definitive diagnosis of pancreas divisum. Thus, ERCP plays an important role not only for treatment but also for diagnosis of chronic recurrent pancreatitis. Since pancreatic stones are sometimes difficult to identify by contrast CT imaging alone, it is important to compare the findings with those by plain CT for the presence of pancreatic stones. Comorbid pancreatic cancer should never be overlooked when diagnosing chronic recurrent pancreatitis. Chronic recurrent pancreatitis carries a high risk of progressing to pancreatic cancer. In addition, it is often difficult to differentiate between pancreatic cancer and chronic recurrent pancreatitis with fibrosis, based on imaging findings. Therefore, CT and MRI scans should be carefully interpreted, and other imaging modalities such as endoscopic ultrasound (EUS), diffusion-weighted MRI and positron-emission tomography (PET) should be used in combination as required. Since diagnostic imaging alone is limited for diagnosis of pancreatic disease, histopathological examination involving ERCP or EUS-fine needle aspiration should be repeated in cases of suspected cancer. This is the definitive solution to the problem of overlooking pancreatic cancer. Simply stenting without complete exclusion of the possibility of pancreatic cancer should be strictly prohibited. Conversely, misdiagnosis of chronic recurrent pancreatitis as pancreatic cancer or autoimmune pancreatitis is occasionally encountered, including chronic recurrent pancreatitis either identified after pancreaticoduodenectomy or treated improperly with steroids based on a misdiagnosis of autoimmune pancreatitis. Exclusion of the possibility of pancreatic cancer can be very difficult, and surgical resection of the pancreas may therefore be performed even without sufficient pathological evidence. Nevertheless, making

every effort to minimize the possibility of misdiagnosis (e.g., repeated pathological examinations) is essential.

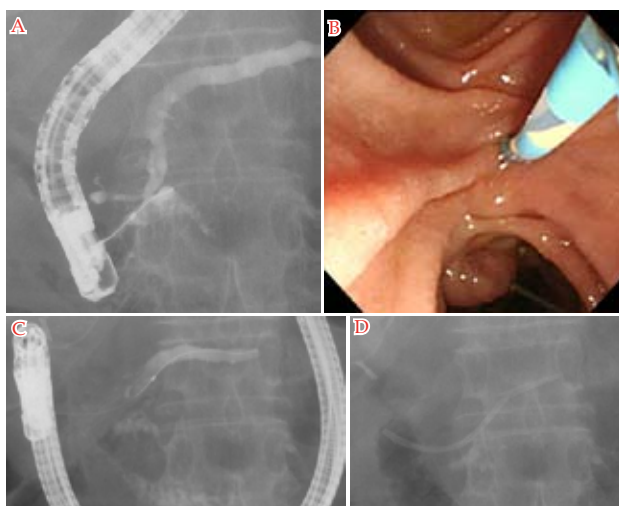
## INDICATIONS FOR EPS

At our hospital, EPS is indicated for patients with suspected pancreatic outflow disturbance (dilation of the caudal pancreatic duct and pancreatic cyst) due to stenosis of the main pancreatic duct or pancreatic stones who are symptomatic (with abdominal pain), retain residual pancreatic function, and/or are willing to abstain from drinking (in alcohol-related cases). In principle, EPS is not indicated for those who are asymptomatic or have devastating pancreatic functional damage. EPS is also highly indicated for pancreas divisum, which often causes chronic recurrent pancreatitis. Since chronic recurrent pancreatitis associated with pancreas divisum occurs as a result of increased intrapancreatic ductal pressure caused by pancreatic outflow from the dorsal pancreas via the minor papilla, decompression of the pancreatic duct by incision of the minor papilla, as well as balloon dilation and stenting involving an approach via the minor papilla, is effective in controlling symptoms of pancreatitis.

## APPROACHES TO REMOVING PANCREATIC OUTFLOW DISTURBANCE BASED ON THE TYPE OF CHRONIC RECURRENT PANCREATITIS

Based on the findings of initial ERCP, chronic pancreatitis can be classified into three types: pancreatic stone type (characterized by the existence of pancreatic stones), pancreatic duct stenosis type (characterized by the existence of pancreatic duct stenosis), and combined type (characterized by co-existence of both pancreatic stones and pancreatic duct stenosis). Among 61 patients with chronic recurrent pancreatitis who underwent endoscopic intervention at our hospital, pancreatic stone type, pancreatic duct stenosis type, and combined type accounted for 21% (13/61), 18% (11/61), and 61% (37/61), respectively. Thus, pancreatic duct stenosis was observed in 79% (48/61) of these patients, suggesting that treatment of pancreatic duct stenosis may be the key to successful treatment of chronic recurrent pancreatitis.

(1) In chronic recurrent pancreatitis caused by pancreatic stones, mechanical destruction of stones by extracorporeal shock wave lithotripsy (ESWL) is helpful. Prior ERCP can confirm the position of each target stone blocking pancreatic outflow. When the stone is difficult to identify on X-ray film (e.g., small size, overlapping with vertebrae), a short pancreatic stent is placed at the cephalad side of the stone as a marker (if stent passage is possible, the stent tip can be positioned at the caudal side of the stone), thereby facilitating efficient performance of ESWL. When the stone is located close to the opening of the pancreatic duct, it is impossible to place a pancreatic stent; thus, a biliary stent is placed as a marker. Endoscopic pancreatic sphincterotomy (EST) and pancreatic stenting are also capable of preventing impaction of pancreatic stone fragments generated by ESWL. There may be stenosis of the papillary opening per se in some cases, and pancreatic sphincter pre-cutting is an effective solution. We usually repeat the cycle of ESWL and ERCP for lithotomy, aiming at complete removal of stones during a single admission. If the pancreatic stone to be removed is extremely large, the patient is tentatively discharged when placement of a pancreatic stent is made possible at the caudal side of the remaining stone in the pancreatic duct dilated after partial stone disruption to further repeat intermittent admissions until complete removal of the stone is achieved.



**Figure 2** A: As pancreatography showed stenosis and filled stones in Wirsung duct, an approach via the major papilla was difficult; B: We selected an approach via the minor papilla; C: As pancreatography showed pancreatic duct stenosis and dilatation in pancreatic tail, minor papilla and stenotic lesion were dilated using dilation catheter after cannulation; D: A straight type pancreatic stent with diameter of 7 Fr was placed for pancreatic duct stenosis.

(2) To treat chronic recurrent pancreatitis with pancreatic duct stenosis, the site of stenosis is identified by pancreatography and an attempt is then made to pass the guide wire through the obstructed portion of the pancreatic duct using guide wires of different types (Figure 1 A). Guide wire passage is often difficult due to fibrosis of the pancreatic parenchyma surrounding the obstructed portion of the pancreatic duct. In such cases, all possible care should be taken to avoid injuries of the pancreatic duct due to careless guide wire handling. Even when guide wire passage through the obstructed portion of the pancreatic duct is possible, it is common for catheter passage to not be possible through the same part of the pancreatic duct. In such cases, coordinated manipulation of the guide wire and catheter is of key importance. With failure of passage, change first to a catheter with a smaller diameter or a dilation catheter (Soehendra Stent Retriever, Winston-Salem, NC) and gradually increase the catheter diameter or dilate the balloon at the tip of the dilation catheter (Figure 1B to 1D). In cases with severe stenosis, insertion of a dilation balloon is often difficult and use of a solid and springy dilation catheter is helpful. Addition of dilation balloons as necessary improves the passage of treatment instruments. When even passage of a dilation catheter fails, a stent retriever should be used. If the caudal major pancreatic duct is not visualized by pancreatography, there is a possibility that the guide wire is entering a side branch of the pancreatic duct. In such cases, care should be taken to avoid injury of the branch caused by guide wire manipulation. While an approach via the minor papilla is very useful when guide wire passage through the site of stenosis is extremely difficult (e.g., severe stenosis of the duct of Wirsung, marked bending at the neck of the main pancreatic duct, loop in the pancreatic duct), this approach is often associated with technical difficulties (cannulation in particular) (Figure 2A to 2D). We use a metal-tipped or tapered catheter for contrast pancreatography or pull out a small portion of the guide wire from the catheter tip prior to cannulation. When standard methods of cannulation have been exhausted, an incision of the minor papilla is made with a needle knife papillotome. After cannulation, dilation is maintained with dilation catheters (with a gradual increase in catheter size or dilation of the balloon), while opening the minor papilla dilated with a balloon as well as the site of pancreatic duct

stenosis. Since stenosis is extremely severe in most cases requiring an approach via the minor papilla for catheter passage, subsequent stenting is routinely performed to prevent restenosis and maintain dilation. Long-term stent placement is associated with problems as described below.

(3) Both pancreatic stones and pancreatic duct stenosis are observed in many chronic recurrent pancreatitis cases. This may be explained by pancreatic fluid pooling in the pancreatic duct due to stenosis and thereby facilitating the formation of pancreatic stones<sup>[14]</sup>. Therefore, treatment of chronic recurrent pancreatitis of this type involves ESWL and EPS in combination and should, ideally, be conducted at a medical institution capable of performing ESWL.

## PROBLEMS WITH EPS

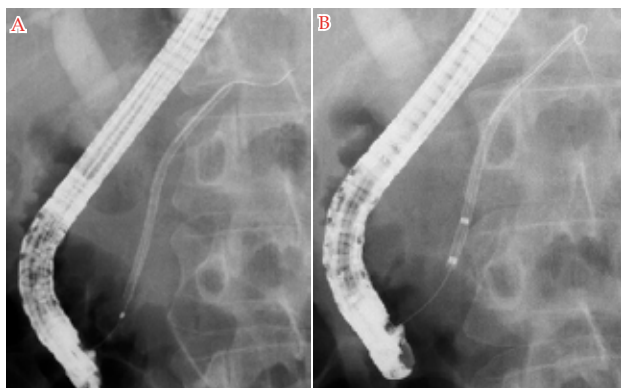
After passage and dilation of the site of pancreatic duct stenosis, long-term stent placement is performed in some cases to prevent restenosis and ensure dilation. However, there is no consensus regarding the procedure for stent placement, and stent procedures varied in different medical institutions.

### Stent selection

To date, there is no consensus regarding the diameter, shape and length of a stent, or the number of stents. We previously used a 10-Fr straight-type stent whenever possible, assuming that a stent with a larger diameter would be more favorable for dilation of the obstructed pancreatic duct. However, no significant difference in the rate of stent free due to removal of pancreatic duct stenosis was observed between stents with smaller (5 or 7 Fr) and larger (8.5 or 10 Fr) diameters. Therefore, we currently use a 7-Fr straight stent in most cases. When severe stenosis is present, a 5-Fr stent is placed first, and replaced with a 7-Fr stent at the time of first exchange. It should be noted that a stent with a small diameter placed at the site of severe stenosis may rupture upon removal for stent exchange. An S-shaped stent (8.5 Fr and 10 Fr, Olympus Optical Co. Ltd., Tokyo, Japan), designed to fit the main pancreatic duct morphologically, is commercially available and reportedly fits the pancreatic duct with minimum harm to the pancreas and prevents deviation and migration<sup>[15]</sup>. An attempt to temporarily place a fully covered self-expandable metallic stent has recently been documented<sup>[16,17]</sup>. Such a stent may be effective for dilation of an obstructed pancreatic duct and facilitate removal of stones in the caudal pancreatic duct. However, due to remaining concerns regarding the duration of stent placement and incidental complications (e.g., migration, deviation, difficulties in removal), further safety assessment is needed for this new stent.

### Insertion and placement of a stent

There are some tips for successful stent insertion. Since stenosis is severe even after successful dilation, placement of a pusher-type stent less springy than a dilation catheter requires careful insertion. On stent insertion, the operator should adjust the erection base and the up-angle dial of an endoscope to avoid detachment of the endoscope from the papilla, align the stent along the axis in the direction of the pancreatic duct, and then insert the stent as if pushing the entire stent straight into the pancreatic duct. During the stent insertion process, coordinated manipulation between the operator and assistant is also important. The assistant should apply constant pulling tension to the guide wire to avoid both excess and insufficient guide wire insertion depth. When the side flap at the papillary end of the stent becomes visible in the endoscopic view, the stent should be carefully pressed to the papilla with a pusher to avoid migration, followed by removal of the guide wire.



**Figure 3** A: Case with pancreatic duct stenosis. After a sigmoid type pancreatic stent with diameter of 8.5 Fr was placed, the pancreatic stent was migrated. A guide wire successfully entered the migrating stent cavity; B: The stent could be retrieved with a balloon catheter.

### Duration of stent placement

How long should a stent be left in the pancreatic duct? The standard duration of stent placement is one year in our hospital, though earlier removal is possible if pancreatography, taken at the time of stent exchange, revealed sufficient dilation of the stenosis site, removal of dilation in the caudal pancreatic duct, and absence of residual stone(s) in the caudal pancreatic duct along with satisfactory symptom control. On the contrary, if insufficient resolution of stenosis or residual stone presence in the caudal pancreatic duct is observed even after one year of stent placement, a substantial risk of disease recurrence is highly likely and stent placement in such cases is therefore continued after providing a thorough explanation to the patient. Since restenosis after stent removal, even when decided according to the above-mentioned criteria, is observed in some patients, further careful follow-up is necessary. It should also be noted that morphological changes (e.g., exacerbation of pancreatic duct stenosis, formation of pancreatic cysts) may occur during prolonged stent placement. Regardless of the presence or absence of a stent in the pancreatic duct, care should be taken not to overlook the development of pancreatic cancer during follow-up after stent placement.

### Timing of stent exchange

When should the stent be exchanged? We generally exchange a stent 3 months after placement, although the interval of stent exchange may depend on stent diameter. At the time of this regular exchange, the stent removed from the pancreatic duct is often obstructed either completely or partially. It is essential to exchange a stent any time there is recurrence of pancreatitis or the development of pancreatic duct inflammation, both due to stent obstruction. Compared with a bile stent, a pancreatic stent (even with a larger diameter of 10 Fr) tends to become obstructed in a shorter time due to the influences of protein plug deposition and increased viscosity caused by reduced pancreatic fluid volume<sup>[14]</sup>, and should therefore be exchanged once every 3 months despite the inconvenience and burden on the patient. Stents with larger diameters may facilitate dilation of the obstructed pancreatic duct but cannot be expected to consistently maintain long-term patency. On the other hand, we have often experienced stent obstruction that does not always lead to recurrence of pancreatitis. This may be attributable to outflow of pancreatic fluid passing through the interspace between the stent outer surface and inner wall of the pancreatic duct, supporting the concept of pancreatic fluid flowing out of branches of the pancreatic duct through the interspace between the inner wall of the main pancreatic duct and the stent outer surface. Although not yet marketed in Japan, a novel "wing" stent (ViaDuct

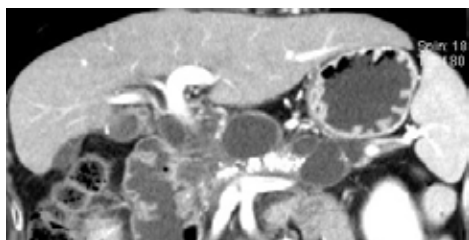
stent, GI Supply, Camp Hill, PA) with a star-shaped cross section, designed to drain fluid around itself along its multiple grooved wings, achieves excellent drainage from side branches of the pancreatic duct and may thereby allow placement for a longer duration<sup>[18]</sup>.

### Incidental complications

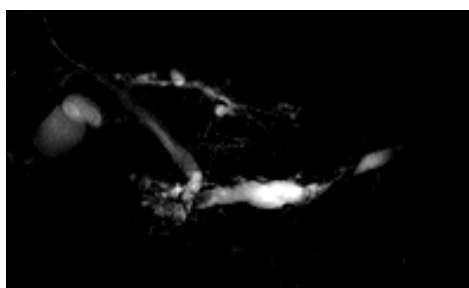
Incidental complications associated with stent placement include injuries of the pancreatic duct. These may be attributable to careless handling of a guide wire in most cases and can be avoided by careful manipulation. Similar to the situation with a bile duct stent, it should be noted that a pancreatic stent may induce pain associated with stent placement as well as recurrence of pancreatitis, development of pancreatic duct inflammation, and pancreatic abscess all associated with obstruction of the stent or side branches of the pancreatic duct as early-to-late incidental complications. Upon development of abdominal pain and fever after stent placement, stent exchange or removal should be considered, taking these incidental complications into consideration. Other late incidental complications associated with the use of a pancreatic stent include migration, deviation, rupture on removal, and injury of the contralateral duodenal mucosa. Migration may occur both upon placement and during the placement period. Migration upon placement can be avoided by careful stent insertion. To avoid stent migration during the placement period, stent exchange at intervals of approximately 3 months is desirable, because improvement of stenosis per se increases this risk. To retrieve a migrating stent, a guide wire is introduced into the pancreatic duct. If the guide wire successfully enters the stent cavity, the stent can be retrieved with a stent retriever. Otherwise, the guide wire is further inserted to reach the caudal side of the migrating stent and linearize the pancreatic duct and the stent can then be retrieved using a wire-guided basket, a snare with a guide wire, or a balloon catheter (Figure 3A to 3B). It should be noted that careless handling during stent retrieval may lead to injury of the pancreatic duct. Stent deviation may possibly cause ileus and intestinal perforation. Fortunately, we have not experienced perforation due to stent deviation. While improvement of pancreatic duct stenosis increases the risk of stent deviation, the deviating stent is expected to be stopped by the contralateral duodenal wall and the possibility of actual deviation may be minor. However, the shorter stents may have a greater tendency for deviation. Therefore, a short stent with a large diameter should be used with care, taking the possibility of deviation into consideration. Regarding stent rupture on removal, there is a high-risk population of patients with severe stenosis of the pancreatic duct, particularly those undergoing placement of a stent with a small diameter after stone destruction by ESWL. Careful stent removal is needed in such cases, but prevention of stent rupture by careful removal alone appears to be difficult, presumably due to deterioration of the stent caused by pancreatic fluid. Since stent rupture occurs in patients with severe stenosis, retrieval of the ruptured stent is difficult in most such cases. Due to the small diameter of the majority of ruptured stents, they are retrieved using a basket or some other instrument after inserting a guide wire deep into the caudal pancreatic duct. Retrieval of the ruptured stent is sometimes impossible and thorough informed consent in advance is thus mandatory.

### CASES REFRACTORY TO EPS

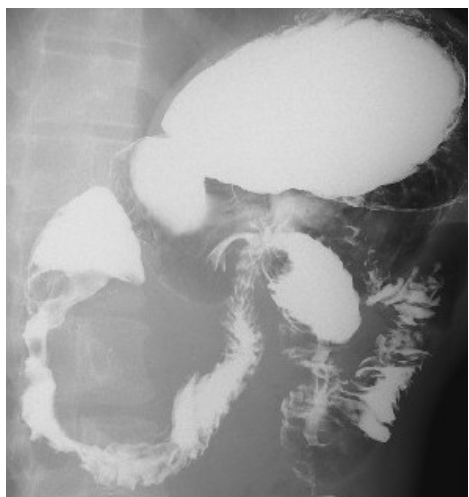EPS is difficult in cases of severe stenosis of the pancreatic duct, pancreatic stones filling the pancreatic duct (Figure 4), stenosis at multiple sites (Figure 5), and the comorbidity of duodenal stenosis (Figure 6). For the treatment of severe stenosis of the pancreatic duct, passage through the stenotic site is attempted using the various



**Figure 4** CT scan shows pancreatic stones filling the pancreatic duct and dilatation of the pancreatic duct.



**Figure 5** MRCP shows stenosis of the pancreatic duct at pancreatic head and tail.



**Figure 6** Gastroduodeno-fluoroscopy shows the comorbidity of duodenal stenosis.

treatment instruments described above. In some refractory cases, transpapillary drainage must be abandoned. Instead, transgastric endoscopic US-guided puncture of the caudal dilated pancreatic duct is attempted, aiming at guide wire passage through the site of stenosis from the caudal side. If guide wire passage is successful, then transpapillary stenting is performed by the rendezvous technique. Otherwise, transgastric placement of a pancreatic drainage tube is attempted. If the transpapillary and the transgastric approach are both difficult, a surgical approach should be considered. Decisions regarding the treatment of patients with pancreatic stones filling the pancreatic duct should be made carefully, after thorough consideration of symptoms and residual function of the pancreas (Figure 4). Endoscopic treatment is highly indicated for those with a dilated caudal pancreatic duct and pancreatic cyst formation. Destruction of stones by ESWL and retrieval of stone fragments are essential, and simple removal of stones may improve symptoms. If there are stenotic lesions and residual stones, pancreatic stenting is performed as necessary. In the treatment of stenosis at multiple sites, whether or not an endoscopic procedure is indicated should be determined carefully on a case-by-case basis (Figure 5). Resolution

of stenosis at all sites is often difficult. It should be noted that simple stent placement may induce pancreatic duct inflammation at the caudal side of the stenosis due to poor drainage. In patients with the comorbidity of duodenal stenosis, a transpapillary approach may not be possible if passage of the endoscope through the duodenum is difficult, and instead, a transgastric approach can be considered (Figure 6). However, surgical treatment is indicated if duodenal passage obstruction is present. Accordingly, close collaboration with a surgeon is desired prior to decision-making regarding the optimal treatment strategy for any patient with such a condition.

## SUMMARY OF EPS

The lacking of medical management for chronic recurrent pancreatitis will reduce quality of life for patients because of symptoms (e.g., pain, steatorrhea) and pancreatic dysfunctions (e.g., diabetes, pancreatic dyspepsia). Therefore we should perform medical management for chronic recurrent pancreatitis. Endoscopic pancreatic stenting for chronic recurrent pancreatitis is safe and effective method, and less invasive and cost-effective method compared with surgical procedures. We first perform endoscopic pancreatic stenting and ESWL for patients with chronic recurrent pancreatitis.

## CONCLUSIONS

Since chronic recurrent pancreatitis develops as a result of pancreatic outflow disturbance associated with pancreatic duct stenosis or pancreatic stones in most cases, these conditions are often treated successfully by endoscopic stenting that improves pancreatic outflow. Amelioration of symptoms will improve nutritional status, thereby leading to improvement of the patient's quality of life. However, since the major cause of chronic recurrent pancreatitis is alcohol abuse, there may be an alternative possibility that improvement of symptoms leads to resumption of drinking, discontinuation of outpatient visits, disease recurrence, and, ultimately, further emergency room visits. Adherence to abstention from drinking is the most important key to successful treatment of alcohol-related chronic recurrent pancreatitis.

## REFERENCES

- Gulliver DJ, Edmunds S, Baker ME, Paine S, Baillie J, Cotton PB, Rice RP. Stent placement for benign pancreatic diseases: correlation between ERCP findings and clinical response. *AJR Am J Roentgenol* 1992; **159**: 751-755
- Guda NM, Partington S, Freeman ML. Extracorporeal shock wave lithotripsy in the management of chronic calcific pancreatitis: a meta-analysis. *JOP* 2005; **6**: 6-12
- Adloff M, Schloegel M, Arnaud JP, Ollier JC. Role of pancreaticojejunostomy in the treatment of chronic pancreatitis. A study of 105 operated patients. *Chirurgie* 1991; **117**: 251-26
- Wilson TG, Hollands MJ, Little JM. Pancreaticojejunostomy for chronic pancreatitis. *Aust N Z J Surg* 1992; **62**: 111-115
- Weber A, Schneider J, Neu B, Meining A, Born P, Schmid RM, Prinz C. Endoscopic stent therapy for patients with chronic pancreatitis: results from a prospective follow-up study. *Pancreas* 2007; **34**: 287-294
- Cremer M, Devière J, Delhaye M, Baize M, Vandermeeren A. Stenting in severe chronic pancreatitis: results of medium-term follow-up in seventy-six patients. *Endoscopy* 1991; **23**: 171-176
- Rösch T, Daniel S, Scholz M, Huibregtse K, Smits M, Schneider T, Ell C, Haber G, Riemann JF, Jakobs R, Hintze R, Adler A, Neuhaus H, Zavoral M, Zavada F, Schusdziarra V, Soehendra N. Endoscopic treatment of chronic pancreatitis: a multicenter study of 1000 patients with long-term follow-up. *Endoscopy* 2002; **34**: 765-771

- 8 Dite P, Ruzicka M, Zboril V, Novotný I. A prospective, randomized trial comparing endoscopic and surgical therapy for chronic pancreatitis. *Endoscopy* 2003; **35**: 553-558
- 9 Ponchon T, Bory RM, Hedelius F, Rouben LD, Paliard P, Napoleon B, Chavaillon A. Endoscopic stenting for pain relief in chronic pancreatitis: results of a standardized protocol. *Gastrointest Endosc* 1995; **42**: 452-456
- 10 Smits ME, Badiga SM, Rauws EA, Tytgat GN, Huijbregtse K. Long-term results of pancreatic stents in chronic pancreatitis. *Gastrointest Endosc* 1995; **42**: 461-467
- 11 Byrne RL, Gompertz RH, Venables CW. Surgery for chronic pancreatitis: a review of 12 years experience. *Ann R Coll Surg Engl* 1997; **79**: 405-409
- 12 Nguyen-Tang T, Dumonceau JM. Endoscopic treatment in chronic pancreatitis, timing, duration and type of intervention. *Best Pract Res Clin Gastroenterol* 2010; **24**: 281-298
- 13 Yoo BM, Lehman GA. Update on endoscopic treatment of chronic pancreatitis. *Korean J Intern Med* 2009; **24**: 169-179
- 14 Ishihara T, Yamaguchi T, Seza K, Tadenuma H, Saisho H. Efficacy of s-type stents for the treatment of the main pancreatic duct stricture in patients with chronic pancreatitis. *Scand J Gastroenterol* 2006; **41**: 744-750
- 15 Park doH, Kim MH, Moon SH, Lee SS, Seo DW, Lee SK. Feasibility and safety of placement of a newly designed, fully covered self-expandable metal stent for refractory benign pancreatic ductal strictures: a pilot study (with video). *Gastrointest Endosc* 2008; **68**: 1182-1189,
- 16 Moon SH, Kim MH, Park doH, Song TJ, Eum J, Lee SS, Seo DW, Lee SK. Modified fully covered self-expandable metal stents with antimigration features for benign pancreatic duct strictures in advanced chronic pancreatitis, with a focus on the safety profile and reducing migration. *Gastrointest Endosc* 2010; **72**: 86-91
- 17 Raju GS, Gomez G, Xiao SY, Ahmed I, Brining D, Bhutani MS, Kalloo AN, Pasricha PJ. Effect of a novel pancreatic stent design on short-term pancreatic injury in a canine model. *Endoscopy* 2006; **38**: 260-265

**Peer reviewer:** Dawei Chen, professor, Room 301, No. 93, 50 GuangLan Road, PuDong 201203, Shanghai, China.