

Endoscopic Management of Common Bile Duct Stones

Alberto Tringali

Alberto Tringali, Endoscopy Unit, Niguarda Hospital, Milano, Italy

Conflict-of-interest statement: The author(s) declare(s) that there is no conflict of interest regarding the publication of this paper.

Open-Access: This article is an open-access article which was selected by an in-house editor and fully peer-reviewed by external reviewers. It is distributed in accordance with the Creative Commons Attribution Non Commercial (CC BY-NC 4.0) license, which permits others to distribute, remix, adapt, build upon this work non-commercially, and license their derivative works on different terms, provided the original work is properly cited and the use is non-commercial. See: <http://creativecommons.org/licenses/by-nc/4.0/>

Correspondence to: Alberto Tringali, Endoscopy Unit, Niguarda Hospital, Milano, Italy.

Email: albertotringali@ospedaleniguarda.it

Telephone: +39-0264442770

Fax: +39-0264442901

Received: June 18, 2016

Revised: July 18, 2016

Accepted: July 22, 2016

Published online: December 21, 2016

ABSTRACT

Gallstone disease is one of the most common reason for hospital admission. CBD stones are classified in primary and secondary stone on the basis of the site of origin. Clinical presentation varies from asymptomatic to life threatening conditions such as acute biliary pancreatitis and cholangitis. Patients are categorized in low, intermediate and high risk of choledocholithiasis using clinical, biochemical and imaging factors. Patients with low risk of choledocholithiasis should receive cholecystectomy without further evaluation while it has been recognized the importance of sequential use of EUS-ERCP in patients with intermediate risk of choledocholithiasis to triage patients in need for treatment. Patients with high risk of choledocholithiasis should receive ERCP before performing cholecystectomy although randomized clinical trial showed no benefit for preoperative ERCP over operative cholangiography and common duct exploration. Patients should be received an informed consent and antiplatelet and anticoagulation treatment should discontinued for the appropriate drug-specific

interval in according to the recent guideline. Routine administration to all patients undergoing to ERCP is considered unnecessary unless cholangitis or immunosuppression is present or biliary drainage is predicted to be incomplete. All patients undergoing to ERCP should be administered prophylactic drugs such as rectal indomethacin or diclofenac because of consistently reduced risk of post ERCP pancreatitis according to several meta-analysis and ESGE guideline. Endoscopic treatment is based on selective cannulation of the CBD and performing adequate endoscopic sphincterotomy. In case of failed biliary access several reasonable options could be chosen. CBD stone can be removed with either a basket or a balloon catheter in 85-90% of cases and the choice of the better device depends on common bile duct and stone size. Approximately 10-15% of biliary stone are difficult to extract and several technique, such as EPBD, PBSD and ML can be used. Alternative modality for the fragmentation of refractory CBD stone are intraductal lithotripsy (eg. Laser or Electrohydraulic lithotripsy) and ESWL. Mirizzi syndrome is usually treated by surgery although although there have been case reports of endoscopic removal. Intrahepatic stones are treated by dormia basket on guidewire after balloon dilation if stricture is present, or cholangioscopy with intraductal lithotripsy, per-oral cholangioscopic lithotripsy (POCSL) or percutaneous transhepatic cholangioscopy lithotripsy (PTCSL) and surgical resection (Hepatectomy). POCSL and PTCSL are hindered by high rates of stone recurrence. Biliary stenting as definitive treatment of difficult bile duct stone should be reserved for patients with short life expectancy. A review of case series suggest that BS is a safe and effective treatment for common bile duct stone in the pregnant patient but may be associated with higher risk of post ERCP pancreatitis than in the general population.

Key words: Bile duct stone; Gallstone; Choledocholithiasis; Acute biliary pancreatitis; Cholangitis

© 2016 The Author(s). Published by ACT Publishing Group Ltd.

Tringali A. Endoscopic Management of Common Bile Duct Stones. *Journal of Gastroenterology and Hepatology Research* 2016; 5(6): 2212-2227 Available from: URL: <http://www.ghrnet.org/index.php/joghr/article/view/1933>

INTRODUCTION

Gallstone disease is one of the most common reasons for hospital admission^[1-3]. Women are two or three times more common than

men. About 10-15% adult population develop gallstone, 1-4% will develop symptoms each year^[4]. More than 95% of biliary tract disease are related to gallstone^[5]. The prevalence of common bile duct stone in patients with symptomatic gallstone varies but probably is about 10-20%^[6-7]. Risk factors for gallstone disease are divided in no modifiable and modifiable risk factors as shown in table 1.

In detail previous studies have shown that the genetic background accounts for 25% of the total disease risk^[8]. Linkage and case-control studies of candidate genes and recent genome-wide studies have identified multiple lithogenic genes, in particular the hepatocanalicular cholesterol transporter ABCG5/G8 and the bilirubin conjugating enzyme UGT1A1, as major genetic determinants of gallstones in humans^[8].

TYPES OF CBD STONES

Common bile duct stones are classified as primary and secondary on the basis of the site of origin.

Primary

Develop de novo in the primary or intrahepatic bile duct. These stones are often brownish-yellow in color, with a soft consistency and consist of calcium bilirubinate mixed with variable amounts of cholesterol and calcium salts. They are more common in Asian population than in the West. While the etiology remains conjectural, bacterial infections and biliary stasis are considered the two most important causative factors. Gastrointestinal tract microorganisms such as Escherichia coli, Proteus, Bacteroides and Clostridium have been isolated from the bile of patients with primary bile duct stones^[9].

Secondary

Originate in the gallbladder and then migrate into the common bile duct. It is unclear why gallstones migrate into the common duct in some patients. In one study the size of the cystic duct has been reported as the single most important determinant^[10]. Furthermore the presence of multiple small (< 5 mm) stones in the gallbladder posing a 4 fold higher risk of migration into common bile duct as opposed to larger and/or single stone^[11]. Factors and mechanism in gallstone formation are reported in table 2.

CLINICAL PRESENTATION

Asymptomatic biliary stone

A considerable proportion of patients with common or intrahepatic duct stone are asymptomatic and may be found incidentally during investigation for unrelated abdominal conditions.

Symptomatic biliary stones

May cause colicky pain, obstructive jaundice, acute biliary pancreatitis and cholangitis.

Obstructive jaundice: continuous obstruction from stone impaction in the distal CBD at level may manifest as progressive jaundice while when the stone impacts and disimpacts at the level of papilla or distal part of the CBD may present as fluctuating jaundice.

Pain: might be due to an increased pressure into biliary tree

Cholangitis: results from bacterial infection in the setting of biliary obstruction with different range of severity from a self-limited to a potentially life-threatening disease require urgent management. The pathogenesis involves several factors including elevated pressure into bile duct caused by obstruction, increased bacterial growth and bacterial or toxin translocation into vascular or lymphatic system which

Table 1 Risk Factors of gallstone disease.

No modifiable risk factors	Modifiable risk factors
Female gender	Obesity
Asian	Diet high calories and low fiber
Family history of gallstone	Prolonged fasting
Pregnancy	Rapid weight loss > 1.5 Kg per week
Hypertriglyceridemia/ low HDL	Drugs (clofibrate, ceftriaxone, oral contraceptive)
Metabolic syndrome	
Cirrhosis/Crohn's disease with severe ileal involvement/resection	
Genetics including genes responsible for biliary transport over hepatic canaliculi and for lipid metabolism	
Polymorphism in gene encoding cholesterol transporters ABCG5-G	
Variants of UGT1A1	

Table 2 Factors and mechanism in gallstone formation^[12,13]

• Impaired gallbladder functions (emptying, absorption, secretion)
• Supersaturated bile (Age, sex, genetics, obesity, drugs, diet, liver disease)
• Cholesterol nucleating factors (mucus, glycoprotein, Infection)
• Absorption/ entero-hepatic circulation of bile acids (Deoxycholate, bowel transit time, faecal flora, Ileal resection, cholestyramine)

Table 3 Performance of different diagnostic modalities.

Diagnostic technique	Sensitivity	Specificity	Limit/benefit
US CBD stone/ Dilated CBD/ cholangitis	30%/ 42%/ 11%	100% /96% /99%	
Helical CT scan	65-88% ^[25-28]	73-97%	Costs /radiation
MRCP	85-92% ^[29-30] 33-71% small stone (< 6mm) ^[31-32]	93-97%	Performance affects by stone size
IOC	59-100% ^[38]	93-100%	10-17 minute to perform during cholecystectomy
Laparoscopic US	71-100% ^[38]	96-100%	4-10 minutes

may lead to sepsis^[14].

Acute biliary pancreatitis: may result from gallstone migration which causes bile-pancreatic duct obstruction which increases pancreatic duct pressure, bile reflux, trypsin activation and pancreatic auto-digestion^[15].

NATURAL HISTORY

Data regarding natural history of choledocholithiasis are limited. Few studies indicate that 21-34% of CBD stones will spontaneously migrate^[16-17], and thus pose a moderate risk of pancreatitis (25-36%)^[16,17] or cholangitis in case of obstructed bile duct^[18].

DIAGNOSIS

The diagnosis of CBD stone is suspected if patients present with symptoms of abdominal pain, jaundice, and fever other than elevated liver enzymes, alkaline phosphatase or gamma-glutamyl transferase and serum bilirubin. Diagnosis is confirmed with imaging studies showing bile duct dilation and/or presence of common bile duct stones. The diagnostic accuracy with sensitivity and specificity of

different diagnostic techniques are summarized in table 3. The normal bile duct diameter is 3 to 6 mm^[19-20]. Biliary dilation greater than 8 mm in a patient with an intact gallbladder is usually indicative of biliary obstruction^[21].

No single variable accurately predicts choledocholithiasis and many authors have shown that the probability of a CBD stone is higher in the presence of multiple abnormal prognostic signs^[22-24]. There is no single scoring system accepted but using of clinical, biochemical and imaging factors patients can be categorized in low (< 10%), intermediate (10-50%) and high (> 50%) probability to have choledocholithiasis as summarized in table 4.

The higher morbidity of ERCP compared with EUS together with greater diagnostic accuracy of EUS compared with other diagnostic modality has led to many investigators to agree, in patients with intermediate risk of choledocholithiasis, on the use of sequential EUS and ERCP to triage patients in need of treatment^[38-41].

Given the relatively low prevalence (5-10%) of choledocholithiasis in patients with symptomatic cholelithiasis, a normal bile duct on US has a 95%-96% negative predictive value.

ALGORITHM OF DIAGNOSIS OF THE CBD STONE

A suggested management algorithm for patients with symptomatic cholelithiasis according to likelihood of CBD stones based on clinical predictors is shown in figure 1.

Low risk of choledocholithiasis

Patients with low risk of choledocholithiasis should undergo cholecystectomy without further evaluation because the cost and risks of additional preoperative imaging test are not justified by the low probability of CBD stone^[45,46].

Intermediate risk of choledocholithiasis

Patients with intermediate risk of choledocholithiasis benefit of additional evaluation to rule out the presence of CBD stone^[47-48]. The failure to identify CBD stone is burdened by the risk of symptoms recurrence, cholangitis and acute biliary pancreatitis^[13,14]. The diagnosis can be performed using magnetic resonance cholangiography, endoscopic ultrasound, intraoperative cholangiography (IOC) laparoscopic US to allow a stone removal at surgery or with postoperative ERCP depending on costs, local expertise.

High risk of choledocholithiasis

Patients with high probability of CBD stone should receive ERCP before surgery, but in the era of laparoscopic randomized clinical trial showed no benefit for preoperative ERCP over operative cholangiography and common duct exploration^[49].

Two RCTs compared 2 stage approach (preoperative ERCP followed by laparoscopic cholecystectomy) with an all surgical approach of laparoscopic IOC and trans-cystic stone removal in this setting^[50,51] showing that there are no difference in morbidity, mortality or primary ductal clearance rates (88%) between two groups.

Criticism on the use of predictors factors for establishing the presence of choledocholithiasis

A recent prospective study By Anderloni *et al*^[52] have shown that the predictors factors are unreliable for predicting the presence of CBD stones. In particular, it is worth noting that 20% of patients stratified in the low-risk group according to clinical parameters were found to have CBD stones by EUS, thus undergoing ERCP and avoiding the

Table 4 Predictors of choledocholithiasis.	
Predictors of choledocholithiasis ^[22,23,42,43,44]	
Very strong	
CBD stone on transabdominal US	
Clinical ascending cholangitis	
Bilirubin > 4 mg/dL	
Strong	
Dilated CBD on US (>6 mm with gallbladder in situ)	
Bilirubin level 1.8- 4 mg/dL	
Moderate	
Abnormal liver biochemical test other than bilirubin	
Age older than 55 y	
Clinical gallstone pancreatitis	
Assigning a likelihood of choledocholithiasis based on clinical predictors ^[22,23,42-46]	
Presence of any very strong predictor	High
Presence of both strong predictors	High
No predictors present	Low
All other patients	Intermediate

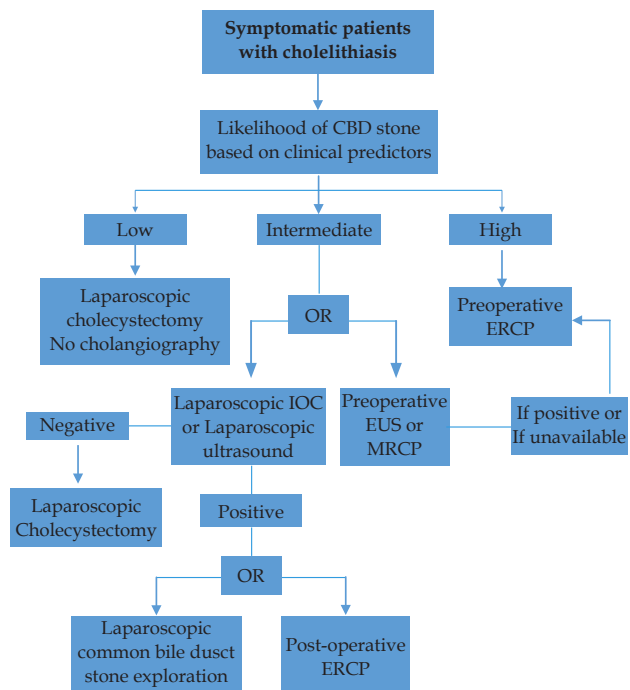


Figure 1 Probability of choledocholithiasis according to predictor factors.

risk of further pancreatic damage.

By contrast, in 50% of patients allocated in the high-risk group based on clinical parameters, CBD stones were not found by EUS, thus avoiding unnecessary ERCP.

Some reports showed a superiority of EUS for small stones and biliary sludge, especially if the bile duct is not dilated^[30].

In particular, EUS has emerged as an accurate diagnostic tool, as demonstrated by the results of a recent meta-analysis^[53]. Moreover the use of EUS significantly reduces the risk of overall complications of interventional ERCP; by performing EUS first, ERCP may be safely avoided in two-thirds of patients with suspected CBD stones^[40].

DIAGNOSIS OF CHOLEDOCHOLITHIASIS AFTER CHOLECYSTECTOMY

CBD stone after cholecystectomy can occur from either migrated gallbladder stone or not detected in the perioperative period or less commonly a stone forming de novo in the CBD.

The diagnosis of choledocholithiasis in patients with previous cholecystectomy are slightly different. Although clinical presentation could be similar alternative diagnosis should be considered such as bile leak, iatrogenic biliary stricture and biliary-type sphincter of Oddi dysfunction.

In fact additional diagnostic possibilities to consider in these patients are bile leak, biliary stricture and biliary-type sphincter of Oddi dysfunction. Patients with normal liver test and ultrasound scan are very unlikely to have choledocholithiasis^[54]. The incidence of choledocholithiasis after initial evaluation is 33% to 43%^[54,55]. MRCP^[54] and EUS^[55] have been shown to be highly accurate for detecting choledocholithiasis in this subset of patients and preferable approach, given their attenuated morbidity compared with ERCP.

DIAGNOSIS OF CHOLEDOCHOLITHIASIS IN PATIENTS WITH ACUTE BILIARY PANCREATITIS

There are no roles of early ERCP in case of absence of evidence of retained CBD stone in patients with mild acute biliary pancreatitis. In patients with ABP and concomitant cholangitis or biliary obstruction, early ERCP is strongly recommended given the benefit shown in morbidity and mortality^[56].

Data are conflicting as to the benefit of early ERCP in patients with predicted severe ABP without acute cholangitis or biliary obstruction^[57,58]. It is suggested that patients with ABP, being at intermediate risk of choledocholithiasis, should be proposed for pre-operative EUS, MRCP or IOC to rule out CBD stone.

ENDOSCOPIC TREATMENT

Preparation of patients for ERCP

Informed consent: Patients should received detailed informations on risk and benefit to receiving treatment and if appropriate will need to describe the therapeutic alternatives.

Anticoagulation or antiplatelet therapy: Patients who have to undergo ERCP should be performed no more than 72 hours before a full blood count and prothrombin time or international normalised ratio. Patients on anticoagulation should be discontinued prior to ERCP 5 day before and substitute with subcutaneously heparin. The novel oral anticoagulants (NOACs) include the direct thrombin inhibitor dabigatran and the direct factor Xa inhibitors (eg, rivaroxaban [Xarelto], apixaban [Eliquis], and edoxaban [Savaysa]) should be hold, while patients in antiplatelet treatment (APA) need to discontinued treatment for the appropriate drug-specific interval in according to the recent guideline^[59,61]. New class agents of Thienopyridines such as ticagrelor (Brilinta) should be hold 5-7 day before while pasugrel (effient) should be hold 10-14 days before.

A new APA agents that are GPIIb/IIIa inhibitors such as tirofiban (Aggrastat), abciximab (ReoPro) and Eptifibatide (Integrilin) according to their shorter duration of action, should be hold respectively in 1-2 seconds, 24 hours and 4 hours^[61].

Biliary sphincterotomy can be safely performed on patients taking Aspirin or non-steroidal anti-inflammatory drugs. A low dose of heparin should not be considered a contraindication to biliary sphincterotomy^[59,60].

Antibiotic prophylaxis: Routine administration to all patients undergoing to ERCP is considered unnecessary unless cholangitis or immunosuppression is present or biliary drainage is predicted to be incomplete^[62].

Pancreatitis prophylaxis: All patients undergoing to ERCP should be administered prophylactic drugs such as rectal indometha-

cin or diclofenac because of consistently reduced risk of post ERCP pancreatitis according to several meta-analysis and ESGE guideline^[63-65].

Sedation and monitoring: patients should be sedated and monitored with anesthesiology support.

Endoscopic treatment is based on selective biliary cannulation and performing adequate endoscopic sphincterotomy. In case of failed biliary access several reasonable options could be chosen based on several factors including reasons for failure, presence or absence of cholangitis, medical stability and performance status of the patient, whether cholecystectomy is planned, and available expertise.

Both repeated ERCP by the same endoscopist on different days^[66] or referral to a tertiary center with ERCP expertise^[67] have been reported to have higher rates (88-96%) of selective cannulation. Percutaneous approach (PTC) have been used to facilitate ERCP via transpapillary guidewire passage (rendez-vous technique), with ERCP performed either at the time of PTC^[68] or after few days^[69]. Moreover PTC has been used for primary percutaneous biliary drainage after failed ERCP although multiple sessions are required especially if large and multiple stone are found^[70].

More recently EUS-guided biliary puncture have been described after ERCP failure for choledocholithiasis^[71], but safety profile of this technique is still underway and at the present is reserved in tertiary center with expertise in ERCP and EUS. Surgical intervention is appropriate after failed ERCP, in patients without surgical contraindication, particularly if cholecystectomy is required. Surgical options include both open and laparoscopic CBD exploration and laparoscopic rendezvous procedure, during which a guidewire is passed via cystic duct into the duodenum to allow intraoperative ERCP^[72].

If selective biliary access occur, after performing sphincterotomy, a cholangiography can show the presence of a stone (Figure 3) that can be removed with either a balloon catheter (Fogarty) (Figure 4a) or a basket (dormia) (Figure 4b). Although no data directly compare their efficacy for uncomplicated CBD stone; the choice of the better device depends on common bile duct and stone size.

In case of stone size are lower of the diameter of common bile duct I usually prefer baskets because of costs, and also because with baskets the vector forces associated with pulling the basket are aligned through the axis of the stone. While with balloon the stone is located lateral to the pull force vector of the catheter, leading to a lateral component which partially impedes stone extraction.

In case of stone size is greater than diameter of CBD (“difficult stone”) it is better to use mechanical lithotripsy or post-sphincterotomy balloon dilation (PSBD).

There are no data comparing different balloons with regard to ease of use and success rates at stone extraction in either the biliary or pancreatic ducts. There are no data to demonstrate the superiority of one extraction balloons device over the others^[73]. Expert ERCPist use a Dormia basket first, with a balloon used where residual stones remain following a pull through with a Dormia basket, for extraction of small stones, or small fragment following lithotripsy.

Extraction Maneuver

Balloon technique: The balloon is inserted above the stone. If there are several stones, the stone are removed one at time, starting always with stone closest to the papilla. Keep the balloon in line with axis of the bile duct during stone extraction. The catheter and stone are retracted to the most downstream portion of the duct; The catheter is held tightly against the endoscope with the third through fifth fingers of the left hand. Endoscope is in the same time torqued clockwise and pushed downward which directs the catheter and stone straight

out of the duct.

Basket technique: The closed basket is inserted over the stones. If this is difficult guidewire can be placed above the stones and basket inserted over the guidewire. The basket is opened and the stone snared by opening and closing the basket. Sometimes vigorous shaking of the fully open basket inside the bile duct may help to capture the stone into the basket avoiding opening the basket to displace the stone into the intrahepatic ducts. The basket is withdrawn as far as the papilla without closing it aligning the scope with the axis of the CBD. If the stone are very large they may be broken mechanically by the Dormia basket. The technical characteristics and type of extraction balloon and baskets are summarized in table 5-6.

Problem with balloon and possible solutions: Avoid to inflate balloon in a duct much smaller than the balloon diameter, given the risk of ductal trauma or perforation^[74]. Avoid of over-injection contrast material while inflate balloon into the bile duct because can lead to pain during the procedure and the risk of dislocate stone into intrahepatic duct; Use of excessive force to remove the stone can be associated with trauma to the periampullary region, increasing the risk of bleeding, perforation and pancreatitis.

Problem with the Basket and possible solutions: (1) Basket Im-

packed: represent a medical emergency and rescue lithotripsy using specialized accessories designed for this occurrence may be required. There are several endoscopic solutions: first need to withdraw the endoscope gradually maintaining firm traction on the basket so that scope and basket are integral allowing to the stone to pass through the sphincterotomy. Second advance the scope so that the tip is against the papilla. Force the basket into the operating channel. The basket will close, as it is withdrawn into the operating channel crushing the stone. Third the basket should be attached to the lithotripter and stone crushed^[75-79]; (2) Basket mesh rupture: there are two solutions: First try to grasp with a forceps the distal end of the basket to pull out from the papilla. Other options include enlarge the opening with balloon dilation of the papilla and distal part of CBD to allow the extraction of the basket and stone with a forceps^[80]. Approximately 85-90% of common bile duct stones can be removed with standard technique after ES or EPBD.

Difficult biliary stone

Approximately 10-15% of biliary stone are difficult to extract. Factors influencing the technical difficulty of endoscopic clearance of CBD have been described and are reported in table 7. Furthermore

Table 5 Types and characteristics of stone extraction balloon *technology Status evaluation Report review ASGE guideline GIE biliary and pancreatic stone extraction device GIE 2009; 70 (4): 603-609.

Manufacturer	Product	Balloon inflated OD (mm)	Catheter length (cm)	Injection site [above,below balloon]	Catheter OD (Fr)	Recommended guidewire	Price (\$)
Triple lumen balloons							
Boston scientific	Extractor Rx retrieval	9 12" 12 15" 15 18"	NA	Available above or below	7 taper to 6	0.035	209
	Extractor XL retrieval	8.5, 11.5 and 15	210	Available above or below	7 taper to 5	0.035	159
Conmed Technologies	Duraglide stone removal	8.5, 11.5 and 15	200	Available above or below	7 taper to 5	0.035	176
Cook endoscopy	D.A.S.H Extraction	8.5 12.5"	200	Above	6	0.025	160
	Tri/ex Radiopaque	8.5,12,15"	200	Available above or below	7	0.035	160
	Fusion Quatro Extraction	8.5 10 12 15" and 12/15/18/20"	200	Available above or below	6.6	0.035	199
	Fusion extraction	8.5 12 15"	200	Available above or below	7	0.035	199
	Multi/3 extraction	8.5 11 15	150	Available above or below	5 at tip	0.035	147
	V/system extraction	8.5 11.5 15	190	Available above or below	5.5*at tip	0.035	186
Double/lumen balloons							
Boston Scientific	Extractor rretrieval	8.5 11 and 15"	210	Above	5	0.025	145
Conmed	Duraglide stone retrieval	11.5 15	200	Above	7	0.035	145
	Duraglide Tapered stone retrieval	8.5 11.5 and 15	200	Above	7 taper to 5	0.035	145
Cook endoscopy	Escort II extrction	8.5 12 15"	200	Above	6.8	0.035	150
	Bouncer multi/pth occlusion	15	200	Above	6.8	0.025/0.035	171
Olympus	Extraction balloon	11	195	Above	5	0.035	177
		13	350	Above	7	0.035	177
		13	195	Above	7	0.035	177

Table 6 Types and characteristics of stone extraction baskets.

Manufacturer	Product	Opening width (mm)	Working length (cm)	Minimum channel size (mm)	Price (\$)	Comment
Cook endoscopy	Fusion basket	20	200	4.2	376	Lithotripter compatible
	Web extraction	15,20,25 and 30	220	2.8	194	Compatible with Conquest TTC and Sohendra mechanical lithotripter
	Web II extraction	20	200	3.2	194	Soft wire construction. Not for use with ML.
	Memory basket 5 Fr soft wire	20	200	2	343	Not for use with ML ,soft multifilament wires
	Memory Basket 7 Fr hard wire	20,30	200	2.8	343	Not for use with ML ,hard monofilament
	Memory basket 7 Fr soft	15,20,25	220	2.8	343	Compatible with Conquest TTC and Sohendra lithotripter,multifilament 4 wire basket
	Mini basket	5	200	2	290	Not for use with ML
	Memory basket eight wire	20,30	200	2	343	Not for use with ML,spiral basket configuration
Olympus	Flower Basket	20	195	2.8	237	
	Stiff wire	22	195	2.8	228	
	Soft wire	22	195	2.8	228	

multiple stones (> 10), barrel-shaped stone, proximal CBD stones, Mirizzi syndrome and the presence of distal stricture or primary sclerosing cholangitis (CSP) are also agreed upon by experts to be difficulty of stone extraction^[81-82].

EPBD: A recent International consensus guideline^[83] stated that in the removal of difficult or large CBD stone EPBD can be used as an alternative to EML and could be used as the initial method when large stone have been identified on ERCP or cross sectional imaging and may not increase the risk of pancreatitis as previous described^[84,85].

The two previous meta-analysis did not consider some relevant factors that could explain the reason because EPBD is not a risk factors of PEP:

1. Time of insufflation have been demonstrated as important risk factors of PEP. In fact patients who have a longer time of insufflation (5

minute) had a low risk of PEP compared to patient with shorter time of insulation (less than 1 minute)^[86-87].

2. The anterograde balloon dilation has not demonstrated an increased risk of post-ERCP pancreatitis supporting the hypothesis that the dilation per se is not a risk factors of PEP^[88].

3. Last but not least the increasing use of rectal NSAID has been shown by several meta-analysis to reduce the risk of PEP^[64] and should also be considered.

PBSD: EPBD after ES using a large balloon (12 to 20 mm) was first used in 2003 as technique to treat patients with large bile duct stone or stone above a distal CBD stricture^[89].

A recent met-analysis included 6 RCTs (835 patients) evaluating large balloon dilation (12 mm) treated by EPBD after ES versus ES alone for removal CBD stone 10 mm or larger showed a similar efficacy with stone clearance at first attempt (OR 1.02; $p=0.92$), reduction in need for mechanical lithotripsy (OR 0.26; $p=0.02$), lower risk of complication without differences in rates of post ERCP pancreatitis (OR 0.77, $p = 0.39$)^[90].

Mechanical lithotripsy (ML): since the description by Demling *et al*^[91] in 1982, endoscopic mechanical lithotripsy has been accepted as the most reliable method of crushing difficult bile duct stones. The success rate of ML has been improved in the last year^[92-93] from 89% to 94%.

The reported incidence of complications with ML ranges from 6%

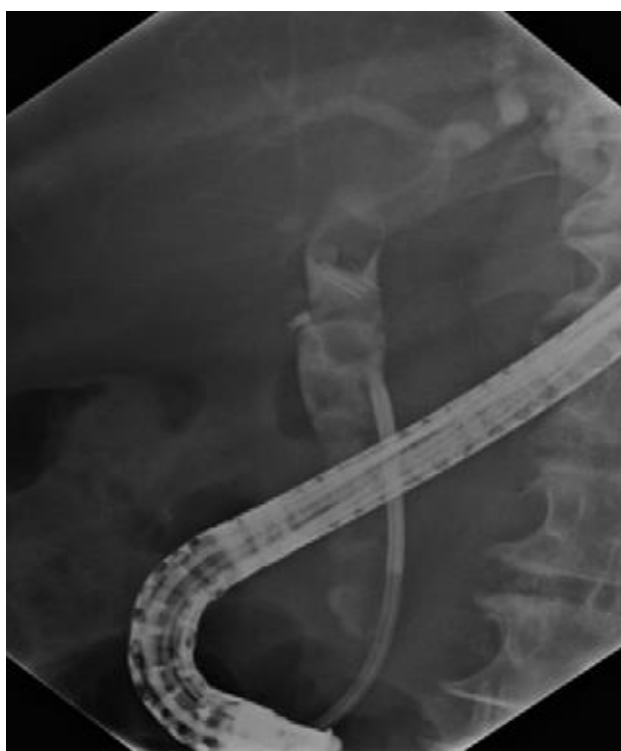

Figure 2 Cholangiography showing choledocholithiasis.

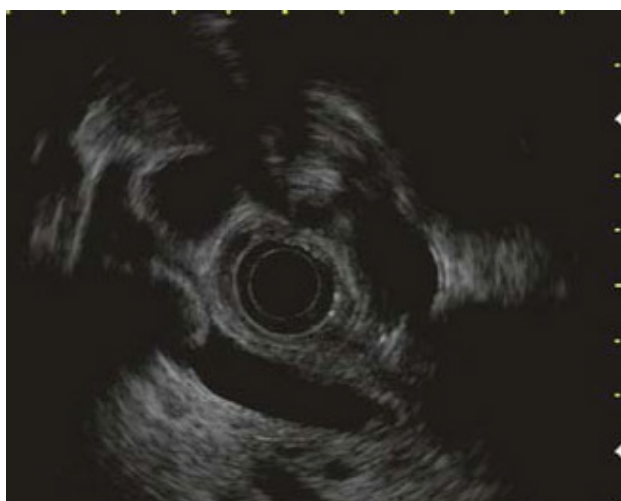

Figure 3 EUS showing choledocholithiasis.

Table 7 Cause of difficult bile duct stone.	
Category	Risk factors
Clinical	Age 65 years. Bleeding tendency. Very poor medical condition.
Anatomic situation	Altered anatomy *Roux/en/Y, gastric bypass, Roux chioleodochoenterostomy. Periampullary diverticulum
Stone characteristics	Stone size > 15 mm. Barrel shaped, elongated. Intrahepatic stones. Multiple stones >10
Bile duct morphology	Angulation of the distal CBD < 135 °. Distal CBD stricture&PSC. Concomitant Mirizzi syndrome

Patients with “difficult to extract stone” may require adjunct technique for stone extraction which are discussed elsewhere in this article.

Table 8 Mechanical lithotriptors. ASGE guideline technical status evolution report Biliary and pancreatic lithotripsy devices GIE 2007,65,6 750.					
Device	Cost initial per use	Assembly required	Contrast njection capability	Working channel	Crush >1 stone
Integrated					
Microvasive					
Boston scientific					
Monolith	399 \$	No	Yes	3.2	Yes
Trapezoid	779\$/ \$329	Yes	Yes	3.2	Yes
Alliance II handle	450\$	No	NA	NA	NA
Olympus America					
BML /3Q	1442\$/50\$	Yes	Yes	4.2	Yes
BML/4Q	1442\$/50\$	Yes	No	3.2	Yes
BML/201Q	879\$/383\$	Yes	Yes	4.2	Yes
BML/202Q/204Q	879\$/383\$	yes	No	3.2	Yes
Salvage					
Olympus					
BML/110 A1	403\$/64\$	Yes	No	3.2/4.2	No
MAJ 403*sheath	64\$	Yes	No	Remove scope	No