

## Difficult Manipulation is One of the Risk Factors for Incomplete Resection in Colorectal Endoscopic Submucosal Dissection

Naohisa Yoshida, Nilesh Fernandopulle, Takaaki Murakami, Ryohei Hirose, Kiyoshi Ogiso, Yutaka Inada, Osamu Dohi, Tetsuya Okayama, Kazuhiro Kamada, Kazuhiko Uchiyama, Takeshi Ishikawa, Osamu Handa, Hideyuki Konishi, Yuji Naito, Akio Yanagisawa, Yoshito Itoh

Naohisa Yoshida, Nilesh Fernandopulle, Takaaki Murakami, Ryohei Hirose, Kiyoshi Ogiso, Yutaka Inada, Osamu Dohi, Tetsuya Okayama, Kazuhiro Kamada, Kazuhiko Uchiyama, Takeshi Ishikawa, Osamu Handa, Hideyuki Konishi, Yuji Naito, Yoshito Itoh, Department of Molecular Gastroenterology and Hepatology, Kyoto Prefectural University of Medicine, Graduate School of Medical Science, Kyoto, Japan

Akio Yanagisawa, Department of Surgical Pathology, Kyoto Prefectural University of Medicine, Graduate School of Medical Science, Kyoto, Japan

Correspondence to: Naohisa Yoshida, MD, PhD, Department of Molecular Gastroenterology and Hepatology, Kyoto Prefectural University of Medicine, Graduate School of Medical Science, 465 Kajicho, Kawaramachi-Hirokoji, Kamigyo-ku, Kyoto 602-8566, Japan.

Email: [naohisa@koto.kpu-m.ac.jp](mailto:naohisa@koto.kpu-m.ac.jp)

Telephone: +81-75-251-5519

Fax: +81-75-251-0710

Received: April 27, 2016

Revised: May 26, 2016

Accepted: May 28, 2016

Published online: June 21, 2016

### ABSTRACT

**AIM:** Colorectal endoscopic submucosal dissection (ESD) remains a difficult procedure, even for experts. Difficult manipulation during procedure is one of the most important problems in colorectal ESD. In this study, we analyzed the risk factors for incomplete resection in colorectal ESD, focusing on difficult manipulation.

**MATERIALS AND METHODS:** We retrospectively analyzed 405 consecutive tumors for which ESD was performed at the Kyoto Prefectural University of Medicine from 2010 to 2013 by a single expert endoscopist with extensive ESD experiences. The relationship between incomplete resection and clinicopathological factors were examined. Additionally, multivariate analysis was performed to examine risk factors of difficult manipulation.

**RESULTS:** The rate of incomplete resection was 3.2%. The rates of

severe fibrosis, difficult manipulation, and perforation were 10.8%, 23.5%, and 2.7%, respectively. Multivariate analyses showed that severe fibrosis (OR: 26.395, 95% CI: 6.587-105.764,  $p < 0.001$ ), difficult manipulation (OR: 4.575, 95% CI: 1.200-17.436,  $p = 0.026$ ), and tumor size  $\geq 50$  mm (OR: 4.452, 95% CI: 1.061-18.688), were significantly related with incomplete en bloc resection. Multivariate analyses showed that right-sided colon (OR: 9.762, 95% CI: 2.119-44.972,  $p = 0.003$ ), left-sided colon (OR: 8.834, 95% CI: 1.788-43.643,  $p = 0.008$ ), severe breathing movement (OR: 2.648, 95% CI: 1.371-5.116,  $p = 0.004$ ), insertion time (per 1min) (OR: 1.094, 95% CI: 1.016-1.179,  $p = 0.018$ ), and procedure time (OR: 0.004, 95% CI: 0.000-0.437,  $p = 0.022$ ) were significantly related with difficult manipulation.

**CONCLUSION:** Severe fibrosis, difficult manipulation, and tumor size  $\geq 50$  mm were related with incomplete resection for colorectal ESD even in expert hands.

**Key words:** Difficult manipulation; ESD; Colorectal polyp

© 2016 The Authors. Published by ACT Publishing Group Ltd.

Yoshida N, Fernandopulle N, Murakami T, Hirose R, Ogiso K, Inada Y, Dohi O, Okayama T, Kamada K, Uchiyama K, Ishikawa T, Handa O, Konishi H, Naito Y, Yanagisawa A, Itoh Y. Difficult Manipulation is One of the Risk Factors for Incomplete Resection in Colorectal Endoscopic Submucosal Dissection. *Journal of Gastroenterology and Hepatology Research* 2016; 5(3): 2070-2076 Available from: URL: <http://www.ghrnet.org/index.php/joghr/article/view/1698>

### INTRODUCTION

In Japan, endoscopic submucosal dissection (ESD) is fast becoming the standard therapy for early gastrointestinal cancers<sup>[1-6]</sup>. During the last few years, ESD has been adopted as a minimally invasive and organ sparing technique by the rest of the world. Thus, with the globalization of ESD and rapid development of its techniques, the level of difficulty of this procedure has been further highlighted. The thinness

of the colonic wall leads to more perforations, which has been one of the difficulties encountered by most endoscopists during colonic ESD. Thus, together with the duodenal ESD, the colorectal ESD has been the most challenging of all gastrointestinal ESDs. There are other factors attributed to this perceived difficulty. The location, size of the lesion, and degree of fibrosis has been previously identified as risk factors for incomplete resection and perforation of colorectal ESD<sup>[7-10]</sup>. Since these risk factors made ESD difficult to perform, only experts conducted the procedure in the early years. Recently, most of these challenges have been resolved by improving on existing devices, utilizing suitable strategies, and learning from the operators' experiences<sup>[6,9]</sup>. Thus, in many institutions where ESD is performed, the rates of en bloc resection have increased and perforation rates have decreased. However, even when performed by experts, the rate of en bloc resection is not optimal. We believe this is due to the persistence of certain issues such as difficulties in manipulation during colorectal ESD. Difficult manipulation occurs due to the long and winding nature of the colon. This remains one of the unresolved risk factors, which causes unintentional movement of the knife and the risk of perforation. To our knowledge, there are no previous reports on the difficulties of colorectal ESDs as performed by experienced experts. In this study, we analyzed the clinicopathological factors which are related to the incomplete resection of the lesion by the experts, focusing on difficult manipulation.

## PATIENTS AND METHODS

This was a single center retrospective study involving 405 consecutive tumors for which, ESD was performed at the Kyoto Prefectural University of Medicine from 2010 to 2013. The indications for ESD included (1) tumors that could not be resected with endoscopic mucosal resection (EMR), as well as those that were diagnosed as (2) intramucosal cancer (Tis) and part of T1 cancer without risk of lymph node metastasis by magnifying endoscopic examination such as pit pattern observation, narrow band imaging (NBI), flexible spectral imaging color enhancement (FICE), and blue laser imaging (BLI)<sup>[3,11-13]</sup>. We excluded (1) patients who had other diseases precluding ESD, and (2) those who did not provide their consent for ESD. A single expert endoscopist (Yoshida N) who had performed more than 200 colorectal ESDs performed the procedure for all the patients in this study. By reviewing medical records, we analyzed the clinicopathological factors and outcomes including age, sex, tumor size, location, morphology, difficult manipulation, severe breathing movement, severe fibrosis, procedure time, the rate of en bloc resection, discontinuance of procedure, histological diagnosis, and complications (perforation and postoperative hemorrhage) in all ESD cases. The discontinuance was defined as a case in which ESD was stopped because of various difficulties (severe fibrosis, perforation and specially difficult manipulation) and a tumor was not resected.

Additionally, we analyzed the rate of use of double balloon endoscopy (DBE) (Fujifilm Medical Co., Tokyo, Japan), which we used for the cases in that we could not perform ESD with a standard endoscope due to specially difficult manipulation during a pre-check colonoscopy. We assigned all patients into either the successful or incomplete en bloc resection group and examined predictive factors for incomplete resection using univariate analysis and multivariate analysis. With respect to the definition of several factors, difficult manipulation was defined as unsmooth and unintended movement of the endoscope during the procedure. It meant persistent paradoxical movement over a given distance, or a given number of turns. Difficult manipulation was evaluated during ESD by a single expert operator

(Yoshida N). Severe breathing movement was defined as the troublesome movement of the endoscopic view, which was synchronous with the patient's breathing and evaluated during ESD by the operator. The evaluations for difficult manipulation and severe breathing movement were performed by the operator in all ESD cases in our institution since 2010. For an objective evaluation of these two factors, an assistant doctor with experience in more than 50 colorectal ESD cases, retrospectively evaluated for difficult manipulation and severe breathing movement by only using recorded videos of the all the ESD cases. The assistant doctor was blinded to the results of the operator's evaluation about difficult manipulation and severe breathing movement. The inter-observer agreement of these two factors between the operator and the assistant doctor were analyzed. Additionally, the assistant doctor evaluated these two factors 2-3 weeks after a first evaluation, and the intra-observer agreement between the first and second evaluation was examined. For further analyses, all cases were divided into two groups as either difficult or good manipulation, according to the evaluation by the operator. The relationships between difficult manipulation and the various clinical characteristics, including insertion time, were examined using univariate analysis and multivariate analysis. On the other hand, the characteristics of the cases using DBE due to difficult manipulation that was detected in a pre-check colonoscopy were analyzed.

With regard to the morphology, polyps were divided into polypoid lesions and non-polypoid lesions in accordance with the Paris classification. Non-polypoid lesions included elevated, flat, and depressed types<sup>[14]</sup>. The location of the tumor was identified according to the three segments, the right-sided colon (from the cecum to the transverse colon), the left-sided colon (from the descending to the sigmoid colon), and the rectum. Though the expert operator (Yoshida N.) performed the colonoscopies and ESDs of all cases, a non-expert endoscopist performed a small component of the procedure under the supervision and assistance of the expert endoscopist in some cases. Thus, they performed insertion of the endoscope to the desired location and 5-10 minutes dissection procedure. The insertion time was calculated during the colonoscopy pre-check in most cases and it was calculated on the ESD day in some cases. The procedure speed was calculated according to a previously reported method<sup>[9]</sup> by dividing the procedure time by the area of the resected specimen (cm<sup>2</sup>/min). Briefly, the area of resected specimen was calculated as follows:  $3.14 \times 0.25 \times \text{long axis} \times \text{minor axis}$ . Severe fibrosis was defined as the appearance of a white muscle-like structure without a blue transparent layer in the submucosal layers<sup>[15]</sup>. Perforation was detected by endoscopy during the ESD procedure or by abdominal computed tomography after ESD. Postoperative hemorrhage was defined as the occurrence of hematochezia that required endoscopic treatment to stop the bleeding<sup>[2,3]</sup>. Histological diagnosis was performed by a clinical pathologist (A.Y.) according to the classification by the World Health Organization and Japanese classification of Colorectal Carcinoma proposed by Japanese Society for Cancer of the Colon and Rectum<sup>[16,17]</sup>. All tumors were classified as an adenoma, Tis, or T1 cancer. Cases of mild and moderate dysplasia were diagnosed as adenomas, and severe and high-grade dysplasia was diagnosed as Tis. All patients provided written informed consent to undergo ESD. The ethics committees of the Kyoto Prefectural University of Medicine approved this study. This study was carried out in accordance with the World Medical Association Helsinki Declaration and was one of sub-group analysis of the study registered in the University Hospital Medical Information Network Clinical Trials Registry (UMIN-CTR) as number UMIN000013772.

## ESD PROCEDURE

We performed a pre-check colonoscopy before ESD in order to confirm the accuracy of the diagnosis and determine the status of manipulation. For cases with severely difficult manipulation, DBE was used in ESD. Our routine ESD procedure was performed with a short-tipped ESD knife such as the Flush knife BT (Fujifilm Medical Co., Tokyo, Japan)<sup>[4]</sup>. The Clutch cutter (Fujifilm Medical Co., Tokyo, Japan), a grasping scissor knife, was also used in difficult situations<sup>[18]</sup>. A lower gastrointestinal endoscope with a single channel (EC-590MP; Fujifilm Medical Co., Tokyo, Japan) was used. The injection solution was prepared with 0.4% hyaluronic acid solution (Mucoup; Johnson & Johnson, Tokyo, Japan or Seikagaku Corporation, Tokyo, Japan) including a small amount of 0.2% indigocarmine (final concentration: 0.06% indigocarmine)<sup>[19]</sup>. Mucosal injection to elevate the submucosa was administered with a 25-gauge needle (TOP Co., Tokyo, Japan). The VIO300D high-frequency generator (ErbeElektromedizin, Tübingen, Germany) and CO<sub>2</sub> insufflation were also used<sup>[20]</sup>. Conscious sedation was performed with midazolam and pentazocine; monitoring was done using an automatic blood pressure monitor. If severe breathing movement was too much in conscious sedation, this was discontinued in exceptional cases. The ESD procedure was performed as reported previously<sup>[6]</sup>. First, injection for submucosal elevation was administered with a 25-gauge needle before mucosal incisions were made (Figure 1). A partial circumferential incision was made using a Flush knife BT on the distal (anal) side of the tumor. After the mucosal incision, the submucosa below the tumor was dissected from the distal side of the tumor. When difficult manipulation and severe breathing movement were seen during the procedure, we preferred to use the Clutch cutter for safe purposes. Additionally, dissection was performed carefully in order to avoid perforation and hemorrhage until en bloc resection of the tumor was completed.

## STATISTICAL ANALYSIS

Statistical analyses were performed using the Mann-Whitney U and the chi-square tests (SPSS version 22.0 for windows, IBM Japan, Ltd., Tokyo, Japan). With respect to tumor size, colorectal ESD was accepted for a tumor 20–50 mm in size in Japanese health insurance a few years ago. Thus, we divided this continuous variable (tumor size) into < 50 mm and ≥ 50 mm. Multivariate logistic regression analyses of the incomplete resection and the difficult manipulation were performed for risk factors with a P-value 0.1 in univariate analysis. A P-value of < 0.05 was considered statistically significant.

## RESULTS

The overall therapeutic results of all ESD cases are given in Table 1. Mean age of the group was 67.9 ± 10.7 years old and 207 were male (51.1%). Two-hundred three (50.1%), 82 (20.2%), and 120 (29.6%) tumors were located in the right-sided colon, left-sided colon and rectum, respectively. While the mean tumor size was 33.1 ± 14.3 mm, 347 (85.6%) were non-polypoid tumors. The rate of use of double balloon endoscopy was 1.7%. Difficult manipulation and severe breathing movement were seen in 23.5% and 35.8% cases, respectively. The rate of en bloc resection was 96.8% (392/405). The discontinuance rate was 1.7% (7/405) and those lesions were resected by surgical operation afterwards. Five cases were due to severe fibrosis and perforation occurred in 2 of these 5 cases. The

remaining 2 cases were discontinued due to difficult manipulation. Histologically, there were 180 (44.7%), 166 (41.0%), and 58 (14.3%) cases of adenomas, Tis, and T1 cancers, respectively. Perforation rate was 2.7% (11/405).

Clinical factors associated with incomplete en bloc resection are shown in Table 2. Tumor size ≥ 50 mm ( $P = 0.02$ ), severe fibrosis ( $P < 0.001$ ), and difficult manipulation ( $P = 0.003$ ) were significantly associated with incomplete en bloc resection. Multivariate analyses showed that severe fibrosis (OR: 26.395, 95% CI: 6.587–105.764,  $p < 0.001$ ), difficult manipulation (OR: 4.575, 95% CI: 1.200–17.436,  $p = 0.026$ ), and tumor size ≥ 50 mm (OR: 4.452, 95% CI: 1.061–18.688), were significantly related with incomplete en bloc resection (Table 3). With the objective evaluation of difficult manipulation and severe breathing movement, the inter-observer agreement rates of these two factors between an operator and an assistant were 79.8% and 84.9%, respectively (Table 4). Additionally, the intra-observer agreement rates of these two factors by an assistant between the first evaluation and second evaluation were 76.5% (310/405) and 86.6% (351/405), respectively.

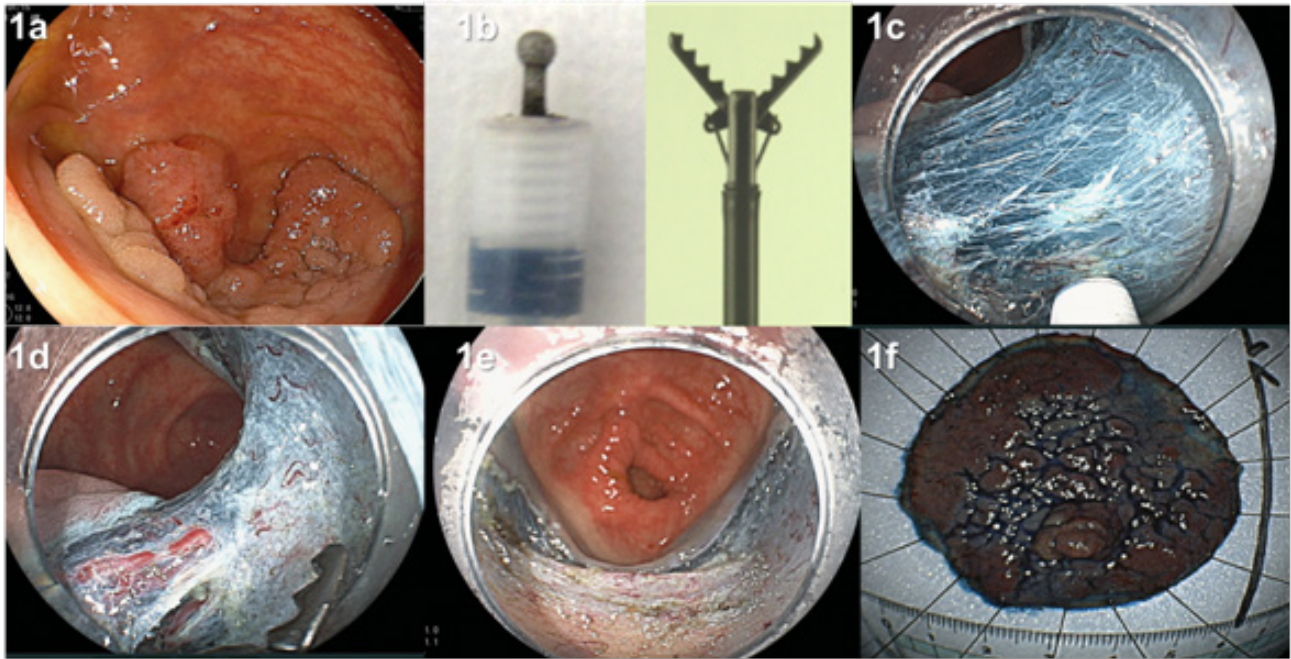
The comparison between the difficult and good manipulation groups are shown in Table 5. With respect to predictive factors of difficult manipulation, the rates of right-sided colon tumors in the difficult manipulation group (70.5%, 67/95) were significantly higher compared to the good manipulation group (43.9%, 136/310,  $p < 0.001$ ). Insertion time in the difficult manipulation group ( $9.0 \pm 3.5$ ) was significantly longer than that in the good manipulation group ( $7.8 \pm 4.2$ ,  $p = 0.03$ ). With respect to therapeutic results, the rate of severe breathing movement was significantly higher in the difficult manipulation group compared to the good manipulation group (60.0% vs 28.4%,  $p < 0.001$ ). There were also significant differences between the difficult and good manipulation groups in terms of the procedure speed ( $0.11 \pm 0.07$  vs  $0.13 \pm 0.17$  cm<sup>2</sup>/min,  $p = 0.003$ ), rate of discontinuation (7.3% vs 0%,  $p < 0.001$ ), and en bloc dissection (91.5% vs 97.4%,  $p = 0.003$ ) (Figure 2). On the other hand, there were no significant differences in complication rates between the two groups (perforation: 2.1% vs 2.9%; postoperative hemorrhage: 3.2% vs 1.9%). Multivariate analyses showed that right-sided colon (OR: 9.762, 95% CI: 2.119–44.972,  $p = 0.003$ ), left-sided colon (OR: 8.834, 95% CI: 1.788–43.643,  $p = 0.008$ ), severe breathing movement (OR: 2.648, 95% CI: 1.371–5.116,  $p = 0.004$ ), insertion time (per 1min) (OR: 1.094, 95% CI: 1.016–1.179,  $p = 0.018$ ), and procedure time (OR: 0.004, 95% CI: 0.000–0.437,  $p = 0.022$ ) were significantly related with difficult manipulation (Table 6).

**Table 1** Overall therapeutic results of 405 colorectal ESDs.

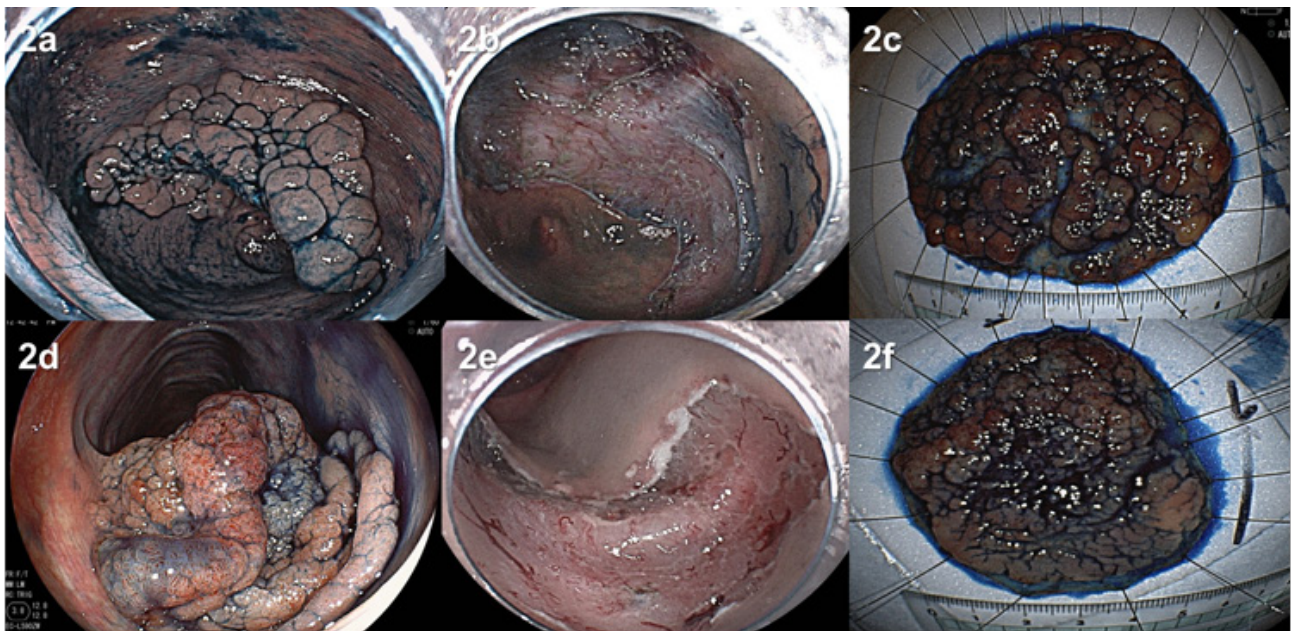
Case number	405
Age, mean ± SD	67.9 ± 10.7
Sex, Male/Female, % (n)	51.1(207)/48.9(198)
Tumor size, mm, mean ± SD	33.1 ± 14.3
Right-sided/Left-sided/Rectum, % (n)	50.1(203)/20.2(82)/29.6(120)
Non-polypoid/Polypoid, % (n)	85.6(347)/14.4(58)
Use of double balloon endoscopy, % (n)	1.7(7)
Difficult manipulation, % (n)	23.5(95)
Severe breathing movement, % (n)	35.8(145)
Severe fibrosis, % (n)	10.8(44)
Procedure time, minutes, mean ± SD (range)	84.1 ± 52.5(10–420)
En bloc resection, % (n)	96.8(392)
Discontinuance, % (n)	1.7(7)
Histological diagnosis, % (n) Ad/Tis/T1	44.7(181)/41.0(166)/14.3(58)
Perforation, % (n)	2.7(11)
Postoperative hemorrhage, % (n)	3.0(9)

Right-sided: Cecum to transverse colon; Left-sided: Descending colon to sigmoid colon; Ad: adenoma.





**Figure 1** Strategy for colorectal endoscopic submucosal dissection. a. Colonic tumor, 50 mm, non-polypoid, located in the transverse colon; b. Flush knife BT (Fujifilm) was used primarily and Clutch cutter (Fujifilm) was used secondarily for difficult manipulation; c. Submucosa became blue after injection of dense blue hyaluronic acid solution, which helped in the identification of the submucosa and enabled safe dissection; d. Clutch cutter was used to dissect thick vessels; e. The ulceration after resection; f. An en bloc resected specimen. Histological diagnosis showed intramucosal cancer with negative margins.



**Figure 2** Case presentations of colorectal ESD with or without difficult manipulation. a. A non-polypoid colonic tumor 60 mm in diameter on the cecum with difficult manipulation; b. ESD was performed and the procedure time was 150 minutes. The procedure speed was 0.18 cm<sup>2</sup>/min. Histological diagnosis showed intramucosal cancer; d. A non-polypoid colonic tumor 60 mm in diameter on the sigmoid colon without difficult manipulation; e. ESD was performed and the procedure time was 60 minutes. The procedure speed was 0.47 cm<sup>2</sup>/min; f. An en bloc resected specimen. Histological diagnosis showed intramucosal cancer.

**Table 2** Comparison of the clinical factors associated with successful and incomplete en bloc resections.

	Successful en bloc resection	Incomplete en bloc resection	P value
Case number, n, (%)	392 (96.8)	13 (3.2)	
Age, mean ± SD	67.6 ± 10.4	72.8 ± 13.9	0.08
Gender Male/Female, %, (n)	57.9(227)/42.1(165)	76.9(10)/23.1(3)	0.17
Tumor size ≥ 50 mm, %, (n)	12.7(50)	38.4(5)	0.02
Morphology, %, (n) Non-polypoid/Polypoid	85.7(336)/14.3(56)	84.6(11)/15.4(2)	0.91
Tumor location, %, (n) Right-sided/Left-sided/Rectum	49.7(195)/20.7(81)/29.6(116)	61.5(8)/7.7(1)/30.8(4)	0.40
Severe fibrosis, %, (n)	8.6(34)	76.9(10)	< 0.001
Difficult manipulation, %, (n)	22.1(87)	61.5(8)	0.003
Severe breathing movement, %, (n)	35.7(140)	38.4(5)	0.83
Histological diagnosis, %, (n) Ad/Tis/T1	45.4(178)/40.8(160)/13.8(54)	23.1(3)/46.2(6)/30.7(4)	0.11

Right-sided: Cecum to transverse colon; Left-sided: Descending colon to sigmoid colon; Ad: adenoma.

**Table 3** Multivariate analysis of risk factors for incomplete resection of colorectal ESD.

	OR	95% CI	P value
Age	1.057	0.985 - 1.135	0.123
Tumor size, $\geq 50$ mm	4.452	1.061 - 8.688	0.041
Severe fibrosis	26.395	6.587 - 105.764	<0.001
Difficult manipulation	4.575	1.200 - 17.436	0.026

Right-sided: Cecum to transverse colon; Left-sided: Descending colon to sigmoid colon; Ad: adenoma.

**Table 4** Comparison of the inter-observer and intra-observer agreements for difficult manipulation and severe breathing movement.

	Operator	Assistant	Inter-observer agreement between an operator and assistant	Intra-observer agreement of an assistant
Difficult manipulation, %, (n)	23.5(95)	35.7(140)	79.8(323)	76.5(310)
Severe breathing movement, %, (n)	35.8(145)	29.6(120)	84.9(344)	86.6(351)

**Table 5** Comparison of the characteristics and therapeutic outcomes of difficult and good manipulation .

	Difficult Manipulation	Good Manipulation	P value
Case number, %, (n)	23.5 (95)	76.5(310)	
<b>Predictive factors</b>			
Age, mean $\pm$ SD	69.3 $\pm$ 9.5	67.3 $\pm$ 10.9	0.12
Gender, %, (n) Male/Female	62.1 (59)/37.9 (36)	57.4 (178)/42.6 (132)	0.41
Tumor size, mm, mean $\pm$ SD	32.2 $\pm$ 11.3	33.4 $\pm$ 15.0	0.65
Morphology, %, (n) Non-polypoid/Polypoid	90.6 (86)/9.4 (9)	84.2 (261)/15.8 (49)	0.12
Tumor location, % (n) Right-sided/Left-sided/Rectum	70.5 (67)/22.1 (21)/7.4 (7)	43.9 (136)/19.7 (61)/36.4 (113)	< 0.001
Insertion time (min)	9.0 $\pm$ 3.5	7.8 $\pm$ 4.2	0.03
Insertion time $\geq 10$ min, %, (n)	48.4 (46)	23.9 (74)	< 0.001
<b>Therapeutic results</b>			
Severe breathing movement %, (n)	61.0 (47/77)	22.4 (53/192)	< 0.001
Procedure speed (cm <sup>2</sup> /min)	0.11 $\pm$ 0.07	0.13 $\pm$ 0.17	0.003
Discontinuance, %, (n)	7.3 (7)	0 (0)	< 0.001
Procedure time (min)	89.5 $\pm$ 47.1	82.6 $\pm$ 54.0	0.56
En bloc resection, %, (n)	91.5 (87)	97.4 (305)	0.003
Histological diagnosis, %, (n) Ad/Tis/T1	49.5 (47)/31.6 (30)/17.9 (17)	42.9 (133)/43.9 (136)/13.2 (41)	0.22
Perforation, %, (n)	2.1 (2)	2.9 (9)	0.67
Postoperative hemorrhage, %, (n)	3.2 (3)	1.9 (6)	0.47

Right-sided: Cecum to transverse colon; Left-sided: descending colon to sigmoid colon; Ad: adenoma.

**Table 7** The characteristics of the cases using double balloon endoscopy.

	Age	Sex	Insertion time (min)	Location	Size (mm)	Morphology	Difficult manipulation	Severe breathing movement	Severe fibrosis	Perforation	Procedure time (min)
1	72	F	12	T	20	Non-polypoid	+	+	+	-	Dis
2	79	F	12	A	18	Non-polypoid	+	+	+	-	85
3	64	M	11	T	20	Polypoid	+	-	-	-	87
4	73	F	4	A	20	Non-polypoid	-	-	+	-	127
5	69	M	15	A	10	Non-polypoid	+	-	-	-	118
6	68	M	15	C	20	Non-polypoid	+	-	+	-	Dis
7	79	F	6	A	30	Non-polypoid	-	-	+	-	58

T: Transverse colon; A: Ascending colon; C: Cecum; Dis: Discontinuance; Ad: Adenoma.

The characteristics of cases using double balloon endoscopy are shown in Table 7. All tumors were on the right-sided colon. Two tumors that were less than 20 mm in size were included and those cases recurred after EMR. ESD succeeded in 5 out of 7 cases due to the use of double balloon endoscopy. Conversely, difficult manipulation persisted in 5 cases and ESD was discontinued in 2 cases due to difficult manipulation.

## DISCUSSION

Difficulties of ESD result in incomplete en bloc resection and perforation in colorectal ESD<sup>[6-10]</sup>. It is therefore important to predict difficult cases. One study reported that right-sided colon

**Table 6** Multivariate analysis of risk factors for difficult manipulation of colorectal ESD.

	OR	95% CI	P value
<b>Tumor location</b>			
Right-sided	9.762	2.119 - 44.972	0.003
Left-sided	8.834	1.788 - 43.643	0.008
Rectum	1.000	ref.	
Insertion time	1.094	1.016 - 1.179	0.018
Severe breathing movement	2.648	1.371 - 5.116	0.004
Discontinuance	n.c.		
Procedure speed	0.004	0.000 - 0.437	0.022
En bloc resection	0.381	0.031 - 4.694	0.452

OR: Odds ratio; CI: confidence interval; ref: reference, n.c.: not calculated.

tumors and fibrosis were significantly associated with incomplete en bloc resection<sup>[20]</sup>. Another study reported that poor endoscopic operability and deep submucosal invasion were significantly related to incomplete en bloc resection<sup>[21]</sup>. Similar to these reports, our present study showed that severe fibrosis and difficult manipulation were related to incomplete resection. Additionally, in our study, tumor sizes  $\geq 50$ mm were also related to incomplete resection. We consider two reasons for this occurrence. First, large tumors need a more complicated strategy. Second, ESD for a large tumor has more complications such as perforation and perioperative hemorrhage than that for tumors that are less than 50 mm in size<sup>[5]</sup>. Tumors  $\geq 50$  mm in size are considered difficult and technically challenging to dissect, especially for a less experienced endoscopist. Thus, a suitable



strategy and considerable expertise should be considered when performing ESD for large tumors.

When considering perforation during ESD, tumor size  $\geq 50$  mm was also reported as a risk factor for complications including perforation<sup>[5]</sup>. Factors such as large tumor size, laterally spreading tumors, tumor location (right-sided colon), submucosal injection without hyaluronic acid, severe fibrosis, and deep-submucosally invasive cancer were associated with a higher rate of perforation in other studies<sup>[8,10,20,21]</sup>. On the other hand, poor endoscopic operability was also reported to be related with perforation<sup>[22]</sup>. However, our study showed that difficult manipulation was not related with perforation during ESD. We believe this was due to the fact that in our study, ESDs were performed by the expert endoscopist with extensive experience of performing more than 200 colorectal ESDs, prompting safer dissection. Thus, less experienced endoscopists especially should be careful of perforation due to difficult manipulation.

Commonly, endoscopic operability in colorectal ESD is due to many factors such as the operator's skill, breathing movement, heartbeat, and adhesion in the colorectum. Only one study reported detail analysis of poor endoscopic operability<sup>[22]</sup>. It defined poor endoscopic operability as the paradoxical movement of the endoscope, poor control for adhesion, and lesion movement with each heartbeat or breathing. Thus, the rate of poor endoscopic operability was reported as 45.3%. In this study, we defined "difficult manipulation" as the unsmooth paradoxical to intended movement of the endoscope. Additionally, severe breathing movement was separated from difficult manipulation and analyzed independently. Thus, we calculated both rates of difficult manipulation (23.5%) and severe breathing movement (35.8%) and studied their effect on incomplete resection. Our study showed that incomplete resection was affected not by severe breathing movement but by difficult manipulation. This may be caused due to an original strategy that we used during ESD. Because we used a scissor type knife during severe breathing movement as it enabled safe dissection in this situation. As mentioned previously, we also think the endoscopist's experience of performing more than 200 previous ESDs helped in difficult situations. Conversely, difficult manipulation remains a big challenge during colorectal ESD, even in experts' hands.

However, the evaluation of difficult manipulation and severe breathing movement were not objective and were subjectively evaluated by the operator. Thus, we performed an objective evaluation using videos recorded by an assistant. The inter-observer agreement rates of difficult manipulation and severe breathing movement between the operator and an assistant were 79.8% and 84.9%, respectively. The intra-observer agreement rates for an assistant were also 76.5% and 86.6%, respectively. This showed that most cases of difficult manipulation and severe breathing movement could be evaluated objectively.

It is customary to perform a pre-check colonoscopy for the target lesion before ESD. During this assessment, the difficulty of insertion, patient discomfort or pain, location, breathing movement, tumor size, and surface characteristics are observed and assessed. A further important aspect for assessment is the manipulation of the endoscope at the lesion. In this study, we revealed that discontinuance of ESD were significantly associated with difficult manipulation ( $P < 0.001$ ). Thus, difficult manipulation should be examined before ESD in order to prevent discontinuance of ESD. With respect to predictors of poor manipulation, tumor locations at the right-sided colon and on a flexure were reported to be associated with difficult operability<sup>[22]</sup>. Our study showed that the right-sided colon, the left-sided colon,

longer insertion time, severe breathing movement, and low procedure time were significantly associated with difficult manipulation. To our knowledge, this is the first report of detail predictive factors being shown to be associated with difficult manipulation. Hence, these findings will enable us to predict and make an assessment of difficult manipulation. DBE is reported to be useful not only for observation of the small intestine, but also for the evaluation of ESD cases with poor manipulation especially at the right-sided colon<sup>[23,24]</sup>. In this study, we used DBE for cases with severely difficult manipulation. The use of DBE enabled us to perform ESD successfully in 5 out of 7 cases with severe difficult manipulation. The scissor type knife, which gives more stability during the dissection, should also be used if difficult manipulation is predicted<sup>[16]</sup>. Carbon dioxide gas is known to be absorbed in the tissues faster than atmospheric air and is used to prevent patient discomfort by air insufflation during ESD<sup>[20]</sup>. We also suggest using carbon dioxide gas for air insufflations to minimize the difficulty of manipulation. However, in spite of all devices described above, we did not achieve complete resection for some cases with difficult manipulation. Therefore, for specific cases, surgical options should be considered before ESD, according to the degree of difficult manipulation, endoscopist's experiences, and availability of specific devices. Additionally, new devices and strategies need to be developed for further improvement of outcomes in colorectal ESD.

A limitation of this study was the small sample size of incomplete cases although multivariate analysis identified 3 risk factors. Additionally, the evaluations of difficult manipulation and severe breathing movement were still subjective because they were performed by only one operator. However, consistent agreements for these two factors between the operator and an assistant were achieved. Various things such as devices and the endoscopist's skill can affect difficult manipulation. Thus, we think the rate of difficult manipulation may be various and increase especially among inexperienced endoscopists. Additionally, the therapeutic results in this study were also from a single expert endoscopist. In addition, the histological diagnosis in the discontinuance cases resulted from the surgical operation.

## CONCLUSION

Our study showed that severe fibrosis, difficult manipulation, and tumor size  $\geq 50$  mm were significant independent predictors of incomplete resection even in experts. Difficult manipulation was related with reduced procedure speed and discontinuance. The right-sided colon tumor and longer insertion times were identified as predictive factors of difficult manipulation.

## ACKNOWLEDGEMENT

We thank all members of the Department of Molecular Gastroenterology and Hepatology, Kyoto Prefectural University of Medicine, for helping with this study.

## CONFLICT OF INTERESTS

Yoshito Itoh is affiliated with AstraZeneca Co., Ltd., Eisai Co., Ltd., Otsuka Pharmaceutical Co., Ltd., MSD K.K., Dainippon Sumitomo Pharma Co., Ltd., Chugai Pharmaceutical Co., Ltd., FUJIFILM Medical Co., Ltd. and Merck Serono Co., Ltd. Yuji Naito received research grants from Otsuka Pharmaceutical Co., Ltd. and Takeda Pharmaceutical Co., Ltd. The other authors have no conflicts of interest to declare. Other than those previously mentioned, the investigators report no other potential sources of conflicts of interest for this study.

## REFERENCES

- 1 Yamamoto H1, Kawata H, Sunada K, Sasaki A, Nakazawa K, Miyata T, Sekine Y, Yano T, Satoh K, Ido K, Sugano K. Successful en-bloc resection of large superficial tumors in the stomach and colon using sodium hyaluronate and small-caliber-tip transparent hood. *Endoscopy* 2003; **35**: 690-4
- 2 Fujishiro M, Yahagi N, Kakushima N, Kodashima S, Muraki Y, Ono S, Yamamichi N, Tateishi A, Oka M, Ogura K, Kawabe T, Ichinose M, Omata M. Outcomes of endoscopic submucosal dissection for colorectal epithelial neoplasms in 200 consecutive cases. *Clin Gastroenterol Hepatol* 2007; **5**: 674-7
- 3 Tanaka S, Oka S, Kaneko I, Hirata M, Mouri R, Kanao H, Yoshida S, Chayama K. Endoscopic submucosal dissection for colorectal neoplasia: possibility of standardization. *Gastrointest Endosc* 2007; **66**: 100-7
- 4 Toyonaga T, Man-I M, Fujita T, Nishino E, Ono W, Morita Y, Sanuki T, Masuda A, Yoshida M, Kutsumi H, Inokuchi H, Azuma T. Endoscopic treatment for early stage colorectal tumors: the comparison between EMR with small incision, simplified ESD, and ESD using the standard flush knife and the ball tipped flush knife. *Acta Chirurgica Iugoslavica* 2010; **57**:41-6
- 5 Saito Y, Uraoka T, Yamaguchi Y, Hotta K, Sakamoto N, Ikematsu H, Fukuzawa M, Kobayashi N, Nasu J, Michida T, Yoshida S, Ikehara H, Otake Y, Nakajima T, Matsuda T, Saito D. A prospective, multicenter study of 1111 colorectal endoscopic submucosal dissections (with video). *Gastrointest Endosc* 2010; **72**: 1217-25
- 6 Yoshida N, Yagi N, Naito Y, Yoshikawa T. Safe procedure in endoscopic submucosal dissection for colorectal tumors focused on preventing complications. *World J Gastroenterol* 2010; **16**: 1688-95
- 7 Yoshida N, Wakabayashi N, Kanemasa K, Sumida Y, Hasegawa D, Inoue K, Morimoto Y, Kashiwa A, Konishi H, Yagi N, Naito Y, Yanagisawa A, Yoshikawa T. Endoscopic submucosal dissection for colorectal tumors: technical difficulties and rate of perforation. *Endoscopy* 2009; **41**: 758-61
- 8 Kim ES, Cho KB, Park KS, Lee KI, Jang BK, Chung WJ, Hwang JS. Factors predictive of perforation during endoscopic submucosal dissection for the treatment of colorectal tumors. *Endoscopy* 2011; **43**: 573-8
- 9 Inada Y, Yoshida N, Kugai M, Kamada K, Katada K, Uchiyama K, Handa O, Takagi T, Konishi H, Yagi N, Naito Y, Wakabayashi N, Yanagisawa A, Itoh Y. Prediction and Treatment of Difficult Cases in Colorectal Endoscopic Submucosal Dissection. *Gastroenterol Res Pract* 2013; **2013**: 523084
- 10 Lee EJ, Lee JB, Choi YS, Lee SH, Lee DH, Kim do S, Youk EG. Clinical risk factors for perforation during endoscopic submucosal dissection (ESD) for large-sized, nonpedunculated colorectal tumors. *Surgical Endoscopy* 2012; **26**: 1587-94
- 11 Yoshida N, Naito Y, Kugai M *et al.* Efficacy of magnifying endoscopy with flexible spectral imaging color enhancement in the diagnosis of colorectal tumors. *J Gastroenterol* 2011; **46**: 65-72
- 12 Yoshida N, Yagi N, Inada Y, Kugai M, Okayama T, Kamada K, Katada K, Uchiyama K, Ishikawa T, Handa O, Takagi T, Konishi H, Kokura S, Yanagisawa A, Naito Y. Ability of A Novel Blue Laser Imaging System for the Diagnosis of Colorectal Polyps. *Dig Endosc* 2014; **26**: 250-8
- 13 Sano Y, Ikematsu H, Fu KI, Emura F, Katagiri A, Horimatsu T, Kaneko K, Soetikno R, Yoshida S. Meshed capillary vessels by use of narrow-band imaging for differential diagnosis of small colorectal polyps. *Gastrointest Endosc* 2009; **69**: 278-83
- 14 Participants in the Paris workshop. The Paris endoscopic classification of superficial neoplastic lesions: Esophagus, stomach, and colon—November 30 to December 1, 2002. *Gastrointest Endosc* 2003; **58 (Suppl)**: S3-43.
- 15 Matsumoto A, Tanaka S, Oba S, Kanao H, Oka S, Yoshihara M, Chayama K. Outcome of endoscopic submucosal dissection for colorectal tumors accompanied by fibrosis. *Scand J Gastroenterol* 2010; **45**: 1329-37
- 16 Japanese Society for Cancer of the Colon and Rectum, Japanese Classification of Colorectal Carcinoma, Kanehara, Tokyo, Japan, 2nd edition, 2009
- 17 Hamilton SR, Aaltonen LA, editors. World Health Organization classification of tumors. Pathology and genetics of tumours of the digestive system. Lyon, France: IARC Press, 2010: 104-9.
- 18 Akahoshi K, Motomura Y, Kubokawa M, Matsui N, Oda M, Okamoto R, Endo S, Higuchi N, Kashiwabara Y, Oya M, Akahane H, Akiba H. *World J Gastroenterol* 2009; **15**: 2162-5
- 19 Yoshida N, Naito Y, Kugai M, Inoue K, Uchiyama K, Takagi T, Ishikawa T, Handa O, Konishi H, Wakabayashi N, Yagi N, Kokura S, Morimoto Y, Kanemasa K, Yanagisawa A, Yoshikawa T. Efficacy of Hyaluronic Acid in Endoscopic Mucosal Resection for Colorectal Tumors. *J Gastroenterol Hepatol* 2011; **26**: 286-91
- 20 Maeda Y, Hirasawa D, Fujita N, Obana T, Sugawara T, Ohira T, Harada Y, Yamagata T, Suzuki K, Koike Y, Kusaka J, Tanaka M, Noda Y. A prospective, randomized, double-blind, controlled trial on the efficacy of carbon dioxide insufflation in gastric endoscopic submucosal dissection. *Endoscopy* 2013; **45**: 335-41
- 21 Isomoto H, Nishiyama H, Yamaguchi N, Fukuda E, Ishii H, Ikeda K, Ohnita K, Nakao K, Kohno S, Shikuwa S. Clinicopathological factors associated with clinical outcomes of endoscopic submucosal dissection for colorectal epithelial neoplasms. *Endoscopy* 2009; **41**: 679-83
- 22 Hayashi N, Tanaka S, Nishiyama S, Terasaki M, Nakadoi K, Oka S, Yoshihara M, Chayama K. Predictors of incomplete resection and perforation associated with endoscopic submucosal dissection for colorectal tumors. *Gastrointest Endosc* 2014; **79**: 427-35
- 23 Suzuki T, Matsushima M, Tsukune Y, Fujisawa M, Yazaki T, Uchida T, Gocyo S, Okita I, Shirakura K, Sasao K, Saito T, Sakamoto I, Igarashi M, Koike J, Takagi A, Mine T. Double-balloon endoscopy versus magnet-imaging enhanced colonoscopy for difficult colonoscopies, a randomized study. *Endoscopy* 2012; **44**: 38-42
- 24 Yamamoto H, Yano T, Kita H, Sunada K, Ido K, Sugano K. New system of double-balloon enteroscopy for diagnosis and treatment of small intestinal disorders. *Gastroenterology* 2003; **125**: 1556

**Peer reviewer:** Polymnia Galiatsatos, Jewish General Hospital, Room E-110 3755 Cote-Ste-Catherine Road Montreal, Quebec H3T 1E2, Canada.