

Therapeutic Strategy for Large Hepatic Hemangioma

Takahisa Fujikawa, Hiroshi Kawamoto, Akira Tanaka

Takahisa Fujikawa, Hiroshi Kawamoto, Akira Tanaka, Department of Surgery, Kokura Memorial Hospital, Kitakyushu, Fukuoka 802-8555, Japan

Correspondence to: Takahisa Fujikawa, MD, PhD, FACS, Department of Surgery, 3-2-1 Asano, Kokurakita-ku, Kitakyushu, Fukuoka 802-8555, Japan.

Email: fujikawa-t@kokurakinen.or.jp

Telephone: +81-93-511-2000

Fax: +81-93-511-3240

Received: March 10, 2016

Revised: May 1, 2016

Accepted: May 3, 2016

Published online: June, 21, 2016

ABSTRACT

Hepatic hemangioma is the most common type of benign liver tumor, and the majority of patients with small hepatic hemangioma have an uncomplicated course, although large hepatic hemangioma occasionally shows complications depending on size and location. Active surgical intervention might be considered in some situations. We successfully performed surgical intervention for a 59-year-old man with giant hepatic hemangioma in his left lobe, which was considered to be at the risk of rupture, and the favorable long-term prognosis was achieved. Although the clinical management of large hepatic hemangioma still may remain controversial, we should review individual patient conditions precisely to make an appropriate therapeutic decision.

© 2016 The Authors. Published by ACT Publishing Group Ltd.

Key Words: Large hepatic hemangioma; Therapeutic strategy; Liver resection

Fujikawa T, Kawamoto H, Tanaka A. Therapeutic Strategy for Large Hepatic Hemangioma. *Journal of Gastroenterology and Hepatology Research* 2016; 5(3): 2100-2101 Available from: URL: <http://www.ghrnet.org/index.php/joghr/article/view/1632>

LETTER TO THE EDITOR

We present a 59-year-old Japanese gentleman with asymptomatic multiple bilobar hepatic hemangiomas. Although asymptomatic, his largest hemangioma, 13 × 12 cm in size, was widely located in the left lobe, showed extrahepatic growth, and was considered for candidate of surgical intervention (Figure 1A, 1B). He underwent resection of the left hepatic lobe involving 3 hemangiomas, ranging 3 to 13 cm in size. His postoperative course was uneventful. He remained asymptomatic and his periodic imaging tests showed no growth of remnant small hemangioma in the right lobe during 2 years since his operation.

Hepatic cavernous hemangioma is the most common type of benign liver tumor, and mostly it is solitary but multiple lesions are sometimes seen^[1]. “Large” liver hemangioma is defined as a hemangioma of the liver 4 cm or larger in diameter, and “giant” liver hemangioma is currently defined as the one with a size of 10 cm or more^[2,3]. Most patients have an excellent prognosis and malignant transformation from hepatic hemangioma has not been reported. It is frequently asymptomatic; it most often discovers incidentally by imaging checkup. The majority of patients with small hepatic hemangioma have an uncomplicated course and they generally require no treatment. However, the clinical management of large hepatic hemangioma still may remain controversial; it occasionally shows complications depending on size and location. Figure 1C shows therapeutic strategy for hepatic hemangioma. Active surgical intervention might be considered in the situation when a large hemangioma becomes symptomatic, is located in the left lobe and getting larger, or grows close to the liver margins^[1,3]. Rupture, intraperitoneal bleeding, and/or Kasalbach-Merritt syndrome (giant hemangiomas accompanied by intravascular coagulation and thrombocytopenia) might occur in patients with giant hemangioma, which require prompt surgery or other types of intervention^[1,4]. Thus, we should review individual patient conditions precisely to make an appropriate therapeutic decision.

CONFLICT OF INTERESTS

There are no conflicts of interest with regard to the present study.

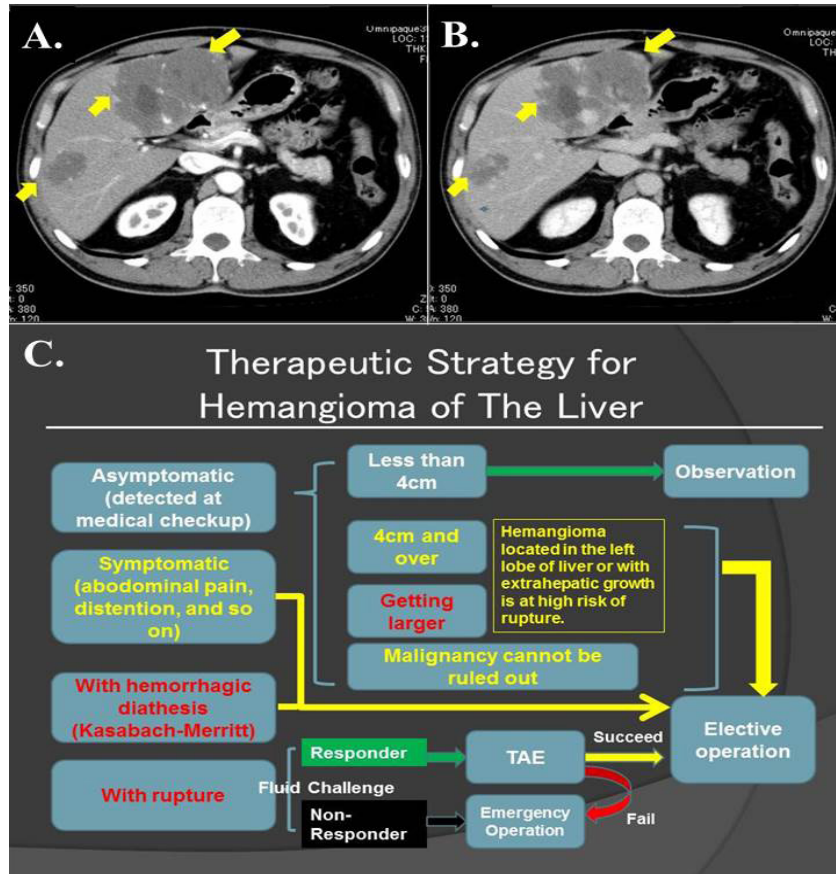


Figure 1 (A,B) Enhanced CT scan of the abdomen demonstrated multiple bilobar hepatic hemangiomas. The largest hemangioma, 13x12 cm in size, was widely located in the left lobe and showed extrahepatic growth. A: arterial phase, B: portal venous phase. (C) Flowchart of therapeutic strategy for large hepatic hemangioma. Active surgical intervention might be considered in the situation when a large hemangioma becomes symptomatic, is located in the left lobe and getting larger, or grows close to the liver margins. Those with rupture and/or Kasabach-Merritt syndrome require prompt surgery or other types of intervention. Abbreviation; TAE: transcatheter arterial embolization.

REFERENCES

- 1 Bajenaru N, Balaban V, Savulescu F, Campeanu I, Patrascu T. Hepatic hemangioma -review-. *J Med Life* 2015; **8**: 4-11
- 2 Adam YG, Huvos AG, Fortner JG. Giant hemangioma of the liver. *Ann Surg* 1970; **172**: 239-245
- 3 Bertino G, Toro A. Giant cavernous liver hemangiomas: is it the time to change the size categories? *Hepatobiliary Pancreat Dis Int* 2016; **15**: 21-29
- 4 Zhao W, Guo X, Dong J. Spontaneous rupture of hepatic hemangioma: a case report and literature review. *Int J Clin Exp Pathol* 2015; **8**: 13426-13428

Peer reviewer: Jeng Kuo-Shyang, Professor of Surgery.(HPB Surgery and Liver Transplantation), Vice President of Far Eastern Memorial Hospital, New Taipei City, Taiwan.