

Accuracy of Diagnosing PDA, Neuroendocrine Tumors, and IPMN by EUS-FNA at a Single Institution

Hannah L Beal, Jill E Shea, Benjamin L Witt, Douglas G Adler, Sean J Mulvihill, Erinn Downs-Kelly, Matthew A Firpo, Courtney L Scaife

Hannah L Beal, Jill E Shea, Sean J Mulvihill, Matthew A Firpo, Courtney L Scaife, Department of Surgery, School of Medicine, University of Utah, Salt Lake City, the United States

Benjamin L Witt, Erinn Downs-Kelly, Department of Pathology, School of Medicine, University of Utah Salt Lake City, the United States

Douglas G Adler, Division of Gastroenterology, School of Medicine, University of Utah, Salt Lake City, the United States

Correspondence to: Hannah L Beal, 207 Wintrob University of Utah 26 North Medical Drive, Salt Lake City, UT 84132, the United States.

Email: hannah.beal@hsc.utah.edu

Telephone: +435-640-4281

Received: June 28, 2015

Revised: July 24, 2015

Accepted: July 29, 2015

Published online:

PPV, and 89% (82-94) NPV. Detection of neuroendocrine tumors by FNA-EUS yielded 66% (47-87) sensitivity, 100% (97-100) specificity, 94% (71-99) PPV, and 97% (94-99) NPV. Detection of IPMN by FNA-EUS yielded 59% (43-74) sensitivity, 100% (98-100) specificity, 100% (87-100) PPV, and 89% (93-99) NPV.

CONCLUSIONS: Our findings are largely consistent with the current literature, confirming there is discernible potential for inappropriate treatment of patients based purely on EUS-FNA evaluation. Both accuracy and clarity of positive tests with EUS-FNA worsened for mucinous pancreatic lesions compared to solid pancreatic lesions. Limitations of this study are the appraisal at a single institution and the necessity to evaluate only cases that ultimately had surgical resection of the pancreatic lesion.

© 2015 ACT. All rights reserved.

Key Words: EUS-FNA; Neuroendocrine; PDAC; PDA; IPMN; Diagnostic; Accuracy; Pancreas; Cancer

Beal HL, Shea JE, Witt BL, Adler DG, Mulvihill SJ, Kelly ED, Firpo MA, Scaife CL. Accuracy of Diagnosing PDA, Neuroendocrine Tumors, and IPMN by EUS-FNA at a Single Institution. *Journal of Gastroenterology and Hepatology Research* 2015; 4(12): 1844-1849 Available from: URL: <http://www.ghrnet.org/index.php/joghr/article/view/1531>

ABSTRACT

BACKGROUND: The purpose of this study was to assess the clinical impact of diagnostic accuracy for EUS-FNA in evaluating pancreatic lesions, particularly Pancreatic Ductal Adenocarcinoma (PDAC), neuroendocrine tumors, and IPMN at our institution using surgical pathological review as the gold standard.

METHODS: We conducted a retrospective chart review using the Clinical Cancer Research Database at Huntsman Cancer Institute. We included all cases in which pancreatic lesions were evaluated by EUS-FNA and a subsequent surgical resection was performed. Sensitivity, specificity, positive predictive value (PPV), and negative predictive value (NPV) were determined for PDAC, neuroendocrine tumors, and IPMN by comparing pathological diagnosis at EUS-FNA to diagnoses following surgery.

RESULTS: Detection of PDAC by FNA-EUS yielded 87.9% (80.1-93.4 95% CI) sensitivity, 80% (72-86) specificity, 78% (70-85)

INTRODUCTION

Pancreatic ductal adenocarcinoma (PDAC) has the 4th highest cancer mortality rate for both men and women in the United States. The average 5 year survival rate for PDAC patients with localized disease that were able to undergo a resection is approximately 24%^[1]. Prognosis is poorer for the 80-85% of patients who are unable to undergo resection due to disseminated disease or

comorbidities that make them poor operative candidates, with a 5 year survival rate of 2-9%, depending on if they present with locally advanced or metastatic disease^[2]. Patients that are unable to undergo a resection are typically treated with palliative chemotherapy. As diagnosis directs disease management, accurate differentiation of PDAC, neuroendocrine tumors, chronic pancreatitis, and benign neoplasms is critical when evaluating patients with suspected pancreatic disease in order to avoid over or under treatment. The lack of anatomical accessibility of the pancreas forces clinicians to rely heavily on cross sectional imaging and endoscopic biopsy techniques in diagnosis of pancreatic lesions. Endoscopic ultrasound guided fine needle aspiration (EUS-FNA) is the standard preoperative method for the diagnosis of pancreatic lesions. Previous studies evaluating EUS-FNA for diagnosing pancreatic lesions have reported sensitivities of 80-93%, specificities of 80-100%, and diagnostic accuracies of 85% to greater than 90%^[4,5]. The incidence of false positive diagnosis of PDAC has been reported to occur at a rate of approximately 1% when EUS-FNA is utilized^[6-7]. Previous studies have only separately evaluated the efficiency of EUS-FNA for diagnosing neuroendocrine tumors^[9-11], cystic neoplasms, such as intraductal papillary mucinous neoplasms (IPMN)^[12-15], or PDAC^[16-18].

The objective of this study was to assess the diagnostic accuracy of EUS-FNA for evaluating solid pancreatic lesions, particularly PDAC, neuroendocrine tumors, and IPMN at our institution, using surgical pathological review as the gold standard. In this context, we also determined the number of patients who received unnecessary neoadjuvant treatment due to a misdiagnosis by EUS-FNA.

MATERIALS AND METHODS

Patients

This study was approved by the Institutional Review Board at the University Of Utah School Of Medicine. We conducted a retrospective chart review using the Clinical Cancer Research Database at the University of Utah Huntsman Cancer Institute (HCI). We included all cases in which pancreatic lesions were evaluated by EUS-FNA and a subsequent surgical resection was performed, since pathological review at resection is the current “gold standard”. The comparison of EUS-FNA to surgical diagnosis is also common among other studies analyzing accuracy of EUS-FNA for diagnosing lesions of the pancreas^[5, 7, 9, 12,13]. Patients who underwent EUS-FNA and who did not undergo surgical resection for any reason were excluded. All patients that met these criteria at HCI between March 1999 and April 2014 were included. We evaluated the accuracy of EUS-FNA for diagnosing PDAC, neuroendocrine tumors, and IPMN using surgical pathology review as the gold standard.

EUS-FNA Procedure

EUS FNA was performed in the standard manner. EUS-FNA was performed with 19, 22, or 25 gauge needles per the endosonographer’s discretion. All cases included in this study were completed by two HCI endosonographers. One or more samples of suspicious pancreatic lesions and/or pancreatic adenopathy were evaluated.

Pathological Review

All included cases had a rapid on-site evaluation conducted by a cytopathologist during the EUS-FNA procedure. In evaluating patient cases on-site, the cytopathologist used a rapid modified Romanowsky stain, Diff-Quik®, to assess for lesional cellularity and

overall specimen adequacy during the procedure. This information was used to communicate to the endosonographer as well as to triage biopsy material for any possible ancillary testing. The final cytologic diagnoses were rendered after the case material had been processed by the cytopathology laboratory. For most cases the processing included cover-slipping the on-site FNA slides, staining alcohol-fixed smears using the Papanicolaou method, and making slides from needle rinses (either cytospins, liquid-based, or cell block preparations). A subset of cases had ancillary testing performed, including immunohistochemical stains and flow cytometry prior to the final diagnosis.

After resection, surgical specimens were delivered from the operating room to the pathology gross room. Here the specimens were oriented and inked in accord with the specimen type. Pertinent sections, to include the lesional area of interest and respective margins, were submitted for final histology either by a pathology resident or a certified pathology assistant. A final histologic diagnosis was rendered after review of the Hematoxylin and Eosin (H+E) stained slides for each case by a pathologist. In cases warranting further workup, immunohistochemical stains were performed and interpreted prior to issuing a final diagnosis.

A board certified cytopathologist categorized the differences between EUS-FNA and surgical pathology diagnoses as “good correlation”, “not unexpected discrepancy”, and “significant discrepancy” (discrepancy potentially impacting patient management). The cytopathologist retrospectively compared the reported diagnostic interpretations from the EUS-FNA cytology specimens to the reported subsequent surgical resection diagnoses for each patient. No slides were re-reviewed during this process.

The sensitivity, specificity, positive predictive value (PPV), and negative predictive value (NPV) were calculated by comparing EUS-FNA results to final surgical diagnoses. The variables used to determine these values were: false positive = positive diagnosis by EUS-FNA and negative at resection, true positive = positive diagnosis for both, false negative = negative diagnosis at EUS-FNA and positive at resection, true negative = negative for both. For analysis of accuracy of EUS-FNA in detecting PDAC we considered atypical cells as a positive diagnosis, since their presence suggests aggressive intervention by the treating clinician. This is consistent with other studies evaluating the accuracy of EUS-FNA in diagnosing PDAC^[5,7]. However, we also recalculated the descriptive variables considering atypical cells as a negative for PDA. For assessing accuracy of EUS-FNA to detect neuroendocrine tumors, we considered neuroendocrine tumor and suspicious for neuroendocrine tumor as a positive result, and atypical cells as a negative result, also as previously reported^[9]. While assessing accuracy of diagnosis when EUS-FNA was utilized in detecting IPMN, we determined descriptive variables by considering all selected EUS-FNA’s considered by board certified cytopathologist and surgeon to likely be considered IPMN or mucinous cystic neoplasm in a clinical setting.

RESULTS

A total of the 251 patients satisfied the inclusion criterion. Ten patients were excluded who underwent EUS-FNA but no sample was attained due to anatomical barriers, 4 cases were non-diagnostic due to hypocellular smears, leaving 237 significant cases. Of the 237 patients included, 134 were female with an average age of 59 +/- 15 (mean +/- standard deviation) and 103 were male with an average age of 62 +/- 13.

Of 237 cases with diagnostic EUS-FNA that subsequently

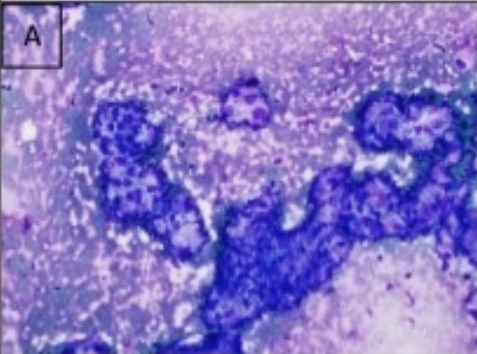
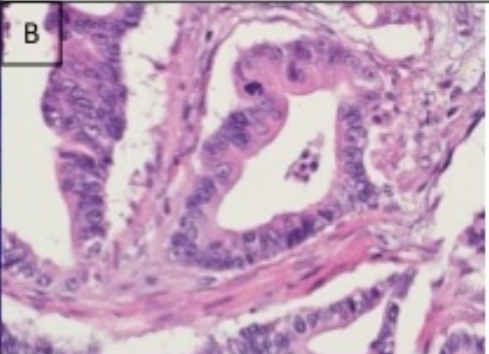
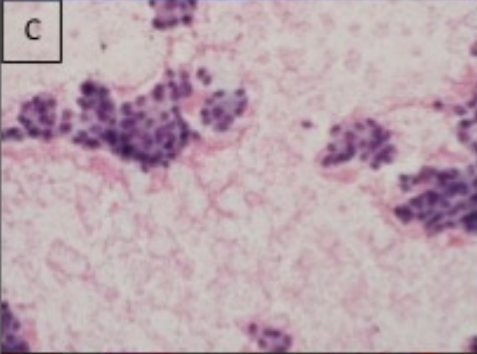
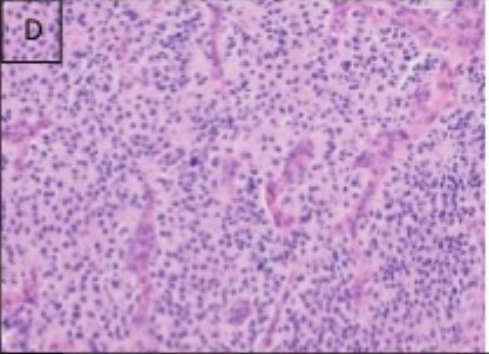
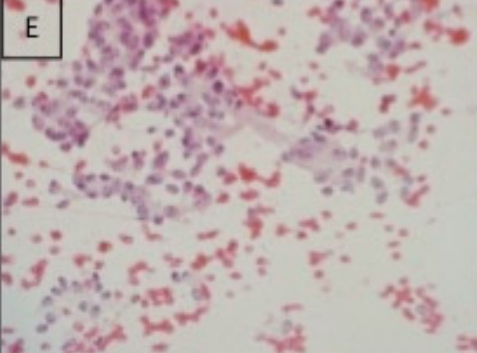
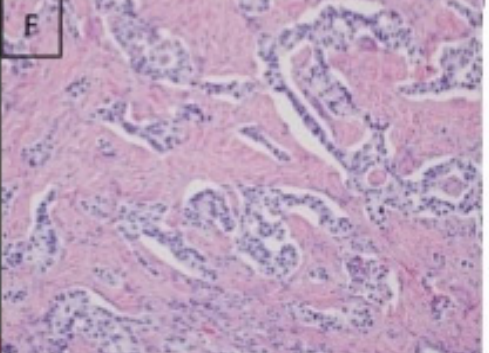
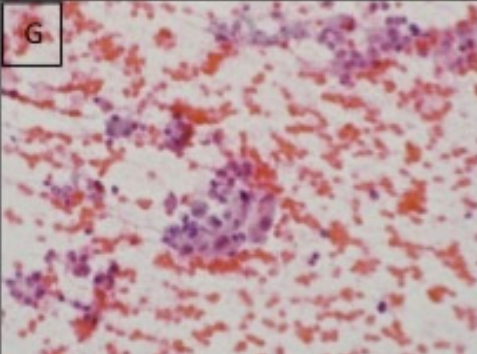
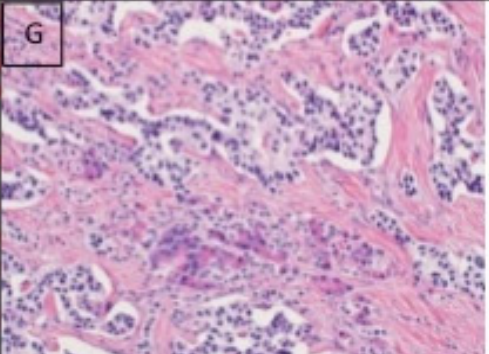
	EUS-FNA	Surgical Pathology
Concordant PDAC		
Concordant Neuroendocrine		
Discordant PDAC(FNA)-Neuroendocrine (Surgery)		
Discordant Neuroendocrine (FNA)-PDAC(Surgery)		

Figure 1: A. EUS-FNA sample correctly diagnosed as PDAC. B. Surgical pathology sample confirming correct PDAC diagnosis. C. EUS-FNA sample correctly diagnosed as neuroendocrine tumor. D. Surgical pathology sample confirming correct neuroendocrine tumor diagnosis. E. EUS-FNA neuroendocrine tumor sample miscategorized as PDAC. F. Surgical pathology sample showing final diagnosis of neuroendocrine tumor. G. EUS-FNA PDAC sample miscategorized as neuroendocrine tumor. H. Surgical pathology sample showing final diagnosis of PDAC.

underwent surgical resection of the pancreatic lesion, 157 were pathologically ranked as “good correlation”, 48 were ranked “not unexpected disparity”, and 32 were ranked “significant discrepancy”. By categorizing only significant discrepancy ranking as a misdiagnosis by FNA, 13.5% (32/237) of pancreatic lesions are misdiagnosed by EUS- FNA.

Pancreatic Adenocarcinoma Diagnosis by EUS-FNA

We first considered atypical cells as a positive test for PDAC. Of the 120 positive tests, 80% (94/120) were true positive and 20% (26/120) were false positive. Of the 117 negative tests, 89% (104/117) true negative and 11% (13/117) were false negative. In terms of detection of PDAC by EUS-FNA, we determined the

sensitivity to be 87.9% (95% CI: 80.1-93.4), specificity to be 80.0% (95% CI: 72.1-86.5), PPV to be 78.3% (95% CI: 69.9-85.3), and NPV to be 88.9% (95% CI: 81.8-93.9), when atypical cells were considered a positive test for PDAC (Table 1). Of the 26 false positive diagnoses of PDAC, 19 (73%) were finally diagnosed as other malignancies and included 8 neuroendocrine tumors, 3 microcytic adenoma, 2 bile duct cholangiocarcinoma, 2 ampullary adenocarcinoma, 1 adenosquamous carcinoma, 1 mixed acinar-endocrine carcinoma, 1 solid and pseudo papillary tumor, and 1 diffuse large B-cell lymphoma (Table 2; Figure 1). All 13 of the false negative diagnoses were diagnosed by EUS-FNA as a benign pancreatic lesion.

When considering only cases where EUS-FNA definitively diagnosed the patient as PDAC as positive, defining atypical as a negative test for PDAC, we determined the sensitivity to be 68.2% (95% CI: 58.5-76.9), specificity to be 90% (95% CI: 83.5-94.6), PPV to be 84.9% (95% CI: 75.5-91.7), and NPV to be 77.5% (95% CI: 70-83.9) (Table 1). Of the 86 positive tests, 85% (73/86) were true positive and 15% (13/86) were false positive. Of the 151 negative tests, 77% (117/151) true negative and 55% (34/151) were false negative. Of the 13 false positive diagnoses of PDAC, 10 were finally diagnosed as other malignancies. Final diagnoses included 4 neuroendocrine tumors, 1 bile duct cholangiocarcinoma, 1 ampullary adenocarcinoma, 1 adenosquamous carcinoma, and 1 mixed acinar-endocrine carcinoma, 1 solid and pseudo papillary tumor, and 1 diffuse large B-cell lymphoma (Table 2). Of the 34 false negative diagnoses, 21 were diagnosed by EUS-FNA as 22 atypical cells.

We found 38 cases that were treated with neoadjuvant chemotherapy after being diagnosed by EUS-FNA as PDAC or atypical, 35 were diagnosed as PDAC at surgical resection, 1 was finally diagnosed as bile duct cholangiocarcinoma, 1 was diagnosed as ampullary adenocarcinoma, and 1 was diagnosed as IPMN. Three of 38 patient treated with neoadjuvant chemotherapy for PDAC, were diagnosed at surgical resection as another pancreatic lesion.

Pancreatic Neuroendocrine Tumor Diagnosis by EUS-FNA

In diagnosis of neuroendocrine tumors by EUS-FNA, sensitivity was 65.6% (95% CI: 47.1-86.7), specificity 99.5% (95% CI: 97.4-99.9), PPV 94.1% (95% CI: 71.2-99.2), and NPV 96.8% (95% CI: 93.5-98.7) (Table 1). Of the 17 positive tests, (16/17) were true positive and (1/17) were false positive. Of the 220 negative tests, 97% (213/220) true negative and 3% (7/220) were false negative. The one false positive neuroendocrine tumor diagnosis was finally diagnosed as no neoplasm (Table 2). Of the 7 false negative diagnoses, 6 were diagnosed by EUS-FNA as other malignancies including 4 PDAC (Figure 1), 1 atypical cells (suggestive of PDAC), 1 carcinoma (type cannot be determined).

IPMN Diagnosis by EUS-FNA

In terms of detection of IPMN and mucinous cystic neoplasms by EUS-FNA, sensitivity was 59% (95% CI: 43.25% to 73.65%), specificity 100% (95% CI: 98.1%-100%), PPV 100% (95% CI: 86.65%-100%), and NPV 96.9% (95% CI: 93.4-98.8), based on pathologist evaluation of diagnosis that were suggestive of IPMN and mucinous cystic neoplasm (Table 1). Of the 26 positive tests, 100% were true positive. Of the 211 negative tests, 91% (193/211) were true negative and 9% (18/211) were false negative. Of the 18 false negative tests, 15 were diagnosed by EUS-FNA as another benign lesions. There were no false positive diagnoses of IPMN.

Table 1 Accuracy and Incidence of EUS-FNA in detecting PDAC, neuroendocrine tumor, and IPMN.

Disease	Sensitivity	Specificity	PPV	NPV	% of Cases
PDAC (atypical +)	88%	80%	78%	89%	45%
PDAC (atypical -)	68%	90%	85%	78%	45%
Neuroendocrine Tumor	66%	100%	94%	97%	10%
IPMN	59%	100%	100%	97%	19%

Table 2 False Positive Diagnoses of EUS-FNA.

EUS-FNA Diagnosis	Surgical Pathology Diagnosis	Incidence	
PDAC(atypical +)	neuroendocrine tumor	8	
	microcytic adenoma	3	
	bile duct cholangiocarcinoma	2	
	ampullary adenocarcinoma	2	
	adenosquamous carcinoma	1	
	mixed acinar-endocrine carcinoma	1	
	solid and pseudo papillary tumor	1	
PDAC(atypical -)	diffuse large B-cell lymphoma	1	
	benign	7	
	Neuroendocrine tumor	neuroendocrine tumor	4
		bile duct cholangiocarcinoma	1
		ampullary adenocarcinoma	1
		adenosquamous carcinoma	1
		mixed acinar-endocrine carcinoma	1
solid and pseudo papillary tumor		1	
diffuse large B-cell lymphoma		1	
IPMN	benign	3	
	false positive diagnoses	1	
		0	

DISCUSSION

In this study, we evaluated the diagnostic accuracy of EUS-FNA for discriminating PDAC, neuroendocrine tumors, and IPMN in cases of periampullary disease, using surgical pathology as the gold standard. In terms of diagnosing PDAC, we found a specificity of 80% and a sensitivity of 87.9%, when atypical cells were considered a positive result. These values of sensitivity and specificity are well within the current literature reported values for the accuracy of diagnosing solid pancreatic lesions by utilizing EUS-FNA^[4,5]. When we considered an EUS-FNA diagnosis of atypical cells as a positive test for PDAC, there were 13 false negative cases. All 13 false negative tests had a final diagnosis of benign lesions at surgical resection. In contrast, when we considered EUS-FNA diagnosis of atypical to be a negative test for PDAC there were 34 false negative cases. Of the 34 false negative tests 38% had a final diagnosis of benign lesions and 62% had a diagnosis of another malignancy at the time of surgical resection. Additionally, when the presence of atypical cells were considered a negative test, specificity was including comparable to the literature (90%), but the sensitivity of diagnosing PDAC when utilizing EUS-FNA was significantly lower (68.2%) compared to commonly reported sensitivities of 80-85%^[4,5,16-18].

Another study reported very low incidence of false positive diagnosis (0-5%) when using EUS-FNA as a diagnostic tool for PDAC^[12]. In our study we found that 22% (26/120) of the cases initially diagnosed as PDAC by EUS-FNA had a different final diagnosis by surgical pathology, when atypical were considered positive. Of these 26 cases a majority, 19, were in fact other malignancies. Although patients with atypical cells were typically diagnosed with a malignancy it is important to recognize different malignancies may warrant different treatment. Thus, misdiagnosis

even between malignancies can interfere with quality of patient care. Considering misdiagnosis can lead to decreased quality of patient care and quality of life, we also examined the incidence of cases unnecessarily treated with neoadjuvant chemotherapy due to misdiagnosis by EUS-FNA. We found 38 cases had neoadjuvant treatment for PDAC. Of those, (3/38) were diagnosed as not having PDAC at the time of resection. These three cases were diagnosed as bile duct cholangiocarcinoma, ampullary adenocarcinoma, and IPMN. These cases may have received different treatment if a false positive misdiagnosis of PDAC by EUS-FNA had not occurred. Based on 2010 Medicare reimbursement for CPT codes, the technical component for the performance of EUS-FNA is \$65. The pathology component of the EUS-FNA incurs additional CPT fees. With the incorporation of on-site evaluation fee for pathology of EUS-FNA costs \$171, in cases where a cell block is made the cost increases to \$271. Although pertinent to only a small subset of cases, if immunohistochemical stains and/or flow cytometry is performed the total cost for the pathology aspect of the procedure may exceed \$400^[19]. While the mean total cost of chemotherapy/radiation therapy for patients with resectable PDAC was reported in 2012 to be \$13,600^[20]. Based on this, it may be more cost effective to repeat EUS-FNA on all patients before considering neoadjuvant chemotherapy.

For the detection of pancreatic neuroendocrine tumors by EUS-FNA we found a lower sensitivity (65.6) and higher specificity (99.5%) than reported in other studies for diagnosis of solid pancreatic lesions^[4,5]. This discrepancy is most likely due to atypical cells being clinically considered PDAC for treatment purposes. Some cases that were suggestive of malignancy in general were treated clinically as PDAC, because PDAC cases require more aggressive treatment and have a poorer prognosis. The majority of misdiagnosis for neuroendocrine tumors(6/8) were falsely identified by pathological reading of EUS-FNA samples as another malignancy, most commonly PDAC(4/8). There was only one incidence of a false positive diagnosis, which was diagnosed at surgical resection as “no neoplasm”.

Some studies have reported the accuracy of diagnosis utilizing EUS-FNA to be less accurate for cystic and other non-solid pancreatic lesions. In our evaluation, the ability of pathologists and cytologists using EUS-FNA samples to detect IPMN showed a sensitivity of 59%, which was lower than that for PDAC (80%), but is consistent with current literature for sensitivity of detecting cystic lesions from 47% to 87%^[12,15]. We found our reported specificity (100%) is consistent with other studies that report specificity between 87%-100%^[12-15]. The majority of misdiagnoses that were finally diagnosed as IPMN were suggestive of other benign diagnoses (15/18). The misdiagnoses for IPMN were exclusively false negative diagnoses. Original diagnoses using EUS-FNA of PDAC, no malignant cells, cystic contents only were finally diagnosed as IPMN. The less straight forward relationship between cytological evaluation for IPMN and other cystic neoplasms is a possible cause for lower accuracy in regard to detection of specific disease type for non-solid pancreatic lesions compared to solid pancreatic lesions.

The limitations for this investigation include completion at a single institution, reliance on chart review, and inclusion of only cases in which patients underwent subsequent surgical resection in order to obtain a pathological sample to be considered the gold standard of diagnosis. Many benign cases and unresectable PDAC cases do not go on to surgical resection, making their inclusion in the study impossible. Using only the cases that went on to surgical resection and received a surgical pathological review, which we deemed our

gold standard, allowed evaluation of the accuracy of EUS-FNA, including the process of cytological and pathologic review of EUS-FNA samples, in a way that seems to correlate with current literature, yet ability to evaluate global accuracy of EUS-FNA is limited.

This study confirms there is discernible potential for inappropriate treatment of patients based purely on EUS-FNA evaluation. The study adds to current literature by assessing accuracy of EUS-FNA for diagnosis of PDAC, neuroendocrine, and IPMN in a single study and including incidence of unnecessary treatment with neoadjuvant chemotherapy due to misdiagnosis using EUS-FNA. The ability to detect malignancy using EUS-FNA seems to be fairly high, while the ability to distinguish between different types of malignancies is less accurate. According to our data, diagnosis utilizing EUS-FNA is most accurate at detecting PDAC when atypical cells are considered positive. However, the shift towards PDAC as the diagnoses for more ambiguously evaluated EUS-FNA malignancies may be cause for the decrease in sensitivity of diagnosis utilizing EUS-FNA in detecting neuroendocrine disease. It is evident that diagnosis utilizing EUS-FNA is more accurate and the cytological evaluation is more straight-forward when evaluating solid pancreatic lesions compared to cystic lesions such as IPMN. Based on our data regarding incidence of unnecessary neoadjuvant treatment, a repeat EUS-FNA may be considered before initiating neoadjuvant chemotherapy for the treatment of PDAC. Improvements could be made to diagnosis by EUS-FNA by investigating better ways to distinguish between malignancy types, or addressing vagueness of cytological description when using EUS-FNA as a diagnostic tool.

CONFLICT OF INTEREST

The authors declare that they have no conflict of interest.

REFERENCES

- 1 Vincent A, Herman J, Schulick R, Hruban RH, Goggins M. Pancreatic cancer. *Lancet* 2011; **378**: 607-620
- 2 Siegel R, Jiemin Ma, Zou Z, Jemal A. (2014) Cancer statistics. *CA Cancer J Clin* **64**(1): 9-29
- 3 Erturk SM, Mortelé KJ, Tuncali K, Saltzman JR, Lao R, Silverman SG. Fine-needle aspiration biopsy of solid pancreatic masses: comparison of CT and endoscopic sonography guidance. *AJR Am J Roentgenol* 2006; **187**(6): 1531-1535
- 4 Jhala N, Jhala D, Vickers SM, Eltoum I, Batra S, Manne U. Biomarkers in Diagnosis of pancreatic carcinoma in fine-needle aspirates. *Am J Clin Pathol* 2006; **126**(4): 572-579
- 5 Eloubeidi MA, Chen VK, Eltoum IA, Jhala D, Chhieng DC, Jhala N. Endoscopic ultrasound-guided fine needle aspiration biopsy of patients with suspected pancreatic cancer: diagnostic accuracy and acute and 30-day complications. *Am J Gastroenterol* 2003; **98**(12): 2663-2668
- 6 Caglar E, Senturk H, Astasoy D, Sisman G, Canbakan B, Tuncer M. The role of EUS and EUS-FNA in the management of pancreatic masses: five-year experience. *Hepatogastroenterology* 2013; **60**(124): 896-899
- 7 Bergeron JP, Perry KD, Houser PM, Yang J. Endoscopic ultrasound-guided pancreatic fine-needle aspiration: Potential pitfalls in one institution's experience of 1212 procedures. *Cancer Cytopathol* 2014; **123**(2): 21497
- 8 Siddiqui AA, Kowalski TE, Shahid H, O'Donnell S, Tolin J, Loren DE, Infantolino A, Hong SK, Eloubeidi MA. False-positive EUS-guided FNA cytology for solid pancreatic lesions. *Gastrointest Endosc* 2011; **74**(3): 535-540
- 9 Hooper K, Mukhtar F, Li S, Eltoum IA. Diagnostic error assessment and associated harm of endoscopic ultrasound-

- guided fine-needle aspiration of neuroendocrine neoplasms of the pancreas. *Cancer Cytopathol* 20014; **121(11)**: 653-660
- 10 Chen S, Lin J, Wang X, Lin J, Wang X, Wu HH, Cramer H. EUS-guided FNA cytology of pancreatic neuroendocrine tumor (PanNET): a retrospective study of 132 cases over an 18-year period in a single institution. *Cytopathology* 2014; **25(6)**: 396-403
 - 11 Baghbanian M, Banqhbanian A, Salmanroghani H, Ghezlou M, Bakhtpour M, Shabazhani B. Efficacy of endoscopic ultrasound fine needle aspiration in diagnosing the rare (non-adenocarcinoma) tumors of pancreas. *Acta Gastroenterol Belg* 2014; **77(3)**: 312-317
 - 12 Woolf KM, Liang H, Sletten ZJ, Russell DK, Bonfilio TA, Zhou Z. False-negative rate of endoscopic ultrasound-guided fine-needle aspiration for pancreatic solid and cystic lesions with matched surgical resections as the gold standard: one institution's experience. *Cancer Cytopathol* 2013; **121(8)**: 449-458
 - 13 Maire F, Voitot H, Aubert A, Palazzo L, O'Toole D, Couvelard A, Levy P, Vidaud M, Sauvanet A, Ruzzniewski P, Hammel P. Intraductal papillary mucinous neoplasms of the pancreas: performance of pancreatic fluid analysis for positive diagnosis and the prediction of malignancy. *Am J Gastroentero* 2008; **1103(11)**: 2871-2877
 - 14 Wright GP, Morrow JB, Shaheen M, Goslin BJ, Baatenburg L, Chung MH. Accuracy of endoscopic ultrasound in the evaluation of cystic pancreatic neoplasms: a community hospital experience. *Pancreas* 2014; **43(3)**: 465-9.
 - 15 Oguz D, Öztaş E, Kalkan IH, Tayfur O, Cicek B, Aydog G, Kurt M, Beyazit Y, Etik D, Nadir I, Sahin B. Accuracy of endoscopic ultrasound-guided fine needle aspiration cytology on the differentiation of malignant and benign pancreatic cystic lesions: a single-center experience. *J Dig* 2013; **14(3)**: 132-9
 - 16 Krishna, SG, Li F, Bhattacharya A, Ladha H, Porter K, Amapai S, Ross WA, Bhutani MS, Lee JH. Differentiation of pancreatic ductal adenocarcinoma from other neoplastic solid pancreatic lesions: a tertiary oncology center experience. *Gastrointest Endosc* 2014; **81(2)**: 370-379
 - 17 Zihao G, Jie Z, Yan L, Jing Z, Jing C, Xue L, Jing Z, Heng LW, Ru G, Jianyu H. Analyzing S100A6 expression in endoscopic ultrasonography-guided fine-needle aspiration specimens: a promising diagnostic method of pancreatic cancer. *J Clin Gastroentero* 2013; **147(1)**: 69-75
 - 18 Akobeng AK. Understanding diagnostic tests 1: sensitivity, specificity and predictive values. *Acta Paediatr* 2007; **96(3)**: 338-41
 - 19 Moberly AC, Vural E, Nahas B, Bergeson TR, Kokoska MS. Ultrasound-guided Needle Aspiration: Impact of Immediate Cytologic Review. *Laryngoscope* 2010; **210**: 1979-1984
 - 20 O'Neill C B, Atoria CL, O'Reilly EM, LaFemina J, Henman MC, Ekin EB. Costs and trends in pancreatic cancer treatment. *Cancer* 2012; **118**: 5132-5139
- Peer reviewer:** Cerwenka R. Herwig, Professor, Department of Surgery, Medical University of Graz, Auenbruggerplatz 29, A-8036 Graz, Austria