

Upper Eyelid Augmentation using Hyaluronic Acid Filler

Maram Alzain, Yara Alfheid, Mohammed A. Alsufyani

Maram Alzain, Yara Alfheid, Mohammed A. Alsufyani, Department of Dermatology and Dermatologic Surgery, Prince Sultan Military Medical City, Riyadh 11159, Saudi Arabia

Correspondence to: Mohammed A. Alsufyani, Department of Dermatology and Dermatologic Surgery, Prince Sultan Military Medical City, Riyadh 11159, Saudi Arabia.

Email: malsufyani@psmmc.med.sa

Received: July 23, 2016

Revised: August 8, 2016

Accepted: August 11, 2016

Published online: September 18, 2016

ABSTRACT

Aging changes occur in all the structures of the eye causing varied effects. Hyaluronic acid fillers provide an alternative to patients who decline surgery or are poor surgical candidates or basically opt to go for such invasive procedures. The application of hyaluronic acid injection into upper eyelid and superior sulcus with using cannula are useful and safe methods of restoring the youthful look and fullness of the upper eye lid with minimal side effects compared to using sharp needles, which are also more convenient to the surgical approach. Improving understanding of the ageing changes will help understand some of the problems that are faced by the aging population.

Key words: Upper eyelid; Aging; Hyaluronic acid; Superior sulcus

© 2016 The Authors. Published by ACT Publishing Group Ltd.

Alzain M, Alfheid Y, Alsufyani MA. Upper Eyelid Augmentation using Hyaluronic Acid Filler. *Journal of Dermatological Research* 2016; 1(3): 57-59 Available from: URL: <http://www.ghrnet.org/index.php/jdr/article/view/1800>

INTRODUCTION

Facial volume loss is one of the major signs of aging. Such atrophy and progressive breakdown of underlying subcutaneous cell components includes fat, muscle, bone resorption and fascia,

which results in altered shape and positioning of the fat pads which results in a sad and tired complexion. Upper eyelid asymmetry and hollowness are some of the manifestations on the face inflicted by such atrophy. This can impact the overall facial harmony and aesthetics. Addressing these asymmetries can significantly improve facial aesthetics.

ANATOMY OF EYELID

The subcutaneous fat of the face is partitioned into discrete anatomic compartments. Facial aging is characterized by how these compartments change with age. Knowledge of this anatomy will lead to better understanding and decision of procedure needed.

The eyelid skin is firmly connected to the underlying orbicularis oculi muscle through fine connective tissue attachments. The orbicularis oculi is divided into pretarsal, preseptal, and orbital components^[1,2].

Deep to the orbicularis oculi is the orbital septum, which is a thin fibrous sheet extending from the arcus marginalis of the orbital rim to its fusion with the levator aponeurosis, which is an extension of the levator palpebral superioris^[3,4], figure 1.

Three subcutaneous fat compartments exist around the eye. The most superior compartment is bounded by the orbicularis retaining ligament as it courses around the superior orbit. The orbicularis retaining ligament is a circumferential structure that spans the superior and inferior orbits and blends into the medial and lateral canthi. Between the orbital septum and the levator aponeurosis, and divided into two preaponeurotic fat collections, the nasal and central fat pads, that are separated by the superior oblique muscle tendon. The nasal fat is white and resistant to atrophy. Central fat is yellow, similar to adipose tissue throughout the body, and of mesodermal origin. It is subject to significant volume loss with aging and is separated from intraconal orbital fat by the levator aponeurosis^[4,5].

PATTERNS OF UPPER EYELID AND BROW AGING

Solar damage, gravitational forces, and lipoatrophy together cause upper lid and brow aging. Solar damage leads to skin degeneration

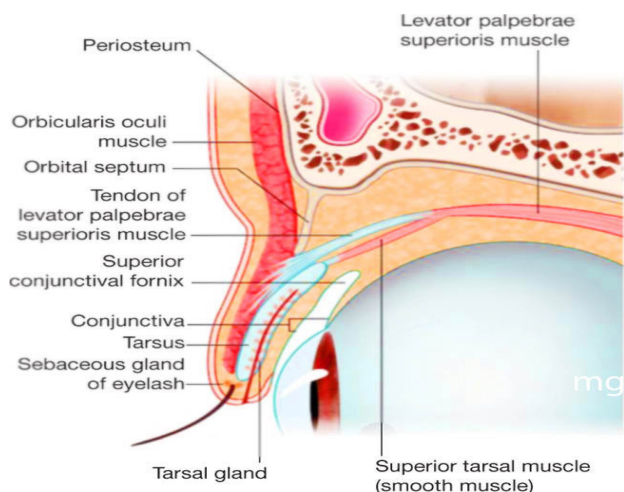


Figure 1 Anatomy of the upper eyelid.

with fine rhytids and increased elastosis. Gravitational forces initiate slow downward descent of soft tissue with resultant laxity and ptotic appearance.

Lipoatrophy leads to volume loss particularly at the central fat pad with increased upper eyelid show and a skeletonized supraorbital rim appearance and an overall deflated form. These three components—skin degeneration, laxity, and deflation, each manifest varying degrees across patients. This variability leads to distinct presentations of upper periorbital aging^[6].

Surgical correction together with fat injection has been suggested as the intervention of choice for addressing upper eyelid margin asymmetry and hollowness^[7-10].

Hyaluronic acid gel (HA) fillers have demonstrated efficacy in the periocular region as they allow for precise placement and control, and are reversible with hyaluronidase, if needed. HA fillers are easily used in an office setting, providing an alternative to patients who decline surgery or are poor surgical candidates or basically opt to go for such invasive procedures. Few articles describe correction of upper eyelid hollowness using hyaluronic acid injection via needle.

Here, we describe the use of hyaluronic acid injection in the upper eyelid to treat upper eyelid margin asymmetry and/or hollowness of various etiologies using cannula to minimize the adverse effect.

Description of technique

A lidocaine premixed 1-ml hyaluronic acid syringe is further mixed with 0.2 mL of 1% plain lidocaine by using a leur-leur lock to connect the hyaluronic acid syringe with the 3ml syringe containing the 0.2 mL lidocaine. The mixing is done with a back and forth modulation technique for approximately 10 times, to assure proper blending.

The patient is made to sit at a 45-degree angle and using isopropyl 70% alcohol swabs, the upper eyelid region is disinfected and made ready for injection. A 25 G needle is used to create the entry point by introducing the whole length of the bevel of the needle. The syringe of the hyaluronic acid is mounted with a 1 1/2 inch long 27G cannula.

The cannula is then introduced down to the level of the subcutaneous fat and the HA is injected and massaged afterwards, taking advantage of the superior orbital bone rim by pulling the skin superiorly to bring the area augmented to rest over the bony background. This is done to mold it to the desired end point. Extreme care should be taken when working around regions of major vessels (supratrochlear and supraorbital vessels). The technique maybe viewed on <https://youtu.be/nD8jl4OWUxk>.



Figure 2 Before treatment showing increased hollowness of the left medial upper eyelid, compared to the contralateral side.

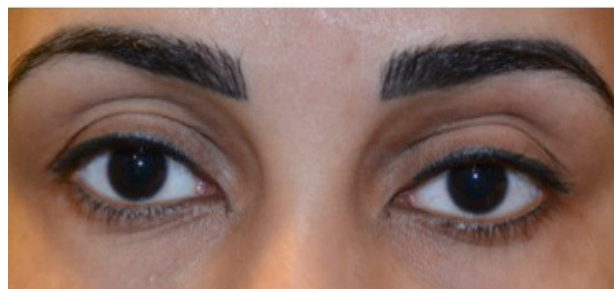

Figure 3 After treatment showing restoration of symmetry of both upper eyelids.

DISCUSSIONS

An aesthetic and youthful upper periorbital subunit is characterized by the fullness of the periorbital unit and well-defined upper eyelid crease with minimal excess skin and good skin quality. This area is one of the first regions to show signs of aging and even minor changes in aged and tired look^[11].

In our study, six patients underwent the treatment, all which were females, ages between 28 and 43 years. Five patients had bilateral hollowness and one had asymmetry of the upper eyelids.

The evaluation was done using the GAIS (Global Aesthetic Improvement Scale):

- Very much improved (score 1); optimal cosmetic result for implant in this patient.
- Much improved (score 2); marked improvement in the appearance but not completely optimal for this patient. A touch up would slightly improve the result.
- Improved (score 3); obvious improvement in appearance from the initial condition, but a touch up or re-treatment is indicated.
- No Change (score 4); the appearance is essentially the same as original condition.
- Worse (score 5); the appearance is worse than the original condition.

One patient has a score of 2 and the remainder had scored 3 on the GAIS. Figures 2 and 3.

Side effect was mild and transient and is limited to injection site reaction, such as bruising & swelling. Of note, the edema was found to be more prolonged in comparison to soft tissue augmentation of other regions; as it usually lasts up to two weeks. In our patients it lasted for duration of three weeks' period before resolving completely. We believe this is attributed to the gravitational effects.

Superior sulcus hollowness and/or eyelid asymmetry can be a result of a previous blepharoplasty, secondary to aging or as normal variation. The loss of volume of the periorbital soft tissue leads to overall deflated and aged appearance. Different ways have been used to restore the volume, autologous fat transplantation and it is one

of the methods that has some disadvantages, first the tissue being harvested from donor site, second the procedure may need sedation/general anesthesia; third, the fat survival rate is variable and its volume may increase with weight gain^[11]; fourth, the formation of visible lumps which may need surgical excision and fifth. Embolization with vision loss or cerebrovascular accidents has been reported^[12-17].

Hyaluronic acids have been used successfully in the periorbital rim with easy application, minimal down time in addition to the safe nature of the product and short duration of the procedure. The minimal irregularities and the ability to dissolve the product with hyaluronidase is one of the main positive aspects of using hyaluronic acid fillers.

Our study differs from the previous reported ones utilizing HA for upper eyelid augmentation in that by using a blunt cannula instead of sharp needle minimizes, if not eliminate, the inherent risk of sharp needle as has been reported including intravascular injections, nerve injuries^[12-17].

CONCLUSION

With the surge of non-surgical rejuvenating procedures beyond the wrinkles and skin folds, dermal fillers have been increasingly used to restore volume of the aged and deflated face.

We believe that the use of Hyaluronic acids injection into upper eyelid and superior sulcus with using cannula are useful and safe methods of restoring the youthful look and fullness of the upper eye lid with minimal side effects compared to using sharp needles which are more convenient to the surgical approach.

CONFLICT OF INTERESTS

The authors declare that they do not have conflict of interests.

REFERENCES

- 1 Kakizaki H, Malhotra R, Selva D. Upper eyelid anatomy: an update. *Ann Plast Surg* 2009; **63**: 336-43.
- 2 Persichetti P, Di Lella F, Delfino S, et al. Adipose compartments of the upper eyelid: anatomy applied to blepharoplasty. *Plast Reconstr Surg* 2004; **113**: 373-8.
- 3 Kaminer MS, Omura NE. Autologous fat transplantation. *Arch Dermatol* 2001; **137**: 812.
- 4 Rubin A, Hoefflin SM. Fat purification: survival of the fittest. *Plast Reconstr Surg* 2002; **109**: 1463.
- 5 Brucker M, Sati S, Spangenberg A, et al. Long-term fate of transplanted autologous fat in a novel rabbit facial model. *Plast Reconstr Surg* 2008; **122**: 749-54.
- 6 Rod J, Rohrich, Joel E Pessa. The Fat compartment of the face: Anatomy and Clinical Implications for cosmetic Surgery. *Plast Reconstr Surg* 2012; **129**: 31S-39S
- 7 Oh SR, Chokthaweesak W, Annunziata CC, Priel A, Korn BS, Kikkawa DO. Analysis of eyelid fat pad changes with aging. *Ophthalmol Plast Reconstr Surg*. 2011; **27**: 348-51.
- 8 Zimble MS, Kokoska MS, Thomas JR. Anatomy and pathophysiology of facial aging. *Facial Plast Surg Clin North Am*. 2001; **9**: 179-87.
- 9 Coleman S, Saboeiro A, Sengelmann R. A comparison of lipatrophy and aging: volume deficits in the face. *Aesthetic Plast Surg*. 2009; **33**: 14-21.
- 10 Donath AS, Glasgold RA, Glasgold MJ. Volume loss versus gravity: new concepts in facial aging. *Curr Opin Otolaryngol Head Neck Surg*. 2007 Aug; **15**: 238-43.
- 11 Steven Iew.D.Q.A.Nguyen. Nonsurgical volumetric periorbital rejuvenation; A plastic surgeons perspective. *Aesth Plast Surg* 2011; **35**: 319-325
- 12 Kim YJ, Choi KS. Bilateral blindness after filler injection. *Plast Reconstr Surg*. 2013; **131**: 298e-299e.
- 13 Park SW, Woo SJ, Park KH, et al. Iatrogenic retinal artery occlusion caused by cosmetic facial filler injections. *Am J Ophthalmol*. 2012; **154**: 653-662.e1.
- 14 Roberts SA, Arthurs BP. Severe visual loss and orbital infarction following periorbital aesthetic poly-(L, L)-lactic acid (PLLA) injection. *Ophthalmol Plast Reconstr Surg*. 2012; **28**: e68-e70.
- 15 Lee CM, Hong IH, Park SP. Ophthalmic artery obstruction and cerebral infarction following periocular injection of autologous fat. *Korean J Ophthalmol*. 2011; **25**: 358-361.
- 16 Park YH, Kim KS. Images in clinical medicine. Blindness after fat injections. *N Engl J Med*. 2011; **365**: 2220.
- 17 Kim YJ, Kim SS, Song WK, et al. Ocular ischemia with hypotony after injection of hyaluronic acid gel. *Ophthalmol Plast Reconstr Surg*. 2011; **27**: e152-e155.

Peer reviewer: Luca Negosanti, Centro Dermatologico Scientific Research Laboratory, Via Mazzini 2/2, 40138, Bologna, Italy.