

The Role of Coronary CT Angiography in Acute Coronary Syndromes

Azeem S Sheikh¹, Nadeem S Sheikh², Samira Yahya³

1 Consultant Interventional Cardiologist, Sandwell & West Birmingham Hospitals NHS Trust, Birmingham, UK;

2 Former Chairman and Dean Department of Pathology, Bolan University of Medical and Health Sciences, Quetta, Balochistan, Pakistan;

3 Former Senior Education Fellow, East Lancashire Hospitals NHS Trust, Blackburn, UK.

Conflict-of-interest statement: The author(s) declare(s) that there is no conflict of interest regarding the publication of this paper.

Open-Access: This article is an open-access article which was selected by an in-house editor and fully peer-reviewed by external reviewers. It is distributed in accordance with the Creative Commons Attribution Non Commercial (CC BY-NC 4.0) license, which permits others to distribute, remix, adapt, build upon this work non-commercially, and license their derivative works on different terms, provided the original work is properly cited and the use is non-commercial. See: <http://creativecommons.org/licenses/by-nc/4.0/>

Correspondence to: Azeem S Sheikh, Consultant Interventional Cardiologist, Sandwell & West Birmingham Hospitals NHS Trust, Dudley Road, Birmingham, B18 7QH, United Kingdom.
Email: drazeemsheikh@hotmail.com
Telephone: +44 121 507 4282

Received: November 16, 2021

Revised: December 1, 2021

Accepted: December 6 2021

Published online: December 15, 2021

ABSTRACT

Coronary CT angiography has become an important tool in evaluating patients presenting to the emergency department with acute chest pain. In patients with intermediate or low-risk of acute coronary syndrome, the current consensus recommends Coronary CT angiography for assessment of coronary artery disease. An understanding of the CT features of ACS can facilitate in making a prompt and precise diagnosis which would lead to better clinical outcomes in this cohort. We review the current evidence and the features of high-risk plaque on coronary CT angiography in this article.

Key words: Coronary CT angiography; CCTA; Acute coronary syndrome; Acute chest pain; Vulnerable plaques; High-risk plaques

© 2021 The Author(s). Published by ACT Publishing Group Ltd. All rights reserved.

Sheikh AS, Sheikh NS, Yahya S. The Role of Coronary CT Angiography in Acute Coronary Syndromes. *Journal of Cardiology and Therapy* 2021; **8(1)**: 981-986 Available from: URL: <http://www.ghrnet.org/index.php/jct/article/view/3239>

INTRODUCTION

Acute chest pain is one of the commonest presenting complaints in patients presenting to the emergency department (ED). It accounts for approximately 700 000 presentations to the ED per year in England and Wales and for 25% of emergency medical admissions^[1]. A prompt diagnosis and exclusion of acute coronary syndrome is crucially important as missed diagnosis is linked to poor clinical outcomes.

Patients presenting with non-ST elevation acute coronary syndrome (NSTACS) are categorized into high-risk and intermediate or low-risk for their tendency to progress to myocardial infarction or death based on their presentation, evolving ECG changes, cardiac biomarkers and haemodynamic instability^[2].

In high-risk acute coronary syndrome (ACS) cohort, an immediate coronary angiography with a view to intervene, if needed, should be performed as soon as possible, to try and salvage the viable myocardium. In patients with intermediate or low-risk of ACS, the current consensus recommends Coronary CT angiography for assessment of coronary artery disease^[3,4]. Table 1 shows the current guidelines on the use of Coronary CT angiography in patients with non-ST elevation Acute Coronary Syndrome.

The role of coronary CT angiography (CTA) in patients presenting with ACS gained significant importance during the course of COVID-19 pandemic^[5-7]. The diagnostic accuracy of 64 – slice coronary CTA has been scrutinized substantially in patients with stable coronary artery disease. Coronary CTA has distinctive sensitivity (>95%) and negative predictive value (>95%) with an outstanding specificity for the detection of coronary artery disease and helps in making a prompt diagnosis when compared with conventional functional testing^[8].

The recent trials have demonstrated that coronary CTA is a safe and an efficient way of discharging low-risk chest pain patients from

the emergency department^[9-11]. The CT-STAT (Coronary Computed Tomographic Angiography for Systematic Triage of Acute Chest Pain Patients to Treatment) trial revealed a 54% reduction in time to diagnosis and a 38% reduction in costs of care between coronary CTA and myocardial perfusion imaging with no difference in major adverse cardiac events (MACE) at 60 days^[9].

In the CT Angiography for Safe Discharge of Patients with Possible Acute Coronary Syndromes (ACRIN-PA) trial^[10], 50% increase in discharge was demonstrated without any increase in MACE at 30 days in a cohort with a normal coronary CTA when it was compared to the standard of care.

The ROMICAT II (Rule Out Myocardial Infarction/Ischemia Using Computer Assisted Tomography II) trial evaluated a strategy incorporating coronary CTA with standard care in assessing patients presenting to the emergency department with acute chest pain. The trial demonstrated that the patients in coronary CTA group had significantly shorter length of stay (8 versus 26 hours) and higher rates of direct discharge from the emergency department, and no significant difference in the rate of major adverse cardiac events at 28 days^[11]. Nonetheless, the cumulative costs at 28 days were noted to be higher in the coronary CTA group, as more patients in this cohort underwent further investigations after initial discharge.

The CATCH (Cardiac cT in the treatment of acute Chest pain) trial compared coronary CTA with standard care among 600 low-to-intermediate risk patients presenting to the emergency department with acute chest pain and the long-term clinical impact of coronary CT angiography-guided strategy was evaluated. The study demonstrated that the coronary CTA group had better clinical outcomes (composite of cardiac mortality, myocardial infarction, hospitalization for unstable angina, late-symptom-driven-revascularization, and readmission for chest pain) at a median follow-up of 18.7 months^[12].

At present, Coronary CTA may be more appropriate to the patients in the low-risk NSTEMI/ACS. Without elevated cardiac biomarkers and in the absence of recurrent chest pain, it is recommended that this cohort should undergo a stress test to look for evidence of inducible ischaemia. Coronary CTA is recommended in this cohort only if the stress test demonstrated significant ischaemia. Coronary CTA may replace the stress test as the first investigation in this cohort, if the stress testing is inconclusive. Table 2 shows the Coronary CTA protocol. Table 3 shows the pre-medications for Coronary CTA. Table 4 shows the contra-indications to Coronary CTA.

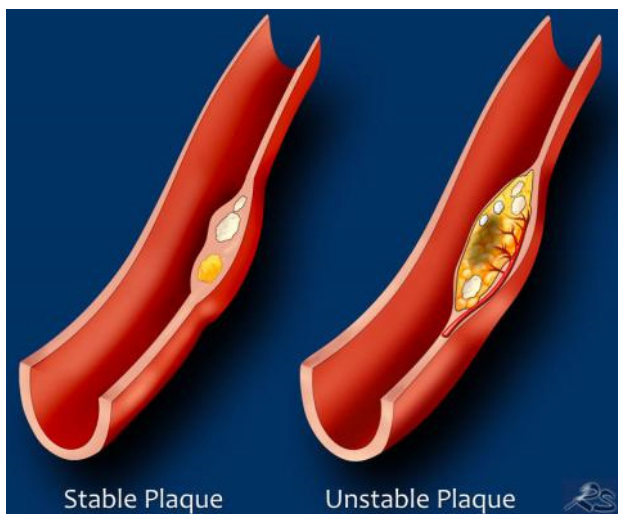

Figure 1 Features of stable and unstable/vulnerable plaque with thin-cap fibro-atheroma; gratefully acknowledged and reproduced from reference 29.

Table 1 Use of Coronary CT angiography in patients with non-ST elevation Acute Coronary Syndrome

Guideline	Recommendation	Evidence
2020 ESC guidelines[3]	CCTA is recommended as an alternative to invasive angiography to exclude ACS when there is a low-to-intermediate likelihood of CAD and when cardiac troponin and/or ECG are normal or inconclusive	Class I (Level of evidence A)
2014 AHA/ACC guidelines[4]	In patients with possible ACS and a normal ECG, normal cardiac troponins, and no history of CAD, it is reasonable to initially perform coronary CT angiography to assess coronary artery anatomy	Class IIa (Level of evidence A)

Table 2 Coronary CT Angiography protocol.

Administration of β - blockers - if the heart rate > 65 BPM
Administration of nitroglycerine
Prospective ECG - gating (or retrospectively gated helical mode).
Calcium score reported in the form of Agatston score
Post-processing: axial image review, multi-planar reformation and maximum intensity projection.
Optional image review: curved multi-planar reformation and volume rendered reconstruction.

Table 3 Pre-medications for Coronary CT angiography.

Check heart rate and blood pressure before administration of any medications
Administration of nitrates (400-800 μ g of sublingual nitroglycerin e.g. 1-2 sprays)
Administration of β -blocker (to target pulse of ≤ 65 bpm)
metoprolol 50-100 mg one hour before the exam
or metoprolol 5mg iv followed of monitoring for 5 min repeatedly up to 15-20 mg

Table 4 Contra-indications to Coronary CTA.

Absolute contraindications	Relative contraindications
Severe or anaphylactic reaction to contrast	Inability to control heart rate
Haemodynamic instability	Pregnancy
Severe renal impairment	Severe aortic stenosis
Acute myocardial infarction	Asthma
Decompensated heart failure	Morbid obesity
Contraindications to β-blockers	
2nd or 3rd-degree atrioventricular block	
Systolic blood pressure ≤ 90 mmHg	
Asthma	
Contraindications to nitrates	
Severe aortic stenosis	
Systolic blood pressure ≤ 90 mmHg	

Table 5 High-risk plaque features on Coronary CTA.

Feature	Definition
Positive remodelling	Outer vessel diameter at the plaque ≥ 1.1 times that of adjacent uninvolved vessel
Low attenuation plaque	Non-calcified plaque measuring < 30 HU, indicating a lipid core
Napkin-ring sign	Peripheral higher attenuation of the non-calcified portion of the plaque
Spotty calcium	Small calcified plaque (density ≥ 130 HU separately visualised from the lumen, diameter < 3 mm in any direction, but also length < 1.5 times vessel diameter and width $< 2/3$ times vessel diameter)

ROLE OF CORONARY CTA IN PREDICTING OUTCOMES

The published evidence suggests that a normal coronary CTA is associated with low major adverse cardiac events in the following years^[13]. The most notable characteristic of coronary CTA is in predicting magnificent outcomes in patients with normal results. The long-term data beyond 5 years demonstrates excellent prognosis for patients with normal coronary CTA with a negative likelihood ratio of 0.008 for MACE, with the risk for MACE increasingly exponentially as the plaque burden increases^[14-17].

CORONARY ABNORMALITIES ON CORONARY CT ANGIOGRAPHY

There is a strong evidence to suggest that acute myocardial infarction transpires not only from significantly stenotic lesions but from ‘vulnerable’ plaque irrespective of the degree of stenosis.

Plaques that are vulnerable to rupture are labelled as thin-cap fibro-atheroma which share identical histopathological features as ruptured plaques with the exception that the fibrous caps are nonetheless intact.

Thin-cap fibro-atheroma (TCFA) is widely recognised as a precursor for plaque rupture, which, in turn, is linked to the majority of cases of acute coronary syndrome. Histologically, TCFA is characterised as a large necrotic core with an overlying thin intact fibrous cap (<65 µm), macrophage infiltration and usually increased number of intra-plaque vasa vasorum^[18]. Figure 1 is a diagrammatic illustration of stable and unstable or vulnerable plaques. It has been shown that TCFA is a substantial predictor for expeditious development of angiographic stenosis (2) and a strong predictor of future cardiac events^[19,20]. The term “vulnerable plaque” has therefore been used to describe rupture prone plaques prior to the occurrence of an event^[20].

‘HIGH-RISK PLAQUE’ ON CORONARY CTA

The recent published work is more focussed on identifying plaque features that may determine its ‘high risk’ for rupture. Acute myocardial infarction is triggered by vulnerable plaque rupture ensuing in obstructive coronary artery stenosis or a complete occlusion. A culprit lesion is described as a 70% stenosis with non-calcified or a mixed calcified and non-calcified plaque accompanied by low attenuation plaque, positive remodelling, spotty calcification and the napkin-ring sign on coronary CTA. The high-risk plaque features on coronary CTA are shown in Table 5 and Figure 2(A - D).

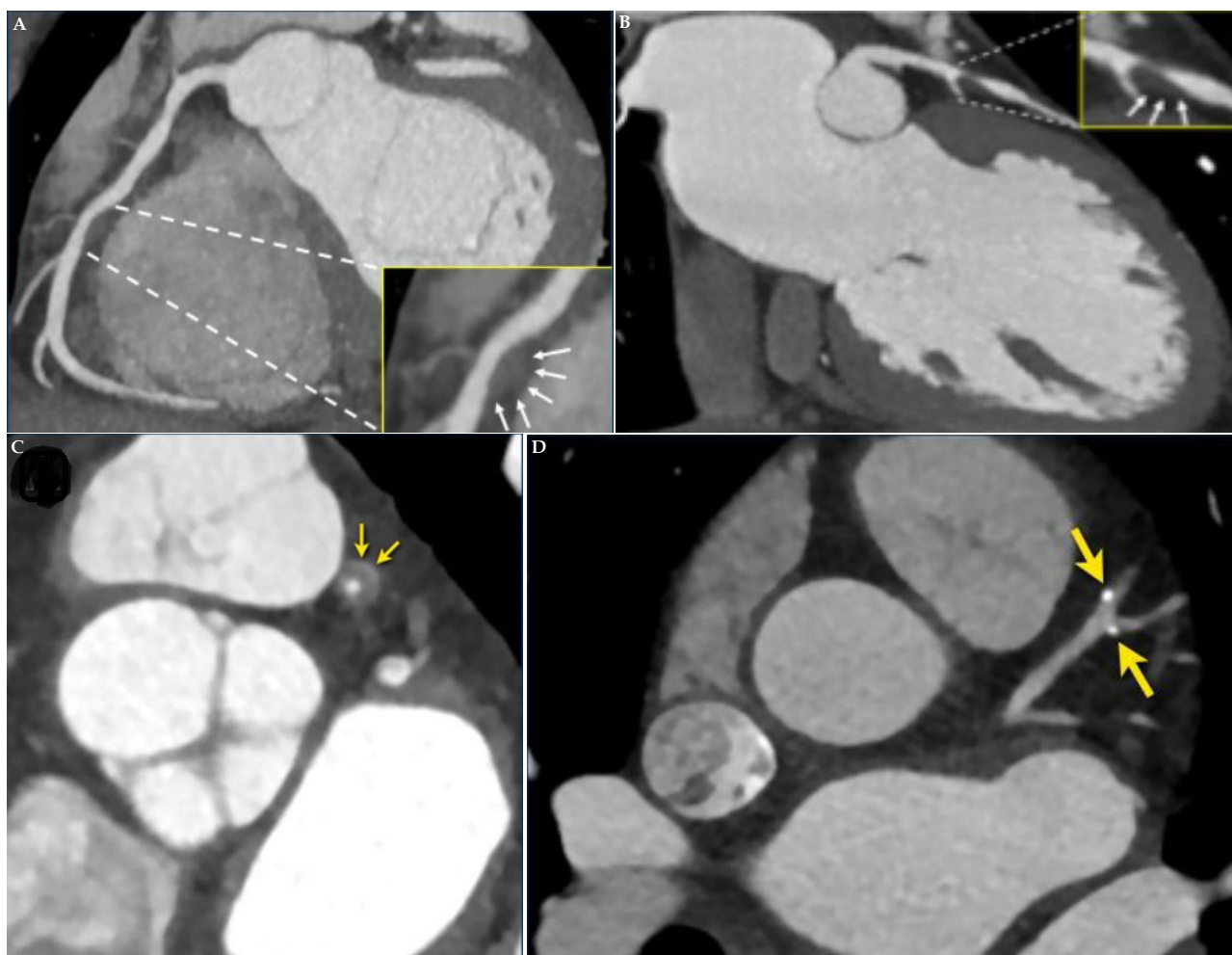


Figure 2 Illustrations showing high-risk plaque features on coronary CT angiography; gratefully acknowledged and reproduced from reference 29. A: Positive re-modelling: Positive remodelling of a non-calcified plaque in the mid right coronary artery. B: Low - attenuation plaque: Lesions associated with plaque rupture have a large lipid rich core, which appears as low attenuation. C: Napkin - ring sign: Central low attenuation area adjacent to the coronary lumen and a higher “ring-like” attenuation tissue surrounding this central area. D: Spotty calcification: Spotty calcifications are defined as calcifications <3 mm^[25].

When a patient present with acute coronary syndrome, two predominant variations occur within a precursor lesion vulnerable features^[21]. The first of these is tearing of the thin cap with resultant expulsion of the lipid core of the plaque into the bloodstream. The second variation is the formation of a thrombus at the site of the ruptured plaque.

In patients with ACS, Chun *et al*^[21] found no difference in the prevalence of features of low attenuation plaque and the napkin-ring sign among precursor and culprit lesions on coronary CTA. On the other hand, complete occlusion suggesting thrombus formation and myocardial hypo-attenuation seem to suggest that myocardial necrosis is more frequent in a culprit lesion as opposed to a precursor lesion on coronary CTA^[21].

CORONARY CTA FEATURES IN UNSTABLE ANGINA

The physiognomy of unstable angina on Coronary CTA mimics that of acute myocardial infarction; the only difference being the lack of wall motion abnormality and myocardial hypo-attenuation due to the absence of myocardial necrosis^[22].

Meijboom *et al*^[23] demonstrated that the sensitivity of detecting significant coronary stenoses on a patient-by-patient analysis was 100%, specificity 75%, and positive and negative predictive values were 96% and 100%, respectively. In segments where it was difficult to interpret due to heavy calcification, there was a tendency for observers to score these as positive for significant stenosis in order to reduce the chance of missing an important lesion. They suggested that this “defensive scoring” approach is also likely to be used in clinical practice when evaluating symptomatic patients. The high negative predictive value of the coronary CTA irrespective of significant coronary calcification and the high prevalence of coronary artery disease demonstrate that significant coronary disease can be ruled out with confidence in this cohort.

In view of the impressive negative predictive value^[23], a negative coronary CTA would cater for patients to be discharged confidently. The cohort with non-obstructive coronary artery disease on coronary CTA would continue to be managed conservatively, in conjunction with secondary prevention, and necessitating any future tests based on the symptomology.

VULNERABLE PLAQUE AND RISK OF FUTURE CARDIAC EVENT

Not all vulnerable plaques on coronary CTA result in ACS. Motoyama *et al*^[24] described that the manifestation of plaque progression on serial coronary CTA was linked to a heightened risk of cardiac event in future. The plaque progression is defined as an increasing size of lipid core or increasing amount of coronary stenosis of follow-up CT. This demonstrates that in order to predict a future cardiac event progression of vulnerable plaque morphology is pivotal than just a vulnerable plaque morphology seen on coronary CTA at a given time.

Motoyama *et al*^[25] matched coronary CTA features of 38 patients with acute coronary syndrome with 33 patients who had stable angina. The coronary morphological characteristics showed that the plaques in ACS group had higher frequency of non-calcified plaques < 30 Hounsfield Units (HU) (79% vs. 9%, $p < 0.0001$), spotty calcification (63% vs. 21%, $p = 0.0005$) and positive remodelling (87% vs. 12%, $p < 0.0001$). The presence of all three

features exhibited a high positive predictive value, and their absence demonstrated a high negative predictive value for future cardiac events.

Motoyama *et al*^[26], in a large prospective study with a cohort of 1,059 patients, described that coronary CTA features of low-attenuation plaque and positive remodelling were linked with the subsequent occurrence of acute coronary events. ACS occurred in 10/45 (22%) who had these two features on coronary CTA compared with 4/820 (0.5%) who did not have these features. It was important to note that none of the 167 patients who had normal coronary CTA sustained acute cardiac events ($p < 0.001$).

Kashiwagi *et al*^[27] suggested that presence of a ring-like attenuation on coronary CTA may be a surrogate marker of TCFA after contemplating OCT and coronary CTA findings. They studied 105 patients with coronary artery disease and divided the cohort into TCFA and non-TCFA group according to the OCT findings. Coronary CTA-verified positive remodelling was detected more often in the TCFA (75%) than in the non-TCFA group (30%, $p < 0.001$). The TCFA group also exhibited LAP more frequently; CT attenuation value in the TCFA group (35 ± 32 HU) was significantly lower than the non-TCFA group (62 ± 34 HU, $p < 0.001$). Exceptionally a ring-like attenuation in the TCFA group was found to be 11-fold more frequent than in the non-TCFA group (44% vs. 4%, $p < 0.001$). The sensitivity, specificity, positive predictive value and negative predictive value of ring-like enhancement for detecting TCFA are 44%, 96%, 79%, and 85%, respectively^[28].

CONCLUSIONS

Coronary CTA is a reliable diagnostic tool of excluding ACS in low-to-intermediate risk cohort in view of its high negative predictive value. An understanding of the CT features of ACS can facilitate in making a prompt and precise diagnosis which would lead to better clinical outcomes in this cohort.

REFERENCES

1. Goodacre S, Cross E, Arnold J, Angelini K, Capewell S, Nicholl J. The health care burden of acute chest pain. *Heart*. 2005;91:229–230. [DOI: 10.1136/hrt.2003.027599]; [PMID: 15657244]; [PMCID: PMC1768669].
2. Bertrand ME, Simoons ML, Fox KA, Wallentin LC, Hamm CW, McFadden E, De Feyter PJ, Specchia G, Ruzyllo W; Task Force on the Management of Acute Coronary Syndromes of the European Society of Cardiology. Management of acute coronary syndromes in patients presenting without persistent ST-segment elevation. *Eur Heart J*. 2002 Dec;23(23):1809–40. [DOI: 10.1053/ehj.2002.3385]; [PMID: 12503543].
3. Collet JP, Thiele H, Barbato E, Barthélémy O, Bauersachs J, Bhatt DL, Dendale P, Dorobantu M, Edvardsen T, Folliguet T, Gale CP, Gilard M, Jobs A, Jüni P, Lambrinou E, Lewis BS, Mehilli J, Meliga E, Merkely B, Mueller C, Roffi M, Rutten FH, Sibbing D, Siontis GCM; ESC Scientific Document Group. 2020 ESC Guidelines for the management of acute coronary syndromes in patients presenting without persistent ST-segment elevation. *Eur Heart J*. 2021 Apr 7;42(14):1289–1367. [DOI: 10.1093/eurheartj/ehaa575]; [PMID: 32860058].
4. Amsterdam EA, Wenger NK, Brindis RG, Casey DE Jr, Ganiats TG, Holmes DR Jr, Jaffe AS, Jneid H, Kelly RF, Kontos MC, Levine GN, Liebson PR, Mukherjee D, Peterson ED, Sabatine MS, Smalling RW, Zieman SJ; ACC/AHA Task Force Members. 2014 AHA/ACC guideline for the management of patients with non-ST-elevation acute coronary syndromes: a report of the American College of Cardiology/American Heart Associa-

- tion Task Force on Practice Guidelines. *Circulation*. 2014 Dec 23;130(25):e344-426. [DOI: 10.1161/CIR.000000000000134]; [PMID: 25249585].
5. Task Force for the management of COVID-19 of the European Society of Cardiology. ESC guidance for the diagnosis and management of cardiovascular disease during the COVID-19 pandemic: part 2-care pathways, treatment, and follow-up. *Eur Heart J*. 2021 Nov 16;ehab697. [DOI: 10.1093/eurheartj/ehab697]. Epub ahead of print. [PMID: 34791154].
 6. Choi AD, Abbara S, Branch KR, Feuchtner GM, Ghoshhajra B, Nieman K, Pontone G, Villines TC, Williams MC, Blankstein R. Society of Cardiovascular Computed Tomography guidance for use of cardiac computed tomography amidst the COVID-19 pandemic Endorsed by the American College of Cardiology. *J Cardiovasc Comput Tomogr*. 2020 Mar-Apr;14(2):101-104. [DOI: 10.1016/j.jcct.2020.03.002]. Epub 2020 Mar 21. [PMID: 32317235]; [PMCID: PMC7102563].
 7. Mahmud E, Dauerman HL, Welt FGP, Messenger JC, Rao SV, Grines C, Mattu A, Kirtane AJ, Jauhar R, Meraj P, Rokos IC, Rumsfeld JS, Henry TD. Management of Acute Myocardial Infarction During the COVID-19 Pandemic: A Position Statement From the Society for Cardiovascular Angiography and Interventions (SCAI), the American College of Cardiology (ACC), and the American College of Emergency Physicians (ACEP). *J Am Coll Cardiol*. 2020 Sep 15;76(11):1375-1384. [DOI: 10.1016/j.jacc.2020.04.039]. Epub 2020 Apr 21. [PMID: 32330544]; [PMCID: PMC7173829].
 8. Hulten E, Pickett C, Bittencourt MS, Villines TC, Petrillo S, Di Carli MF, Blankstein R. Outcomes after coronary computed tomography angiography in the emergency department: a systematic review and meta-analysis of randomized, controlled trials. *J Am Coll Cardiol*. 2013 Feb 26;61(8):880-92. [DOI: 10.1016/j.jacc.2012.11.061]. Epub 2013 Feb 6. [PMID: 23395069].
 9. Goldstein JA, Chinnaiyan KM, Abidov A, Achenbach S, Berman DS, Hayes SW, Hoffmann U, Lesser JR, Mikati IA, O'Neil BJ, Shaw LJ, Shen MY, Valeti US, Raff GL; CT-STAT Investigators. The CT-STAT (Coronary Computed Tomographic Angiography for Systematic Triage of Acute Chest Pain Patients to Treatment) trial. *J Am Coll Cardiol*. 2011 Sep 27;58(14):1414-22. [DOI: 10.1016/j.jacc.2011.03.068]; [PMID: 21939822].
 10. Litt HI, Gatsonis C, Snyder B, Singh H, Miller CD, Entrikin DW, Leaming JM, Gavin LJ, Pacella CB, Hollander JE. CT angiography for safe discharge of patients with possible acute coronary syndromes. *N Engl J Med*. 2012 Apr 12;366(15):1393-403. [DOI: 10.1056/NEJMoa1201163]. Epub 2012 Mar 26. [PMID: 22449295].
 11. Hoffmann U, Truong QA, Schoenfeld DA, Chou ET, Woodard PK, Nagurny JT, Pope JH, Hauser TH, White CS, Weiner SG, Kalanjian S, Mullins ME, Mikati I, Peacock WF, Zakrotsky P, Hayden D, Goehler A, Lee H, Gazelle GS, Wiviott SD, Fleg JL, Udelson JE; ROMICAT-II Investigators. Coronary CT angiography versus standard evaluation in acute chest pain. *N Engl J Med*. 2012 Jul 26;367(4):299-308. [DOI: 10.1056/NEJMoa1201161]. [PMID: 22830462]; [PMCID: PMC3662217].
 12. Linde JJ, Hove JD, Sørgaard M, Kelbæk H, Jensen GB, Kühl JT, Hindso L, Køber L, Nielsen WB, Kofoed KF. Long-Term Clinical Impact of Coronary CT Angiography in Patients With Recent Acute-Onset Chest Pain: The Randomized Controlled CATCH Trial. *JACC Cardiovasc Imaging*. 2015 Dec;8(12):1404-1413. [DOI: 10.1016/j.jcmg.2015.07.015]. Epub 2015 Nov 11. [PMID: 26577263].
 13. Jones RL, Thomas DM, Barnwell ML, Fentanec E, Young AN, Barnwell R, Foley AT, Hilliard M, Hulten EA, Villines TC, Cury RC, Slim AM. Safe and rapid disposition of low-to-intermediate risk patients presenting to the emergency department with chest pain: a 1-year high-volume single-center experience. *J Cardiovasc Comput Tomogr*. 2014 Sep-Oct;8(5):375-83. [DOI: 10.1016/j.jcct.2014.08.003]. Epub 2014 Aug 19. [PMID: 25301043].
 14. Andreini D, Pontone G, Mushtaq S, Bartorelli AL, Bertella E, Antonioli L, Formenti A, Cortinovis S, Veglia F, Annoni A, Agostoni P, Montorsi P, Ballerini G, Fiorentini C, Pepi M. A long-term prognostic value of coronary CT angiography in suspected coronary artery disease. *JACC Cardiovasc Imaging*. 2012 Jul;5(7):690-701. [DOI: 10.1016/j.jcmg.2012.03.009]; [PMID: 22789937].
 15. Ostrom MP, Gopal A, Ahmadi N, Nasir K, Yang E, Kakadiaris I, Flores F, Mao SS, Budoff MJ. Mortality incidence and the severity of coronary atherosclerosis assessed by computed tomography angiography. *J Am Coll Cardiol*. 2008 Oct 14;52(16):1335-43. [DOI: 10.1016/j.jacc.2008.07.027]; [PMID: 18929245].
 16. Fazel P, Peterman MA, Schussler JM. Three-year outcomes and cost analysis in patients receiving 64-slice computed tomographic coronary angiography for chest pain. *Am J Cardiol*. 2009 Aug 15;104(4):498-500. [DOI: 10.1016/j.amjcard.2009.04.011]. Epub 2009 Jun 24. [PMID: 19660601].
 17. Hulten EA, Carbonaro S, Petrillo SP, Mitchell JD, Villines TC. Prognostic value of cardiac computed tomography angiography: a systematic review and meta-analysis. *J Am Coll Cardiol*. 2011 Mar 8;57(10):1237-47. [DOI: 10.1016/j.jacc.2010.10.011]. Epub 2010 Dec 8. [PMID: 21145688].
 18. Go AS, Mozaffarian D, Roger VL, Benjamin EJ, Berry JD, Borden WB, Bravata DM, Dai S, Ford ES, Fox CS, Franco S, Fullerton HJ, Gillespie C, Hailpern SM, Heit JA, Howard VJ, Huffman MD, Kissela BM, Kittner SJ, Lackland DT, Lichtman JH, Lisabeth LD, Magid D, Marcus GM, Marelli A, Matchar DB, McGuire DK, Mohler ER, Moy CS, Mussolino ME, Nichol G, Paynter NP, Schreiner PJ, Sorlie PD, Stein J, Turan TN, Virani SS, Wong ND, Woo D, Turner MB; American Heart Association Statistics Committee and Stroke Statistics Subcommittee. Executive summary: heart disease and stroke statistics--2013 update: a report from the American Heart Association. *Circulation*. 2013 Jan 1;127(1):143-52. [DOI: 10.1161/CIR.0b013e318282ab8f]; [PMID: 23283859].
 19. Narula J, Finn AV, Demaria AN. Picking plaques that pop. *J Am Coll Cardiol*. 2005 Jun 21;45(12):1970-3. [DOI: 10.1016/j.jacc.2005.03.034]; [PMID: 15963394].
 20. Muller JE, Abela GS, Nesto RW, Tofler GH. Triggers, acute risk factors and vulnerable plaques: the lexicon of a new frontier. *J Am Coll Cardiol*. 1994 Mar 1;23(3):809-13. [DOI: 10.1016/0735-1097(94)90772-2]; [PMID: 8113568].
 21. Chun EJ, Han JH, Yoo SM, Lee HY, Song IS, White CS. Differences in the CT findings between vulnerable plaque and culprit lesions in acute coronary syndrome. *J Cardiovasc Comput Tomogr*. 2018 Mar-Apr;12(2):115-117. [DOI: 10.1016/j.jcct.2018.01.001]. Epub 2018 Jan 5. [PMID: 29330042].
 22. Son MJ, Yoo SM, Lee D, Lee HY, Song IS, Chun EJ, White CS. Current Role of Computed Tomography in the Evaluation of Acute Coronary Syndrome. *Diagnostics (Basel)*. 2021 Feb 9;11(2):266. [DOI: 10.3390/diagnostics11020266]; [PMID: 33572267]; [PMCID: PMC7914414].
 23. Meijboom WB, Mollet NR, Van Mieghem CA, Weustink AC, Pugliese F, van Pelt N, Cademartiri F, Vourvouri E, de Jaegere P, Krestin GP, de Feyter PJ. 64-Slice CT coronary angiography in patients with non-ST elevation acute coronary syndrome. *Heart*. 2007 Nov;93(11):1386-92. [DOI: 10.1136/hrt.2006.112771]. Epub 2007 Mar 7. [PMID: 17344332]; [PMCID: PMC2016889].
 24. Motoyama S, Ito H, Sarai M, Kondo T, Kawai H, Nagahara Y, Harigaya H, Kan S, Anno H, Takahashi H, Naruse H, Ishii J, Hecht H, Shaw LJ, Ozaki Y, Narula J. Plaque Characterization by Coronary Computed Tomography Angiography and the Likelihood of Acute Coronary Events in Mid-Term Follow-Up. *J Am Coll Cardiol*. 2015 Jul 28;66(4):337-46. [DOI: 10.1016/j.jacc.2015.05.069]; [PMID: 26205589].
 25. Motoyama S, Kondo T, Sarai M, Sugiura A, Harigaya H, Sato T, Inoue K, Okumura M, Ishii J, Anno H, Virmani R, Ozaki Y, Hishida H, Narula J. Multislice computed tomographic char-

- acteristics of coronary lesions in acute coronary syndromes. *J Am Coll Cardiol.* 2007 Jul 24;50(4):319-26. [DOI: 10.1016/j.jacc.2007.03.044]; Epub 2007 Jul 6. [PMID: 17659199].
26. Motoyama S, Sarai M, Harigaya H, Anno H, Inoue K, Hara T, Naruse H, Ishii J, Hishida H, Wong ND, Virmani R, Kondo T, Ozaki Y, Narula J. Computed tomographic angiography characteristics of atherosclerotic plaques subsequently resulting in acute coronary syndrome. *J Am Coll Cardiol.* 2009 Jun 30;54(1):49-57. [DOI: 10.1016/j.jacc.2009.02.068]; [PMID: 19555840].
 27. Kashiwagi M, Tanaka A, Kitabata H, Tsujioka H, Kataiwa H, Komukai K, Tanimoto T, Takemoto K, Takarada S, Kubo T, Hirata K, Nakamura N, Mizukoshi M, Imanishi T, Akasaka T. Feasibility of noninvasive assessment of thin-cap fibroatheroma by multidetector computed tomography. *JACC Cardiovasc Imaging.* 2009 Dec;2(12):1412-9. [DOI: 10.1016/j.jcmg.2009.09.012]; [PMID: 20083077].
 28. Andreini D, Pontone G, Mushtaq S, Pepi M, Bartorelli AL. Multidetector computed tomography coronary angiography for the assessment of coronary in-stent restenosis. *Am J Cardiol.* 2010 Mar 1;105(5):645-55. [DOI: 10.1016/j.amjcard.2009.10.046]; [PMID: 20185011].
 29. Celeng C, Takx R, Smithuis R, Leiner T. Coronary Artery Disease-Reporting and Data System: Examples for the different Cad-Rads categories; *The Radiology Assistant* (accessed on Dec 2, 2021)