

## A Painful Sleep Apnea

Sofia Morra, François Bughin, Kamila Solecki, François Roubille

Sofia Morra, François Bughin, Kamila Solecki, François Roubille, Department of Cardiology, University Hospital of Montpellier, Montpellier, France

Sofia Morra, Departement of Cardiac, Thoracic and Cardiovascular Sciences, University of Padua Medical School, via Giustiniani 2, 35121, Padova, Italy

François Roubille, PhyMedExp, University of Montpellier, INSERM U1046, CNRS UMR 9214. 34295 Montpellier, France

Correspondence to: François Roubille, MD, PhD., Department of Cardiology, Hôpital Arnaud de Villeneuve, CHU de Montpellier, UFR de Médecine, Université Montpellier 1, 371, avenue du Doyen Gaston Giraud, 34295 Montpellier cedex 05, France

Email: [francois.roubille@gmail.com](mailto:francois.roubille@gmail.com)

Telephone: +39-3403335699

Received: September 3, 2015 Revised: November 19, 2015

Accepted: November 22, 2015

Published online: February 14, 2016

### ABSTRACT

**BACKGROUND:** Obstructive sleep apnea (OSA) is largely recognized as an independent risk factor for coronary artery disease (CAD), its prevalence is higher in the acute phase of ischemic heart disease and the risk of developing ischemic myocardial injury is greater in presence of this syndrome. OSA seems to exacerbate ischemic nocturnal events, to impair coronary blood flow (CBF) response to myocardial energy demand, to increase myocardial vascular resistance and to negatively impact outcomes of percutaneous coronary intervention (PCI)

**CASE REPORT:** We reported the case of 57-years-old men with multiples cardiovascular risk factors and previous history of severe CAD, who presented multiples relapses of in-stent restenosis and failure in percutaneous procedures; because of overweight, snoring and nocturnal pains referred occurring simultaneously of respiratory apneic events, he underwent to an overnight sleep screening, resulting positive for obstructive sleep apnea.

**CONCLUSIONS:** OSA, likewise others chronic inflammatory states, could be responsible for negative outcomes of PCI(in-stent

proliferation restenosis) due to abnormal inflammatory state, coronary microvascular dysfunction secondary to vascular remodeling, and thus ineffectiveness of coronary blood flow (CBF) response to myocardial work.

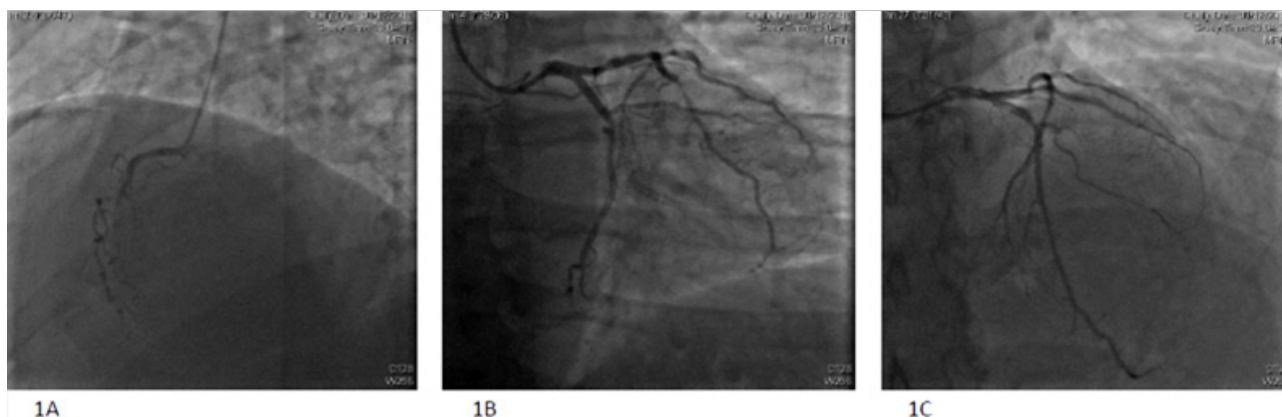© 2016 ACT. All rights reserved.

**Key words:** Ostructive apnea; Intermittent hypoxia; Coronary artery disease

Morra S, Bughin F, Solecki K, Roubille F. A Painful Sleep Apnea. *Journal of Cardiology and Therapy* 2016; 3(1): 500-503 Available from: URL: <http://www.ghrnet.org/index.php/jct/article/view/1602>

### Abbreviations

AHI: Apnea-Hypopnea Index;  
BP: Blood Pressure;  
CBF: Coronary Blood Flow;  
CFR: Coronary Flow Reserve;  
CMR: Cardiovascular Magnetic Resonance;  
CRP: C-reactive protein;  
DP: Double Product;  
ECG: Electrocardiogram;  
FFR: Fractional Flow Reserve;  
IHD: Ischemic Heart Disease;  
HR: Heart rate;  
LAD: Left Anterior Descending artery;  
LV: Left Ventricle;  
LVEF: Left Ventricle Ejection Fraction;  
MI: Myocardial Infarction;  
OCT: Optical Coherence Tomography;  
OSAS: Obstructive Sleep Apnea Syndrome;  
RAC: Right Coronary Artery;  
RBBB: Right Bundle Branch Block;  
RV: Right Ventricle;  
STEMI: ST-segment Elevation Myocardial Infarction;  
PCI: Percutaneous Coronary Intervention.



**Figures 1A.** Chronic occlusion of right coronary artery; **1B.** Sub-occlusion of left descending artery (LAD) due to in-stent proliferation re-stenosis and in-stent chronic occlusion of marginal artery; **1C** Successfully result of percutaneous coronary intervention (PCI) both on LAD and marginal arteries.

## INTRODUCTION

Obstructive sleep apnea (OSA) is a common sleep disorder breathing (SDB) frequently found in general population<sup>[1]</sup> and even higher in cardiovascular patients<sup>[2-6]</sup>. OSA seems to be strongly related to coronary artery disease (CAD), its prevalence is very high in coronary patients<sup>[7,8]</sup> and negatively affects short<sup>[9]</sup> and long-term<sup>[10]</sup> prognosis following the acute phase of ischemic heart disease (IHD). Sudden death for cardiovascular causes seems to be 2-fold higher in apneic patients than in general population, mainly occurring between midnight and 6 a.m. contrary to control population in which mainly occurs between 6 a.m. and 12 p.m.<sup>[11]</sup>.

Nowadays, evidences support OSA to be an independent risk factor for CAD<sup>[12]</sup>, and in this context its presence seems to exacerbate nocturnal ischemic events (both thoracic pain and ST-segment modifications), that occurs mainly in the early morning (5.00 to 7.00 a.m.)<sup>[13]</sup> and it seems that coronary blood flow (CBF) response to the increased myocardial O<sub>2</sub> demand is impaired<sup>[14]</sup>. Moreover, OSA seems to be linked to negative outcomes following percutaneous coronary intervention (PCI)<sup>[16]</sup>.

## CASE PRESENTATION

A 57-years old man smoker, diabetic, dyslipidemic, with a family history of ischemic heart disease (IHD), presented to our hospital for anterior ST-segment Elevation Myocardial Infarction (STEMI). He was given Clopidogrel 75 mg, Acetylsalicylic Acid 75 mg, Ramipril 10mg, Atenolol 50 mg × 2, Atorvastatin 40mg, Nitroglycerin at need.

His medical history was marked by myocardial infarction (MI) in 2005 treated by PCI on left anterior descending artery (LAD) and marginal coronary artery, followed by an in-stent restenosis 2 years later into both arteries and treated with intra-stent implantation.

Coronary artery angiogram revealed a multitruncular coronary artery disease: chronic occlusion of right coronary artery (RCA) and marginal artery; sub-occlusion of LAD due to a proliferative in-stent restenosis. Both LAD and marginal artery were treated with active balloon, with a successfully result (Figures 1A, 1B, 1C).

Echocardiography post-catheterization showed a left ventricle ejection fraction (LVEF) of 35-40% with hypokinesia in lateral, inferior, and infer-lateral territories.

Another coronary catheterization performed 48 hours later showed an occlusion of the marginal artery, so that medical treatment was chosen regarding marginal and RCA arteries.

Echocardiography performed before patient hospital discharge showed a promising evolution with a LVEF of 45% with anterolateral

akinesia. The Cardiovascular magnetic resonance (CMR) showed ischemic lesions in inferior and lateral territories but with normal EF.

Medical treatment at the discharge consisted of: Clopidogrel 75 mg, Acetylsalicylic Acid 75 mg, Ramipril 5 mg, Atenolol 50 mg, Atorvastatin 80mg, Metformine 500 mg × 2, Esomeprazole 40 mg.

Two weeks later, Mr. T. was hospitalized again because of persistence of thoracic pain at rest. An additional PCI was performed on the LAD1 with kissing on the LAD and the diagonal branch. Medical treatment at the discharge was unchanged except switch Clopidogrel 75mg with Ticagrelor 90mg.

Nevertheless, because of persistence of thoracic pain, myocardial scintigraphy was performed two months later, showing extensive ischemia in antero-lateral, infero-lateral and inferior territories (Figure 2) although the LVEF and volumes were normal both at physical exertion and rest.

Another coronary angiogram revealed significant residual stenosis on LAD when evaluated by the fractional flow reserve (FFR) method. Because of multiples and severe coronary lesions difficult to revascularize by PCI, the possibility to revascularize efficiently at least the LAD and the circumflex arteries, the persistence of symptoms, the patient was offered a coronary artery bypass graft as the best therapeutic strategy. The patient refused this option.

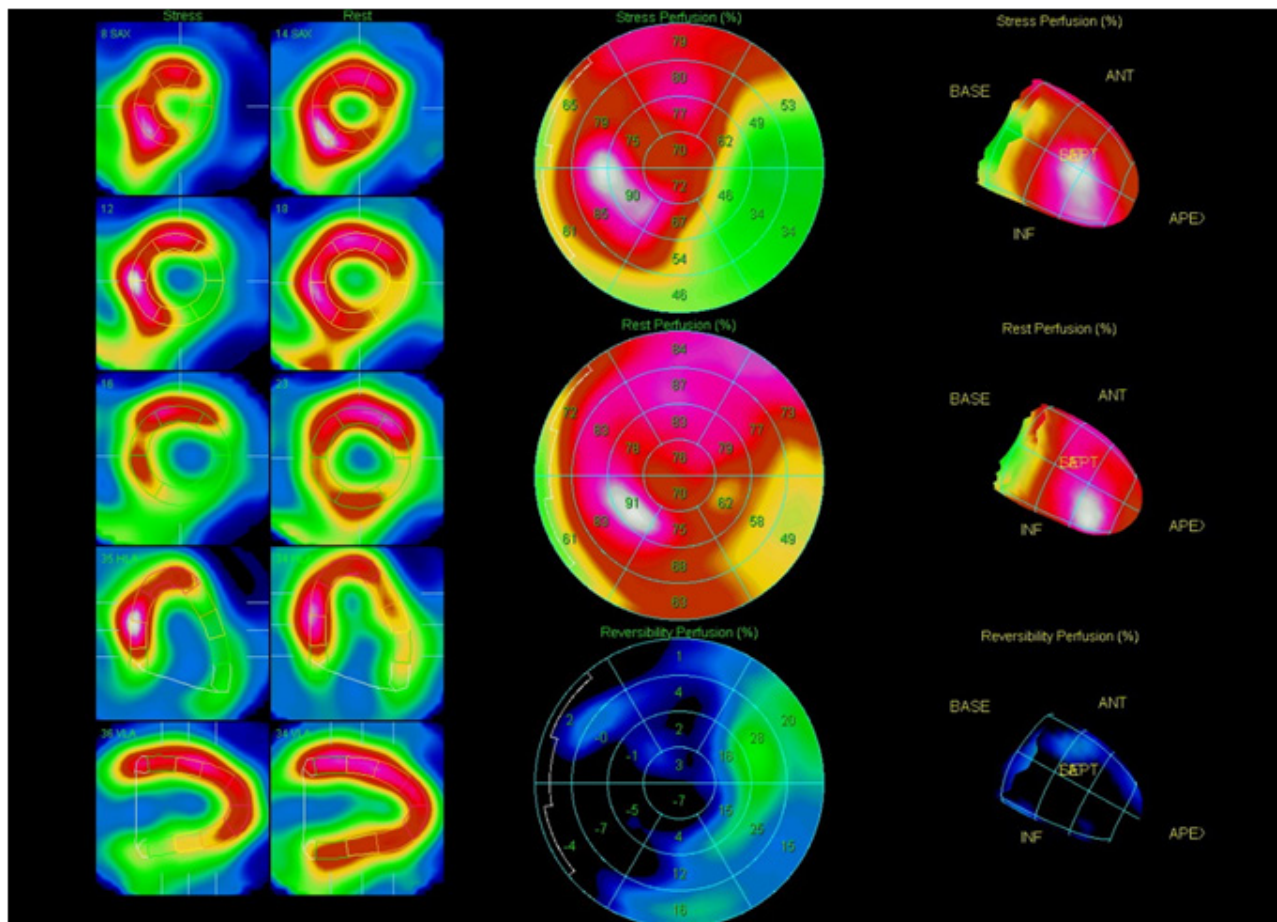
One year later, because of persistent pains, a new coronary angiogram confirmed the lesions and a new myocardial scintigraphy evidenced a contractile dysfunction on lateral and inferior territories. A PCI was attempted to treat the chronic total occlusion but failed.

Because of overweight, snoring and nocturnal pains, he underwent an overnight sleep study for the detection of obstructive sleep apnea. Nocturnal chest pains occurred simultaneously to obstructive respiratory events. The test was positive for obstructive sleep apnea, with an apnea-hypopnea index (AHI) of 23 per hour of sleep and a desaturation index of 21 per hour of sleep. The patient refused further investigations regarding the sleep apnea syndromes.

## DISCUSSION

In this case report, two aspects deserve to be analyzed: multiple in-stent restenosis and above all nocturnal thoracic pains simultaneously to obstructive sleep apnea.

The medical history was heavily marked by frequently in-stent proliferation and failure in percutaneous procedures: this could be explained by the abnormal inflammation response found in OSA condition, promoting thrombosis and early neo-intimal hyperplasia following PCI. Indeed, OSA has been suggested as an independent risk factor for negative angiographic outcomes after PCI<sup>[16]</sup>: as



**Figures 2** Myocardial scintigraphy showing extensive ischemia in antero-lateral, infero-lateral and inferior territories, with normal left ventricle ejection fraction (LVEF) and volumes are normal both at physical exertion and rest..

shown in Yumino *et al's* study, OSA is associated with a higher binary restenosis rate, and higher luminal late loss after percutaneous procedures.

This tendency to develop in-stent restenosis could be explained by the abnormal oxidative stress as well as the inflammatory response linked to the apneic events, promoting local inflammation and thus in-stent proliferation.

Secondly, during an obstructive apneic event, several hemodynamic changes in myocardial flow and perfusion occur.

Throughout the obstructive apneic event, similarly to a physical effort, myocardial energy demand increases secondary to both hemodynamic and metabolic changes. The rise both in heart rate and blood pressure due to the abnormal adrenergic system activation results in an increasing in myocardial consumption. Also the variations in intrathoracic pressure, due to persistent respiratory efforts against the occluded upper airways, are responsible for the increase in  $O_2$  demand: increased difference between intra and extra-cardiac pressure and so, in the left ventricular transmural gradient, results in an increasing in LV wall tensions and again, in LV afterload. On the other hand, during obstructive respiratory events, a transient mismatch between coronary blood flow (CBF) and myocardial work seems to occur<sup>[14]</sup>.

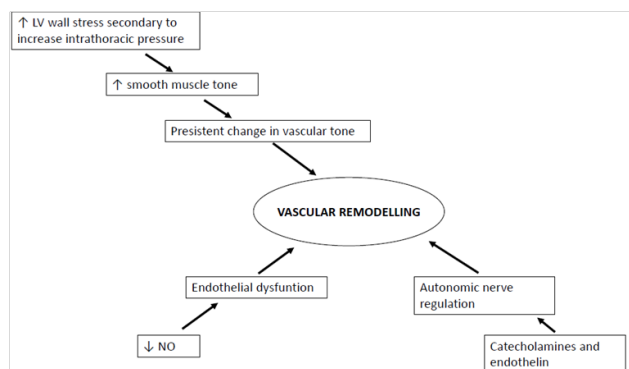
The imbalance between myocardial  $O_2$  demand secondary to the increased LV afterload and myocardial  $O_2$  supply secondary to the inadequate response of CBF to myocardial work, could reasonably explain the thoracic pains reported by patient during the apneic events.

Both LV compliance and LV end-diastolic volume decrease as consequence of increased venous return due to the negative intrathoracic pressure; this could lead to an increase in the LV end-diastolic pressure, in a reduction in the coronary  $\Delta P$  and thus CBF, that could be inadequate to the increased myocardial work occurring throughout the obstructive event.

Nevertheless, this impairment in CBF could also be the consequence of an increase in coronary vascular resistance. The increase in coronary vascular resistance is responsible for a reduction in CBF at maximal vasodilation, resulting in a dysfunction of coronary flow reserve ( $CFR = CBF$  at maximal vasodilation/  $CBF$  at rest). Accordingly, Wang *et al.* show an inverse relationship between CFR and the severity of OSA and an increase odds of having low CFR as the AHI rises<sup>[15]</sup>.

Maybe, the key linking OSA to microvascular dysfunction, expressed as an impaired CFR, is the inflammatory state. As well as high levels of C-reactive protein (CRP) are linked to lower CFR<sup>[17]</sup>, and in OSA condition there are great plasma levels of CRP<sup>[18]</sup>, inflammation could be responsible for the impairment of CFR observed in OSA state, likewise other chronic inflammatory diseases. Finally, increased coronary vascular resistance could be the consequence of vascular remodeling. In OSA condition, several mechanisms could be associated with vascular remodeling, as result of long-term vascular adaptation as explained in the following figure (Figure 3).

In conclusion, nocturnal thoracic pains occurring simultaneously to obstructive respiratory events could be the consequence of an



**Figure 3** Possible multiples mechanisms explaining vascular remodeling of small arteries vessels in myocardial muscle, leading to microvascular dysfunction. The increased LV wall stress due to intrathoracic negative pressure is a strong stimulus to vascular tone changing mainly by the myogenic response; the persistent increased vascular tone drives long-term vascular adaptation by structural remodeling. Also endothelial dysfunction secondary to the lower bioavailability of NO could pave the way to vascular remodeling. Lastly, vascular remodeling could be promoted also by an increase activity in catecholamines and endothelin systems.

imbalance of O<sub>2</sub> supply and O<sub>2</sub> demand ratio, secondary to both an increased O<sub>2</sub> demand following LV increased afterload, and an impairment of CBF, due to both hemodynamics changes and microvascular dysfunction.

In-stent restenosis may be also the consequence of the inflammatory state linking to OSA condition.

## CONFLICT OF INTEREST

There are no conflicts of interest with regard to the present study.

## REFERENCES

- Young T., Palta M., Dempsey J., Skatrud J., Weber S., Badr S. The occurrence of sleep-disordered breathing among middle-aged adults. *NEJM* 1993;328(17):1230-1235.
- Douglas T.B., John S. Floras. Obstructive sleep apnea and its cardiovascular consequences. seminar. *The Lancet* 2009;373:82-83.
- Paulino A., Damy T., Margarit L., Stoica M., et al. Prevalence of sleep disordered breathing in 316- patients french cohort of stable congestive heart failure. *Arch Cardiovasc Disc* 2009;102(3):169-175.
- Oldenburg O., Lamp B, Faber L, Teschler H, Horstkotte D, Töpfer V. Sleep disordered breathing in patients with symptomatic heart failure: A contemporary study of prevalence and characteristic of 700 patients. *Eur J Hear Fail* 2007;9(3):251-257.
- Guilleminault C, Conolly ST, Winkle RA. Cardiac arrhythmias and conduction disturbances during sleep in 400 patients with sleep apnea syndrome. *Am J Cardiol* 1983;52(5):490-494.
- Parish J.M. SVK. Obstructive sleep apnea and cardiovascular disease. review. *Mayo Clin Proc* 2014;79(8):1036-1046.
- Lee CH., Khoo SM, Tai BC, Chong EY, Lau C, Than Y, Shi DX, Lee LC, Kailasam A, Low AF, Teo SG, Tan HC. Obstructive sleep apnea in patients admitted for acute myocardial infarction. prevalence, predictors, and effect on microvascular perfusion.. *Chest* 2009;135:1488-1495.
- T. Konecny, F. H. Sert Kuniyoshi, M. Orban et al. Under-diagnosis of sleep apnea in patients after acute myocardial infarction. *Journal of the American College of Cardiology* 2010;56(9):742-743.
- Barbé F., Sánchez-de-la-Torre A., Abad J., Durán-Cantolla J., Mediano O., Amilibia J., Masdeu MJ., Florès M., Barceló A., de la Peña M., Aldomá A., Worner F., Valls J., Castellà G., Sánchez-de-la-Torre M. Effect of obstructive sleep apnea on severity and short-term prognosis of acute coronary syndrome. *Eur Respi J* 2015;45:419-427.
- Daniel J. Gottlieb Gayane Yenokyan, Anne B. Newman, George T. O'Connor, Naresh M. Punjabi, Stuart F. Quan, Susan Redline, Helaine E. Resnick, Elisa K. Tong, Marie Diener-West, Eyal Shahar. A prospective study of obstructive sleep apnea and incident coronary heart disease and heart failure: The sleep health heart study. *Circulation* 2010;122(4):352-360.
- A. S. Gami, D. E. Howard, E. J. Olson, and V. K. Somers. Day-night pattern of sudden death in obstructive sleep apnea. *NEJM* 2005;352(12):1206-1214.
- Organe Officiel de Pneumologie de la Langue Française. Recommandation pour la pratique clinique du syndrome d'apnée hypoxée de l'adulte. *Rev Mal Respir* 2010;27:S113-S178.
- Peled N., Abinader E.G., Pillar G., Sharif D., Lavie P. Nocturnal ischaemic events in patients with obstructive sleep apnea syndrome and ischaemic heart disease. *JACC* 1999;34(6):1744-49.
- Hamilton G.S., Meredith I.T., Wolker A.M., Solin P. Obstructive sleep apnea leads to transient uncoupling of coronary blood flow and myocardial work in humans. *Sleep* 2009;32(2):263-270.
- Wang N., Li S., Zhao L., Li H., Li Z., Shi Q., Li Y., Zhi Q. Relationship between obstructive sleep apnea and coronary microcirculatory function among patients with cardiac syndrome X. *Coronary Artery Disease* 2014;25:35-39.
- D. Yumino, Y. Tsurumi, A. Takagi, K. Suzuki, and H. Kasanuki. Impact of obstructive sleep apnea on clinical and angiographic outcomes following percutaneous coronary intervention in patients with acute coronary syndrome. *American Journal of Cardiology*, 2007;99(1):26-30.
- Recio-Mayoral A., Rimoldi O., Camici P., Kaski JC. Inflammation and microvascular dysfunction in cardiac syndrome X patients without conventional risk factors for coronary artery disease. *J Am Coll Cardiol Img* 2013;6(6):660-7.
- Shamsuzzaman A., Mikolaj Winnicki M., Lanfranchi P., Wolk R., Kara T., Accurso V., Somers V.K. Elevated C-reactive protein in patients with obstructive sleep apnea. *Circulation* 2002;105:2462-2464.
- Ip M., Lam B., Chan L.Y., Zheng L., Kenneth W., Tang T., Peter C., Fung W., Lam W.K. Circulating nitric oxide is suppressed in obstructive sleep apnea and is reversed by nasal continuous positive airway pressure. *American Journal of Respiratory and Critical Care Medicine* 2000;162(2):2166-2171.
- Belaidi E., JoyeuxFaure M., Ribout C., Launois SH., Lévy P., Godin-Ribout D. Major of hypoxia inducible factor-1 and endothelin system in promoting myocardial infarction and hypertension in an animal model of obstructive sleep apnea. *J Am Coll Cardiol* 2009;53:1309-17.
- T. Douglas Bradley M, John S. Floras, MD, DPhil. Sleep apnea and heart failure. part I: Obstructive sleep apnea. *Circulation* 2003;107:1671-1678.
- Pries A., Badimon L., Bugiardini R., Camici P., Dorobantu M., Duncker D., Escaned J., Koller A., Piek J., de Wit C. Coronary vascular regulation, remodelling, and collateralization: Mechanisms and clinical implications on behalf of the working group on coronary pathophysiology and microcirculation. *EJH* 2015.
- Gotsman J., Stabholz A., Planer D., Pugatsch T., Lapidus L., Novikov Y., Masrawa S., Soskolne A., Lotan C. Serum cytokines tumor necrosis factor alpha and interleukin-6 associated with severity of coronary artery disease: Indicators of an active inflammatory burden? *Isr Med Assoc* 2008;10(7):494-498.
- Rayan S., Taylor CT., McNicholas WT. Predictors of elevated nuclear factor-kB-dependent genes in obstructive sleep apnea syndrome. *Am J Respir Crit Care Med* 2006;174:824-830.