

Wrist Arthritis and Carpal Advanced Collapse- Systematic Review

Mohamed Maklad¹

1 University Hospitals of Nottingham, United Kingdom.

Conflict-of-interest statement: The author(s) declare(s) that there is no conflict of interest regarding the publication of this paper.

Open-Access: This article is an open-access article which was selected by an in-house editor and fully peer-reviewed by external reviewers. It is distributed in accordance with the Creative Commons Attribution Non Commercial (CC BY-NC 4.0) license, which permits others to distribute, remix, adapt, build upon this work non-commercially, and license their derivative works on different terms, provided the original work is properly cited and the use is non-commercial. See: <http://creativecommons.org/licenses/by-nc/4.0/>

Correspondence to: Mohamed Maklad, University Hospitals of Nottingham, United Kingdom.

Email: mohamedmaklad@doctors.org.uk

Received: October 14, 2020

Revised: November 8, 2020

Accepted: November 11 2020

Published online: December 28, 2020

ABSTRACT

BACKGROUND: wrist arthritis is broad and common surgical problem. It can arise due to different causes. These cases can end up with degree of carpal advanced collapse.

CASE DESCRIPTION: This review article looks into different types of carpal advanced collapse, pathogenesis and surgical options.

LITERATURE REVIEW: PubMed, Medline and EMBASE search had been performed. More than 60 papers have been reviewed. 39 references have been used within this review article.

CLINICAL RELEVANCE: the author combines these types of carpal collapse within one article to help specialists and junior trainees to have one comprehensive source for such crucial wrist pathology.

Key words: Carpal collapse; SLAC; SNAC; SMAC; SCAC

© 2020 The Author(s). Published by ACT Publishing Group Ltd. All rights reserved.

Maklad M. Wrist Arthritis and Carpal Advanced Collapse- Systematic Review. *International Journal of Orthopaedics* 2020; 7(6): 1374-1378 Available from: URL: <http://www.ghrnet.org/index.php/ijo/article/view/3013>

INTRODUCTION

Wrist arthritis can be broadly classified into inflammatory, degenerative, infectious and haemorrhagic.

Inflammatory arthritis of the wrist is frequently observed in patients with rheumatoid arthritis or crystal arthropathies. Deposition of urate and calcium pyrophosphate dehydrate (CPPD) in the synovial tissue leads to degenerative changes and eventually Scaphoid Chondrocalcinosis Advanced Collapse (SCAC).

Primary degenerative arthritis of the wrist is relatively uncommon.

Degenerative arthritis of the wrist is generally observed around the scaphoid bone. When the scapho-lunate ligaments are ruptured or the scaphoid is fractured and complicated by nonunion or malunion, joint misalignment will occur, causing secondary arthritis and Scapho-Lunate Advanced Collapse (SLAC), Scaphoid Nonunion Advanced Collapse (SNAC) or Scaphoid Malunion Advanced Collapse (SMAC) respectively.

Other causes of wrist arthritis include infectious or haemorrhagic cause like sickle cell anaemia and haemophilia.

The study looks into different types of wrist arthritis, pathogenesis and different surgical treatment options and their patient related outcomes.

METHOD

Electronic bibliographic search was performed in May 2019. The electronic databases of PubMed, Medline and EMBASE were searched using the following medical subject headings (MeSH): "Scapholunate advanced collapse", "SLAC", "scaphoid nonunion advanced collapse", "SNAC", "scaphoid crystal arthropathy advanced collapse", "SCAC", "CPPD", chondrocalcinosis, "scaphoid malunion advanced collapse" and "SMAC".

The titles and abstracts of potentially relevant articles were screened and examined. Lists of references from the articles were also examined to find other relevant studies that were not detected through the electronic search.

The authors reviewed each title and abstract, along with each

potentially relevant article.

History

SLAC Wrist: In 1984, Watson and Ballet^[1] reviewed more than 4,000 wrist radiographs and found degenerative changes in 210 cases (5.25%), mostly around the scaphoid. Most patients presented a pattern of degenerative arthritis from ruptures of the scapho-lunate ligaments and they introduced the term “SLAC wrist”.

SNAC Wrist: In 1970, Fisk^[2] reported degenerative changes after scaphoid nonunions. These findings were later confirmed by other studies^[3,4]. The pattern of degenerative arthritis is similar to the one described for the SLAC wrist. However, the term SNAC wrist is more accurate and was introduced by Krakauer et al^[5]. In spite of that, they continued to use the term SLAC wrist in their own publication. The term SNAC is now more commonly used^[6,7].

SCAC wrist: Chondrocalcinosis of the wrist was first described in 1970s by rheumatologists and radiologists. Later on, its pathological and histological features were described^[8]. In 2003, Romano introduced the term SCAC describing the degenerative changes associated with crystals^[9].

SMAC Wrist: Introduced by Lluch in 1998^[10].

Pathophysiology and biomechanics

SLAC Wrist: In the lateral radiographic view of a normal wrist, the scaphoid is seen in about 45° of flexion (ranging from 30° to 60°) in relation to the longitudinal axis of the radius. When grasping objects, the forces transmitted through the distal carpal row will add a flexion torque to the scaphoid. Further flexion of the scaphoid is prevented by its distal ligament insertions to the trapezium and trapezoid and the proximal ligament insertions to the lunate. When the scapho-lunate ligaments are ruptured from injury, flexion of the scaphoid increases, causing a dorsal subluxation of its proximal pole. This leads to flexion instability of the scaphoid. In normal circumstances, the lunate is collinear with the radius and the capitate. The normal alignment of the lunate is maintained by the length of the scaphoid and the intact scapholunate ligaments. When the scapholunate ligaments are ruptured, the scaphoid subluxes dorsally in relation to the radius, and the radial column of the carpus shortens. As a consequence, the compression forces through the central column, formed by the capitate and the lunate, will increase. When the lunate is compressed between the capitate and the radius it always goes into extension. This can be explained because its dorsal horn is thinner than the volar one, and the joint surface of the distal radius is volarly angulated about 11°. Consequently, wrist extension takes place primarily at the radio-lunate joint, while flexion is greater at the midcarpal joint^[11].

SNAC Wrist: In the presence of a scaphoid nonunion, the distal fragment flexes by the compression forces transmitted by the distal carpal row. The scaphoid also loses its normal length from wear of the bone at the fracture ends. Belsole et al^[12] observed an average of 6-15 % of bone loss (average 10 %) in this bone, which has a volume of 2.3-4 cm³ (normal average 3 cm³). The bone loss is even greater in longstanding cases where the proximal fragment of the scaphoid is barely in contact with the distal radius. Because the scaphoid is shortened, all compression forces are transmitted by the central column of the carpus, causing extension of the lunate as previously described for the SLAC wrist. The proximal fragment of the scaphoid is brought into extension by the intact scapholunate ligaments^[13]. The proximal fragment of the scaphoid follows the extended position of the lunate and keeps congruency with the distal radius, without causing cartilage wear at this level.

SCAC Wrist: The mechanism of crystal deposition and synovial change has been elucidated. Firstly, crystals appear in the synovial fluid. These are then deposited in the synovial membrane, ligaments and fibrocartilaginous structures and then in the articular cartilage. The CPPD localize in and around joints. The classic feature which is most specific for CPPD is calcification of the triangular fibrocartilage. Isolated ScaphoTrapezioTrapezoid joint (STT) disease is also specific to CPPD. The scapholunate joint is the next most frequently involved joint, followed by the distal radioulnar joint (DRUJ), the lunotriquetral (LT) joint and the isolated midcarpal joint, radiolunate and pisotriquetral joints. There may be a pancarpal arthrosis at the end stage^[8].

SMAC Wrist: Following scaphoid malunion, shortening and flexion of the distal fragment and extension of the proximal fragment, a pattern of degenerative arthritis similar to the SNAC wrist will also occur^[14,15]. Therefore, the aim of the treatment for scaphoid fractures should be without bone deformity. To prevent a future SMAC wrist pattern of degenerative arthritis, a young patient with a fractured scaphoid which has healed in a very deformed position, should be treated by corrective osteotomy and the addition of an anterior bone graft^[16].

Clinical picture

SLAC, SNAC, SMAC: Can stay asymptomatic for many years^[17,18]. Pain usually starts after minor trauma, and it is usually localized at the dorsal radio-scaphoid joint. Wrist mobility can be reduced, particularly on extension. The reason is that extension can only happen at the midcarpal joint, because the radio-lunate joint is already in extension. The wrist flexion is preserved, as both the radio-lunate and the midcarpal joint are able to flex.

The difference between SLAC, SNAC and SMAC wrists are the time between the injury and the onset of degenerative arthritis. The SLAC wrist is the one that will progress faster, while the SMAC wrist will take longer to develop degenerative arthritis and will always have a direct relationship to the degree of scaphoid deformity. Within the SNAC wrists, the worst prognosis will be seen in those cases with a very proximal fracture of the scaphoid, where the distal fragment of scaphoid will very rapidly develop a degenerative arthritis with the radial styloid. When the pseudoarthrosis occurs at the distal end of the scaphoid, the SNAC wrist will take longer to develop.

CPPD: Can remain asymptomatic for few years and diagnosed only radiologically by TFCC chondrocalcinosis. 50% can present as pseudo osteoarthritis affecting multiple joints. 25% of cases can present as acute monoarticular pseudogout, usually triggered by medical illness, trauma or secondary to calcium metabolism issues. 5% can show pseudo rheumatoid picture with bilateral symmetrical involvement of the MCP and PIP joints. With advanced disease, scapholunate ligament dissociation with incarceration of the scaphoid into distal radius can happen. Less than 5% will present with severe destructive arthropathy.

Imaging and staging

SLAC: four stages following a topographical sequence of joint degeneration. **Stage I:** proximal scaphoid and radial styloid. **Stage II:** involvement of the entire scaphocapitate joint. **Stage III:** Capitate-lunate joint with proximal migration of capitate. **Stage IV:** Degenerative arthritis of the radiolunate joint.

SNAC: similar to SLAC wrist except in stage I. The arthritic changes happen at the distal pole of the scaphoid^[19].

SMAC: Similar to SNAC wrist^[14,15].

SCAC: Romano described four stages of the SCAC wrist^[9].

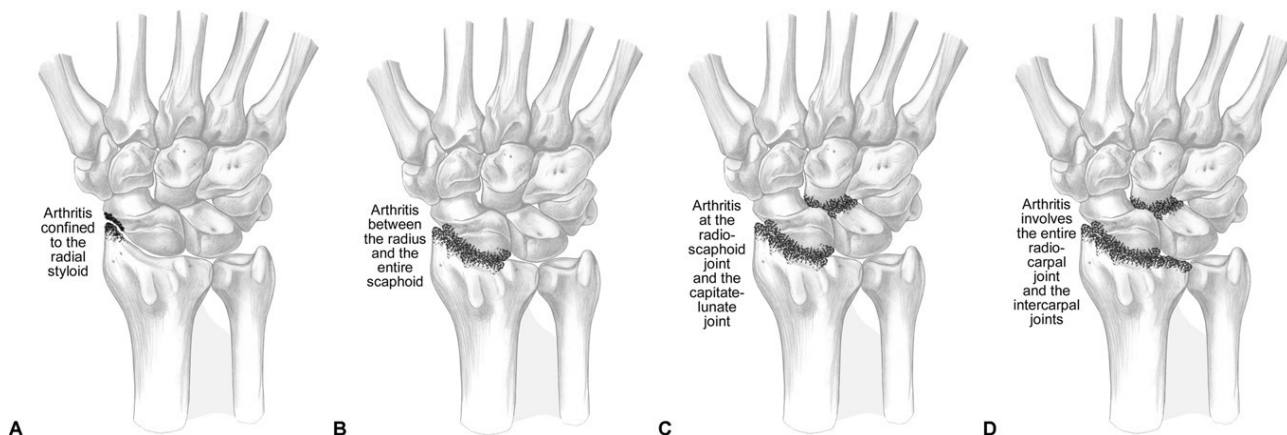


Figure 1 Stages of SLAC, SNAC and SMAC.

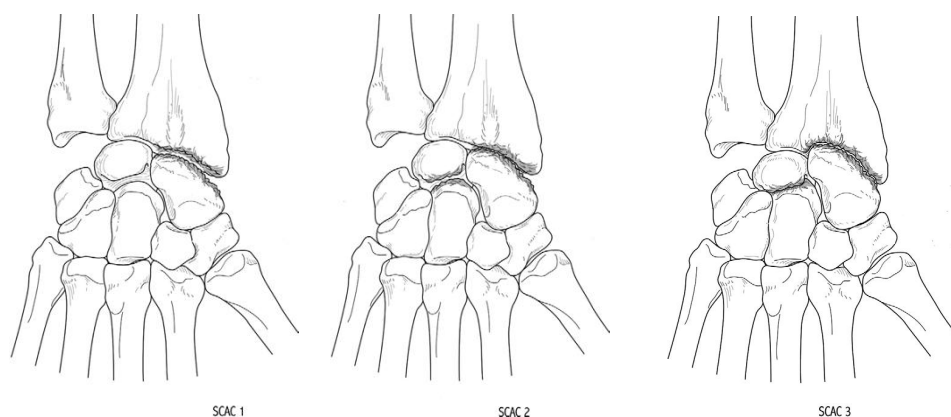


Figure 2 Stages of SCAC wrist.

Stage I: Isolated radioscaphoid changes. Involvement of the entire vertical aspect of the scaphoid easily differentiates it from SLAC and SNAC. Calcinosis at TFCC can be noted. **Stage II:** Scapholunate is more obvious. Verticalization of the scaphoid with inlay into the radius. **Stage III:** Midcarpal dislocation, characteristic embedding of scaphoid into the radius with vertical scapholunate dissociation. **Stage IV:** global wrist arthritis.

Management

Conservative Treatment: Trial of conservative treatment is recommended. Pain control, immobilization of the wrist with a splint or plaster cast for 3-4 weeks. This proves to be effective in elderly particularly those with a SLAC wrist.

Medical treatment: For acute attacks of crystal arthropathy. Includes non-steroidal anti-inflammatory drugs. Colchicine is used to control urate levels and flare up of chondrocalcinosis^[9].

Wrist Denervation: This is a surgical option to consider in the older group of patients. It has short postoperative recovery and does not affect wrist mobility. However, since its effectiveness and duration are limited, it is not recommended for younger age groups^[20,21].

Radial Styloidectomy: This may be indicated for cases of SNAC or SMAC wrists. A true radial styloidectomy is a good option for stages I and II of SNAC wrists, but only when it is associated with the treatment of the nonunion and correction of the deformity by bone grafting of the pseudoarthrosis and internal fixation of the scaphoid. Over excision of more than 6 mm should be avoided as it can lead to ulnar translocation of the carpus and radio-carpal incongruence from disruption of the radioscapho- capitate ligaments^[22,23].

Contraindicated in SLAC wrists as on long run will cause more instability of the scaphoid, unless the deformity is corrected at the same time.

Proximal Row Carpectomy: Can be done in patients with stages I and II. Good results have also been reported for the treatment of stage III, when there is minimal wear of the cartilage covering the head of the capitate^[24]. The good initial results will deteriorate with time, because the head of the capitate and the distal radius have different shapes. Therefore, it is not recommended in patients younger than 35 years of age^[25].

Scaphoid Resection and Partial Wrist Fusion: Resection of the scaphoid is the most effective treatment to relieve the pain. Isolated Scaphoid excision alone should never be performed as it will cause further collapse of the midcarpal joint and further extension of the lunate. To prevent this, it should be combined with some kind of midcarpal fusion^[26]. The most frequently performed fusion has been called the “four corner fusion”. Watson and Ryu^[27] recommended fusing the capitate and hamate to the lunate and triquetrum. Internal fixation can be achieved with transosseous K-wires, compression staples, headless compression screws or circular plates.

Dimitrios et al^[28] obtained a 100 % union rate of capito-lunate fusions, but 3 out of 8 patients still had persistent pain.

In SNAC or SMAC wrist, the proximal pole of the scaphoid should be left in place, for the purpose of increasing the surface of joint contact with the radius. After its correction together with the lunate or can be fused to the capitate as proposed by Viegas^[29].

Radio-scapho-lunate Arthrodesis: The technique of choice for cases of stage IV arthritis. The mobility at the midcarpal joint will be preserved. The so called “dart throwers motion” (DTM),

which follows a plane that varies from 37° to 59° from the sagittal plane according to the different investigators^[30-32] takes place at the midcarpal joint. This is the plane followed by the wrist extensors, extensor carpi radialis longus and brevis, and the main wrist flexor, the flexor carpi ulnaris, and used for the majority of hand activities. Patients prefer and adapt quicker to a radio-scapho-lunate arthrodesis than a midcarpal fusion. Excision of the distal scaphoid improves mobility after radio-scapho- lunate arthrodesis^[33].

Total Wrist Fusion: Since scaphoid excision and partial or total midcarpal arthrodesis provide good results, total wrist fusion is less popular. However, it may help early return to activities of daily life^[34].

Total Wrist Arthroplasty: a flexible silicone wrist implant was designed by Swanson in 1973^[35]. It was mainly intended for use in rheumatoid patients. Early results achieved good pain control and acceptable range of motion. However, longer follow-up revealed subsidence within the distal carpal row and rupture of the implant in the majority of cases^[36]. The distal bone anchorage is not into the metacarpals but into the distal carpal row by means of an elliptical metallic plate and screws^[37].

The “Universal Total Wrist” ® implant was manufactured by Kinetics Medical Inc. San Diego CAL. USA. These total wrist implants are semiconstrained, with the polyethylene bearing between both components having a condylar shape, which has recently changed from toroid to ellipsoid to improve stability and decrease wear^[38,39]. After some modifications, “Universal Total Wrist II ® (Integra LifeSciences, Plainsboro, NJ, USA).

These new implants, also called third generation, have also been used for the treatment of degenerative arthritis with short term satisfactory results. We have offered this alternative to patients who require painless wrist mobility for certain activities of daily life.

Potential complications, such as implant loosening, and wear should be thoroughly discussed with the patient.

RESULTS

Denervation is a valuable option in elderly patients having low morbidity. Proximal row carpectomy and four-corner fusion have good functional outcomes in the long-term. Total fusion should not be reserved as a salvage method for failed procedures. In some situations, total fusion maximises the likelihood of returning to activities of daily life. Finally, arthroplasty probably have a role within the therapeutic armamentarium, although longer follow-ups are needed to determine the exact indication. The choice of surgical option depends on the stage of the arthritis, patient requirements and surgeon's preference.

DISCUSSION

Wrist arthritis is common pathology. It can arise due to different causes and can end up with degree of carpal advanced collapse. The author made literature review into different types, pathogenesis and possible treatment options. The article aims to provide comprehensive information for the specialists specially the trainees.

REFERENCES

1. Watson HK, Ballet FL. The SLAC wrist: scapholunate advanced collapse pattern of degenerative arthritis. *J Hand Surg Am.* 1984 May; **9(3)**: 358-65. [DOI: 10.1016/s0363-5023(84)80223-3]; [PMID: 6725894].
2. Fisk GR. Carpal instability and the fractured scaphoid. *Ann R Coll Surg Engl.* 1970 Feb; **46(2)**: 63-76. [PMID: 5442131]; [PMCID: PMC2387714].
3. Mack GR, Bosse MJ, Gelberman RH, Yu E. The natural history of scaphoid non-union. *J Bone Joint Surg Am.* 1984 Apr; **66(4)**: 504-9. [PMID: 6707028].
4. Ruby LK, Leslie BM. Wrist arthritis associated with scaphoid nonunion. *Hand Clin.* 1987 Nov; **3(4)**: 529-39. [PMID: 3693420].
5. Krakauer JD, Bishop AT, Cooney WP. Surgical treatment of scapho-lunate advanced collapse. *J Hand Surg Am.* 1994 Sep; **19(5)**: 751-9. [DOI: 10.1016/0363-5023(94)90178-3]; [PMID: 7806795].
6. Krimmer H, Krapohl B, Sauerbier M, Hahn P. Der posttraumatische karpale Kollaps (SLAC- und SNAC-wrist)--Stadieneinteilung und therapeutische Möglichkeiten [Post-traumatic carpal collapse (SLAC- and SNAC-wrist)--stage classification and therapeutic possibilities]. *Handchir Mikrochir Plast Chir.* 1997 Sep; **29(5)**: 228-33. German. [PMID: 9424446].
7. Cooney WP, DeBartolo T, Wood MB. Post- Traumatic arthritis of the wrist. In: Cooney WP, Linscheid RL, Dobyns JH, editors. *The Wrist. Diagnosis and operative treatment.* St. Louis: Mosby; 1998. p. 588-629.
8. Saffar P. Chondrocalcinosis of the wrist. *J Hand Surg Br.* 2004 Oct; **29(5)**: 486-93. [DOI: 10.1016/j.jhsb.2004.02.013]; [PMID: 15336755].
9. Romano S. Arthrose non traumatique du poignet: la chondrocalcinose [Non-traumatic osteoarthritis of the wrist: chondrocalcinosis]. *Chir Main.* 2003 Dec; **22(6)**: 285-92. French. [DOI: 10.1016/j.main.2003.09.012]; [PMID: 14714506].
10. Lluch A. Concepto de muñeca SNAC: Scaphoid non-union Advanced Collapse. *Rev Ortop Traumatol.* 1998; **42 suppl 1**: 33-8.
11. Sarrafian SK, Melamed JL, Goshgarian GM. Study of wrist motion in flexion and extension. *Clin Orthop Relat Res.* 1977 Jul-Aug; **(126)**: 153-9; [PMID: 598105].
12. Belsole RJ, Hilbelink DR, Llewellyn JA, Dale M, Greene TL, Rayhack JM. Computed analyses of the pathomechanics of scaphoid waist nonunions. *J Hand Surg Am.* 1991 Sep; **16(5)**: 899-906. [DOI: 10.1016/s0363-5023(10)80158-3]; [PMID: 1940172].
13. Smith DK, Cooney WP 3rd, An KN, Linscheid RL, Chao EY. The effects of simulated unstable scaphoid fractures on carpal motion. *J Hand Surg Am.* 1989 Mar; **14(2 Pt 1)**: 283-91. [DOI: 10.1016/0363-5023(89)90022-1]; [PMID: 2703676].
14. Amadio PC, Berquist TH, Smith DK, Ilstrup DM, Cooney WP 3rd, Linscheid RL. Scaphoid malunion. *J Hand Surg Am.* 1989 Jul; **14(4)**: 679-87. [DOI: 10.1016/0363-5023(89)90191-3]; [PMID: 2787817].
15. Lindström G, Nyström A. Incidence of post-traumatic arthrosis after primary healing of scaphoid fractures: a clinical and radiological study. *J Hand Surg Br.* 1990 Feb; **15(1)**: 11-3. [DOI: 10.1016/0266-7681(90)90041-2]; [PMID: 2307868].
16. Birchard D, Pichora D. Experimental corrective scaphoid osteotomy for scaphoid malunion with abnormal wrist mechanics. *J Hand Surg Am.* 1990 Nov; **15(6)**: 863-8. [DOI: 10.1016/0363-5023(90)90004-b]; [PMID: 2269774].
17. Lindström G, Nyström A. Natural history of scaphoid non-union, with special reference to “asymptomatic” cases. *J Hand Surg Br.* 1992 Dec; **17(6)**: 697-700. [DOI: 10.1016/0266-7681(92)90204-f]; [PMID: 1484258].
18. Kerluke L, McCabe SJ. Nonunion of the scaphoid: a critical analysis of recent natural history studies. *J Hand Surg Am.* 1993 Jan; **18(1)**: 1-3. [DOI: 10.1016/0363-5023(93)90235-U]; [PMID: 8423291].
19. Viegas SF, Patterson RM, Hillman GR, Peterson PD, Crossley M, Foster R. Simulated scaphoid proximal pole fracture. *J Hand Surg Am.* 1991 May; **16(3)**: 495-500. [DOI: 10.1016/0363-5023(91)90021-3]; [PMID: 1861034].
20. Buck-Gramcko D. Denervation of the wrist joint. *J Hand Surg Am.* 1977 Jan; **2(1)**: 54-61. [DOI: 10.1016/s0363-5023(77)80010-5]; [PMID: 839055].
21. Rothe M, Rudolf KD, Partecke BD. Langzeitergebnisse nach

- Handgelenkdenervation bei fortgeschrittenem karpalem Kollaps (SLAC-/SNAC-Wrist Stadium II und III) [Long-term results following denervation of the wrist in patients with stages II and III SLAC-/SNAC-wrist]. *Handchir Mikrochir Plast Chir*. 2006 Aug; **38(4)**: 261-6. German. [DOI: 10.1055/s-2006-924408]; [PMID: 16991047].
22. Siegel DB, Gelberman RH. Radial styloidectomy: an anatomical study with special reference to radiocarpal intracapsular ligamentous morphology. *J Hand Surg Am*. 1991 Jan; **16(1)**: 40-4. [DOI: 10.1016/s0363-5023(10)80010-3]; [PMID: 1995691].
 23. Nakamura T, Cooney WP 3rd, Lui WH, Haugstvedt JR, Zhao KD, Berglund L, An KN. Radial styloidectomy: a biomechanical study on stability of the wrist joint. *J Hand Surg Am*. 2001 Jan; **26(1)**: 85-93. [DOI: 10.1053/jhsu.2001.20963]; [PMID: 11172373].
 24. Cohen MS, Kozin SH. Degenerative arthritis of the wrist: proximal row carpectomy versus scaphoid excision and four-corner arthrodesis. *J Hand Surg Am*. 2001 Jan; **26(1)**: 94-104. [DOI: 10.1053/jhsu.2001.20160]; [PMID: 11172374].
 25. DiDonna ML, Kiefhaber TR, Stern PJ. Proximal row carpectomy: study with a minimum of ten years of follow-up. *J Bone Joint Surg Am*. 2004 Nov; **86(11)**: 2359-65; [PMID: 15523004].
 26. Strauch RJ. Scapholunate advanced collapse and scaphoid nonunion advanced collapse arthritis--update on evaluation and treatment. *J Hand Surg Am*. 2011 Apr; **36(4)**: 729-35. [DOI: 10.1016/j.jhsa.2011.01.018]; [PMID: 21463735].
 27. Watson HK, Ryu J. Degenerative disorders of the carpus. *Orthop Clin North Am*. 1984 Apr; **15(2)**: 337-53; [PMID: 6728449].
 28. Giannikas D, Karageorgos A, Karabasi A, Syggelos S. Capitulum arthrodesis maintaining carpal height for the treatment of SNAC wrist. *J Hand Surg Eur Vol*. 2010 Mar; **35(3)**: 198-201. [DOI: 10.1177/1753193409352280]. Epub 2009 Dec 23. Erratum in: *J Hand Surg Eur Vol*. 2010 Jul; **35(6)**: 521. Dimitrios, G [corrected to Giannikas, D]; Athanasios, K [corrected to Karageorgos, A]; Ageliki, K [corrected to Karabasi, A]; Spiridon, S [corrected to Syggelos, S]; [PMID: 20031996].
 29. Viegas SF. Limited arthrodesis for scaphoid nonunion. *J Hand Surg Am*. 1994 Jan; **19(1)**: 127-33. [DOI: 10.1016/0363-5023(94)90236-4]; [PMID: 8169357].
 30. Werner FW, Short WH, Fortino MD, Palmer AK. The relative contribution of selected carpal bones to global wrist motion during simulated planar and out-of-plane wrist motion. *J Hand Surg Am*. 1997 Jul; **22(4)**: 708-13. [DOI: 10.1016/S0363-5023(97)80133-5]; [PMID: 9260631].
 31. Crisco JJ, Coburn JC, Moore DC, Akelman E, Weiss AP, Wolfe SW. In vivo radiocarpal kinematics and the dart thrower's motion. *J Bone Joint Surg Am*. 2005 Dec; **87(12)**: 2729-40. [DOI: 10.2106/JBJS.D.03058]; [PMID: 16322624].
 32. Moritomo H, Murase T, Goto A, Oka K, Sugamoto K, Yoshikawa H. In vivo three-dimensional kinematics of the midcarpal joint of the wrist. *J Bone Joint Surg Am*. 2006 Mar; **88(3)**: 611-21. [DOI: 10.2106/JBJS.D.02885]; [PMID: 16510829].
 33. Garcia-Elias M, Lluch A, Ferreres A, Papini-Zorli I, Rahimtoola ZO. Treatment of radiocarpal degenerative osteoarthritis by radioscapulunate arthrodesis and distal scaphoidectomy. *J Hand Surg Am*. 2005 Jan; **30(1)**: 8-15. [DOI: 10.1016/j.jhsa.2004.09.001]; [PMID: 15680550].
 34. Laulan J, Marteau E, Bacle G. Wrist osteoarthritis. *Orthop Traumatol Surg Res*. 2015; **101(1 Suppl)**: S1-S9. [DOI: 10.1016/j.otsr.2014.06.02].
 35. Swanson AB. Flexible implant arthroplasty for arthritic disabilities of the radiocarpal joint. A silicone rubber intramedullary stemmed flexible hinge implant for the wrist joint. *Orthop Clin North Am*. 1973 Apr; **4(2)**: 383-94. [PMID: 4267620].
 36. Stanley JK, Tolat AR. Long-term results of Swanson silastic arthroplasty in the rheumatoid wrist. *J Hand Surg Br*. 1993 Jun; **18(3)**: 381-8. [DOI: 10.1016/0266-7681(93)90069-r]; [PMID: 8345274].
 37. Menon J. Universal Total Wrist Implant: experience with a carpal component fixed with three screws. *J Arthroplasty*. 1998 Aug; **13(5)**: 515-23. [DOI: 10.1016/s0883-5403(98)90050-x]; [PMID: 9726316].
 38. Anderson MC, Adams BD. Total wrist arthroplasty. *Hand Clin*. 2005 Nov; **21(4)**: 621-30. [DOI: 10.1016/j.hcl.2005.08.014]; [PMID: 16274871].
 39. Kamal R, Weiss AP. Total wrist arthroplasty for the patient with non-rheumatoid arthritis. *J Hand Surg Am*. 2011 Jun; **36(6)**: 1071-2. [DOI: 10.1016/j.jhsa.2011.01.033]. Epub 2011 Apr 12. [PMID: 21489725].