

## The Outcome of Modified Dunn's Procedure for Moderate and Severe Slipped Capital Femoral Epiphysis

Mohamed Othman, Mohamed Abd El-Fattah Sebei, Adel Abdel Azim Ahmad

Mohamed Othman, Assistant professor of Orthopaedic Surgery, Faculty of medicine, Zagazig University, Zagazig City, Egypt  
Mohamed Abd El-Fattah Sebei, Lecturer of Orthopaedic Surgery, Faculty of medicine, Zagazig University, Zagazig City, Egypt  
Adel Abdel Azim Ahmad, Assistant professor of Orthopaedic Surgery, Faculty of medicine, Zagazig University, Zagazig City, Egypt

**Conflict-of-interest statement:** The author(s) declare(s) that there is no conflict of interest regarding the publication of this paper.

**Open-Access:** This article is an open-access article which was selected by an in-house editor and fully peer-reviewed by external reviewers. It is distributed in accordance with the Creative Commons Attribution Non Commercial (CC BY-NC 4.0) license, which permits others to distribute, remix, adapt, build upon this work non-commercially, and license their derivative works on different terms, provided the original work is properly cited and the use is non-commercial. See: <http://creativecommons.org/licenses/by-nc/4.0/>

**Correspondence to:** Adel Abdel Azim Ahmad, Department of Orthopaedic Surgery, New surgery building, 4th floor, Zagazig University Hospitals, Zagazig City, Egypt.  
Email: [Afoda77@gmail.com](mailto:Afoda77@gmail.com)  
Telephone: +201065976503

Received: May 21, 2018

Revised: June 3, 2018

Accepted: June 6 2018

Published online: August 28, 2018

### ABSTRACT

**AIM:** To evaluate the outcome of 20 children with moderate-severe slipped capital femoral epiphysis (SCFE) with open physes, treated by the modified Dunn's procedure, as regards: intraoperative findings, clinical and radiographic outcomes, and postoperative complication rate.

**PATIENTS AND METHODS:** A prospective study was executed, between 2012 and 2016, for treating moderate-severe SCFE with modified Dunn procedure in 20 hips of 20 patients, with a mean age of  $13.6 \pm 3.4$  years (range: 10 - 16.5 years). Seven cases were

unstable SCFE. We excluded mild SCFE, endocrinopathy and renal cases.

**RESULTS:** The mean *follow-up* was  $19 \pm 9.2$  months (range: 12 - 36 months). *Radiologically*, all parameters showed significant improvement; with the mean slip angle corrected from  $61^\circ \pm 14.4$  preoperatively to  $10^\circ \pm 10.1$  postoperatively, the mean alpha angle corrected from  $90.2 \pm 21^\circ$  preoperatively to  $49.1 \pm 8^\circ$  postoperatively and the mean femoral neck length difference was  $8.1 \pm 6$  mm. *Functionally*, the mean Harris hip score (HHS) was  $86.2 \pm 9.6$  and the Heyman and Herndon score was excellent-good in 15 cases (75%), fair in two, poor in two and failed in one. *Postoperative major complications* occurred in only two cases (10%); AVN in one and secondary FAI in another case.

**CONCLUSIONS:** Modified Dunn's procedure is an effective and safe treatment for moderate-severe SCFE, achieving better anatomical and functional outcome, with a reasonable complication rate.

**Key words:** Slipped capital femoral epiphysis; Modified Dunn procedure; Capital realignment of SCFE; Safe surgical dislocation of the hip; Avascular necrosis in SCFE

© 2018 The Author(s). Published by ACT Publishing Group Ltd. All rights reserved.

Othman M, El-Fattah Sebei MA, Ahmad AAA. The Outcome of Modified Dunn's Procedure for Moderate and Severe Slipped Capital Femoral Epiphysis. *International Journal of Orthopaedics* 2018; 5(4): 952-960 Available from: URL: <http://www.ghrnet.org/index.php/ijo/article/view/2344>

### INTRODUCTION

Slipped capital femoral epiphysis (SCFE) is relatively common in adolescents<sup>[1,2]</sup>. The management of SCFE has been controversial for decades, especially for moderate to severe slips<sup>[2-5]</sup>. Traditionally, in-situ pinning is the most common treatment, with the objective to prevent further epiphyseal slippage, while minimizing the risk of osteonecrosis<sup>[2,5-7]</sup>. In-situ fixation of moderate to severe slips has a low surgical risk, with many hips remaining asymptomatic for decades<sup>[8,9]</sup>, and has been advocated by surgeons who believe that the

deformed hip has the potential to remodel with some restoration of the disturbed proximal femoral anatomy<sup>[8-12]</sup>. However, the remodeling potential is controversial and partial if any, with a resultant abnormal head-neck offset, leading to femoro-acetabular impingement (FAI), with associated chondrolabral damage and premature osteoarthritis<sup>[2,3,6,7,13]</sup>.

Increasing recognition of FAI and chondro-labral damage even after mild SCFE<sup>[3,14-18]</sup> has led to a reconsideration and change of the objectives of treatment of SCFE. The ideal treatment would involve stabilizing the physis to prevent further epiphyseal slippage and correcting the deformity at the subcapital level, at the same time, to prevent FAI and early arthrosis, and to normalize hip range of motion (ROM)<sup>[3,5-7,13,15,19,20]</sup>.

Subcapital corrective osteotomies have the advantage of normal or near-normal restoration of the proximal femoral anatomy but are associated with potential risk of femoral head osteonecrosis<sup>[2-5,13,19,21,22]</sup>.

In the original Dunn's procedure<sup>[23]</sup>, greater trochanter osteotomy was done to obtain a wide exposure, the hip joint was examined, protecting the retinacular vessels running along the posterior surface of the femoral neck under direct visualization while performing neck osteotomy, reduction and fixation of slip. Ganz *et al.*<sup>[22]</sup> introduced a modified Dunn's procedure that involved executing the original procedure after surgical dislocation of the epiphysis, because it is technically demanding to operate on the femoral neck to the epiphysis while it is located within the acetabulum. The modified Dunn's procedure is reported to achieve favorable postoperative outcome, although caution is needed because of the potential risk of femoral head avascular necrosis (AVN)<sup>[2,13,17,20,24]</sup>.

The purpose of this study was to evaluate the outcome of 20 children with moderate to severe SCFE with open physes, treated by the modified Dunn's procedure, as regards: (1) intraoperative findings; (2) clinical outcome; (3) radiographic outcome and (4) postoperative complication rate.

## PATIENTS AND METHODS

A prospective study was executed at our institution, between March 2012 and January 2016, on the modified Dunn's procedure (open subcapital realignment by a surgical dislocation approach), for management of moderate and severe SCFE in 20 hips of 20 patients (who were available for final follow-up examination). Eleven patients were male and nine were female. The mean age at the time of the surgery was  $13.6 \pm 3.4$  years (range: 10 - 16.5 years old). The left hip was affected in 12 patients and the right hip, in eight. According to the degree of slip, nine cases were moderate and 11 cases were severe. According to Fahey and O'Brien's classification<sup>[25]</sup>, eight cases were acute on top of chronic slip, while 12 cases were chronic. According to Loder's classification<sup>[26]</sup>, seven cases were unstable. Contralateral mild slip was noted in four cases (20%) at the first presentation. Cases with mild slippage, cases with underlying endocrinopathy or renal insufficiency, cases with other congenital or acquired hip deformity, patients with established osteonecrosis before the index procedure and patients with less than one year of follow-up were excluded. The study was authorized by the local Ethical Committee and an informed written consent of the parents of patients to participate in the study (after explanation of risks and benefits) was taken.

### Preoperative Evaluation

All patients complained of hip and/or thigh pain, aggravated by walking for more than three weeks. In unstable cases, patients could

not weight-bear. Preoperative ROM and clinical hip scores were inconsistently assessed, because of the high percentage of hips with unstable SCFE. The radiographic examination were carried out with AP-pelvic radiographs and either a cross-table lateral or frog-leg lateral radiograph, to measure slip angle by Southwick's method<sup>[27]</sup> and alpha angle and to evaluate for the presence of femoral head AVN<sup>[6,28]</sup>.

### Surgical procedures (Figure 1, A - H)<sup>[3,7,22,29]</sup>

Surgery was performed under general anesthesia and in lateral position. A straight lateral incision centered over the greater trochanter was made. The fascia lata was incised along the anterior border of the gluteus maximus muscle and the Gibson interval between the gluteus medius and maximus muscles was developed. The trochanteric bursa was incised and the piriformis and gluteus minimus muscles were identified by retracting the gluteus medius anteriorly. Care should be taken to avoid an iatrogenic injury of the relatively constant anastomosis of the inferior gluteal artery to the deep branch of the medial femoral circumflex artery (DB-MFCA), which runs at the inferior border of piriformis. This important anastomosis can potentially guarantee the femoral head blood supply in case of the deep branch injury.

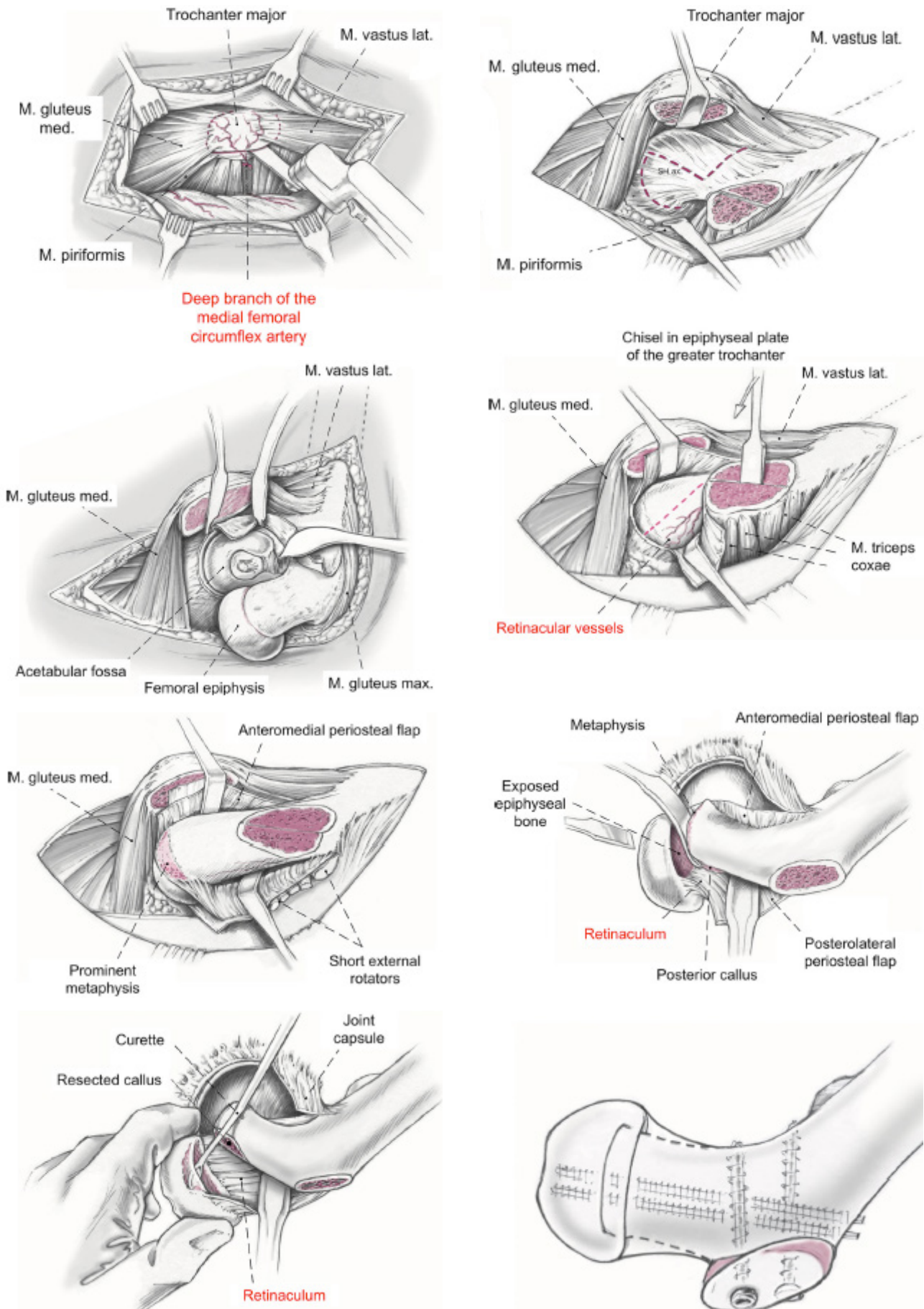
A trochanteric flip osteotomy (of no > 1.5 cm thickness), was done leaving the most posterior fibers (2 - 3 mm) of the gluteus medius tendon intact. This ensures that the osteotomy is not too medial endangering DB-MFCA and ensures that most fibers of the piriformis tendon remain attached to the stable portion of the greater trochanter. The mobile trochanter with the attached vastus, gluteus minimus and medius was flipped antero-superiorly, thus exposing the anterior capsule of hip, between the piriformis and gluteus minimus.

The arthrotomy was performed in a Z or reverse Z fashion, while protecting the soft tissues in the piriformis fossa and the labrum. In unstable slip, the epiphysis was provisionally-pinned with 2 mm-K wires, to avoid rupturing or stretching of the retinacular vessels by uncontrolled movement of the femoral neck and head. The epiphyseal perfusion was checked by drilling a 2-mm hole in the femoral head before the hip was dislocated.

After cutting the ligamentum teres, the femoral epiphysis was then dislocated by placing the lower leg in the opposite sterile bag in flexion and external rotation  $\pm$  a hook placed around the calcar. This allowed a full inspection and debridement or repair of chondrolabral damage.

After head relocation, the retinacular soft tissue flap was developed. This flap contained DB-MFCA, periosteum, piriformis muscle, part of posterior capsule, and short external rotators. The flap was developed by stepwise resection of the most posterior portion of the greater trochanter by the so-called inside-out technique. This started at the level of the trochanteric apophysis which indicates the base of the femoral neck and extended proximally to the tip of the trochanter, thus allowing for release of the posterior and lateral periosteum along the neck. The neck periosteum was incised along its axis, and the retinacular flap was then carefully mobilised proximally with periosteal elevator. Distally, the flap should extend to the level of lesser trochanter, thus significantly reducing tension on the retinacular vessels. Anteriorly, the periosteum was peeled off the bone with a periosteal elevator with the head in dislocated position.

Gradual separation of the epiphysis from the metaphysis was done using chisels starting from anterior and facilitated with external rotation, till the epiphysis became completely mobile but still attached to the posteroinferior retinacular soft tissue flap. The metaphyseal stump could be best exposed with the epiphysis



**Figure 1** Steps of surgical technique: (A) Trochanteric flip osteotomy , (B) Capsulotomy, (C) Head dislocation, (D) Periosteal incision and development of retinacular soft-tissue flap, (E) Complete development of retinacular soft-tissue flap, (F) Epiphyseal-metaphyseal separation, (G) Physal plate curettage, (H) Final fixation[29].

relocated in the acetabulum. The metaphyseal callus was resected until a spherical surface of the neck was achieved, with the least further neck shortening needed to prevent tension on the retinacular vessels during reduction of slip.

The physal plate was curetted, to accelerate bony healing. Normally, the exposed epiphyseal bone would show visible bleeding. Under visual control of the retinaculum, the epiphysis was then reduced manually on the metaphyseal stump in an anatomic alignment, to minimize FAI; by centering the femoral head on the neck (thus, adjusting the head-neck offset), adjusting the neck thickness, achieving correct varus-valgus alignment and correct rotation (estimated with the position of the anterior retinacular border relative to the neck and with the position of fovea capitis). Correct alignment was checked, by fluoroscopy after preliminary pin fixation through the fovea capitis. Final fixation was achieved by two cannulated screws. Epiphyseal perfusion after the capital realignment was re-checked using a 2 mm-drill hole with observation of subsequent bleeding.

The anterior periosteum and posterior retinacular flap were then reattached loosely with tension-free sutures. Also, the capsule was closed without tension. The greater trochanter was readapted with two 3.5 mm screws, optionally with distal advancement (in five cases), to achieve a relative lengthening of the femoral neck to avoid greater trochanter impingement against the pelvis.

#### Postoperative care

To protect the trochanteric osteotomy, an abductor pillow was used for two weeks postoperatively, and active hip abduction, passive adduction and hip strengthening were not allowed until the trochanter was healed. However, physiotherapy was used to avoid the development of a hip flexion and external rotation contracture<sup>[28]</sup>. A non-weight bearing protocol was followed for 6 weeks. After radiographic union of the trochanteric osteotomy and femoral neck, stepwise transition to full weight-bearing was allowed, with normal use of the hip after three months<sup>[3,7,29]</sup>.

#### Intraoperative assessment

We used the method proposed by Slongo *et al*<sup>[3]</sup> for assessing physal stability. A grossly-unstable hip showed a ruptured anterior periosteum and needs temporary pinning to avoid epiphyseal separation during dislocation. A stable physis required surgical separation of the epiphysis from the neck with an osteotome after dissecting the intact periosteum. A hip was classified as partially-unstable when it was grossly stable and the periosteum was intact, but the epiphysis could be separated with little force once the periosteum was freed.

#### Postoperative functional Assessment

The final functional outcome was assessed using the Harris hip score (HHS)<sup>[30,31]</sup> and the Heyman and Herndon classification system<sup>[32]</sup>. According to the Heyman and Herndon scoring system<sup>[32]</sup>, a hip is considered excellent if it has normal ROM, and without limp or pain; good if there is no limp, no pain, and slight limitation of internal rotation (IR) but internal rotation beyond neutral; fair if there is no pain, no limp, and slight limitation of abduction and IR; or poor if there is a slight pain, mild limp after strenuous exercise, and slight limitation of IR, abduction, and flexion. A hip is rated as failed if there is pain, limp on activity, and marked limitation of motion requiring reconstructive surgery or progressive radiographic changes are seen.

#### Postoperative radiographic assessment

At the last follow-up, bilateral hip radiographs (AP and frog-leg lateral) were used to measure slip angle, alpha angle (as an indicator for the development of FAI) and femoral neck length difference and to evaluate for the presence of chondrolysis and AVN<sup>[6,19,28]</sup>.

#### Statistical analysis

Results were expressed as means  $\pm$  SD (standard deviation). The differences between pre- and post-operative data were analyzed by Paired T test. A statistical significance was set at  $p < 0.05$

## RESULTS

The mean follow-up period was  $19 \pm 9.2$  months (range: 12 - 36 months).

**The intra- operative findings (Table 1):** (1) Chondrolabral damage was demonstrated in 15 cases (75%). It was more extensive in the stable SCFE and hips with a longer duration of complaint; (2) Clinically-assessed SCFE stability correlated with intraoperative physal stability only in the unstable SCFE. All clinically-unstable SCFE ( $n = 7$ ) had intraoperative instability [grossly unstable ( $n = 5$ ) or partially-unstable ( $n = 2$ )]. However, even in the clinically stable SCFE, five out of 13 hips had partial intraoperative instability; (3) Bleeding of the femoral head after reduction was demonstrated in 19 cases (95%) and was absent in one head, which developed AVN.

#### The final outcome: (Figures 2, 3)

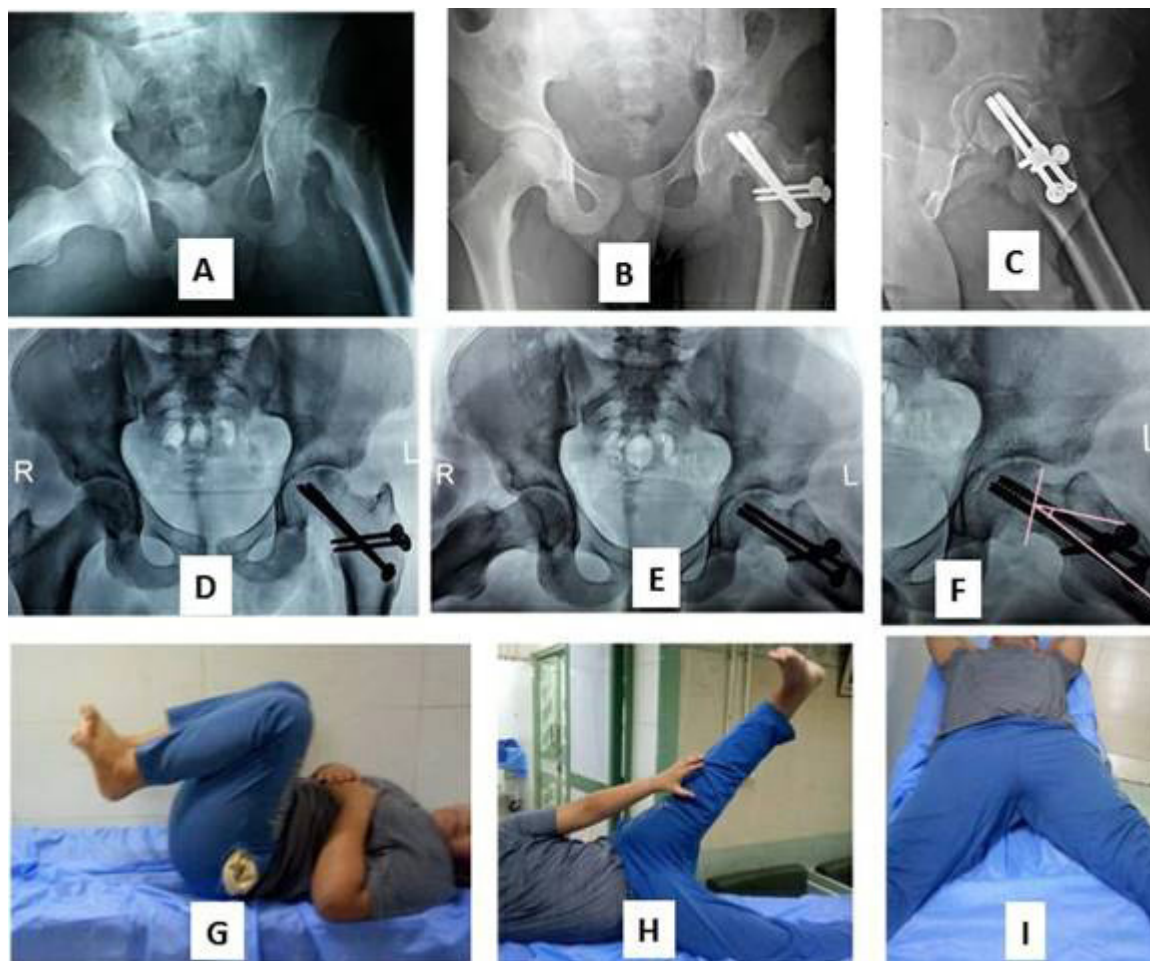
**Clinical results:** (1) The range of movement improved to a satisfactory degree. The mean postoperative flexion was  $105.5 \pm 15.7^\circ$  (range:  $50 - 120^\circ$ ). The mean postoperative internal rotation (IR) in  $90^\circ$  flexion was  $36.0 \pm 8.5^\circ$  (range:  $15 - 45^\circ$ ). The mean postoperative external rotation (ER) in  $90^\circ$  flexion was  $42.4 \pm 7.4^\circ$  (range:  $15 - 50^\circ$ ). The mean post-operative abduction was  $40.0 \pm 7.5^\circ$  (range:  $20 - 48^\circ$ ). (2) The mean Harris hip score (HHS)<sup>[30,31]</sup> at the final follow examination was  $86.2 \pm 9.6$  and the functional outcome according to the Heyman and Herndon score<sup>[32]</sup>, was excellent and good in 15 cases (75%), fair in two cases, poor in two and failed in one (Table 2).

Table 1 Intra- operative findings.

Intraoperative Findings	No. of Hips (%)
<b>Acetabular chondrolabral damage</b>	
Yes	15 (75%)
No	5 (25%)
<b>Epiphyseal stability</b>	
Stable	8 (40%)
Partially-unstable	7 (35%)
Grossly-unstable	5 (25%)
<b>Bleeding of the femoral head after reduction</b>	
Yes	19 (95%)
No	1 (5%)

Table 2 The outcome of our series according to the Heyman and Herndon system<sup>[32]</sup>.

Excellent	Good	Fair	Poor	Failure	total
5 (25%)	10 (50%)	2 (10%)	2 (10%)	1 (5%)	20



**Figure 2** 12 ys old boy, with Lt-sided severe unstable SCFE treated by modified Dunn procedure; (A) preoperative slip, (B, C) postoperative radiographs, (D-F) 18 months-postoperative radiographs; sufficient correction of slip angle and head-neck offset, complete union of physis and trochanteric osteotomy without chondrolysis or AVN, (G-I) good ROM. The clinical score was excellent.

**Table 3** Patients' characteristics and results in different studies.

	No of hips	Stability		Severity	Mean follow-up (months)	Mean slip angle		Mean $\alpha$ angle		Hip score	
		stable	unstable			preop	postop	preop	postop	mean HHS	H&H (G-EX)
Ziebarth <i>et al</i> 2009	40	27	13	M-S	42	45.6	8.6		40.6	99.6	
Slongo <i>et al</i> 2010	23	20	3	All	24	47.6	4.6		38	99	
Huber <i>et al</i> 2011	30	27	3	All	51.6	44.9	5.2		41.4	97	
Sankar <i>et al</i> 2013	27		27		22.3		6			no AVN: 88; with AVN: 60	
Novais <i>et al</i> 2015	15	15		S	28.8	65	16	111	44		9/15
Cosma <i>et al</i> 2016	7	6	1	S	12	68	9				6/7
El-marghany <i>et al</i> 2017	32	32		All	17.3	52.5	5.6	97.8	51.15	96	30/32
Persinger <i>et al</i> 2018	31		31		27.4		2.5		47.4		
Current study	20	13	7	M-S	19.9	61	10	90	49	86	15/20

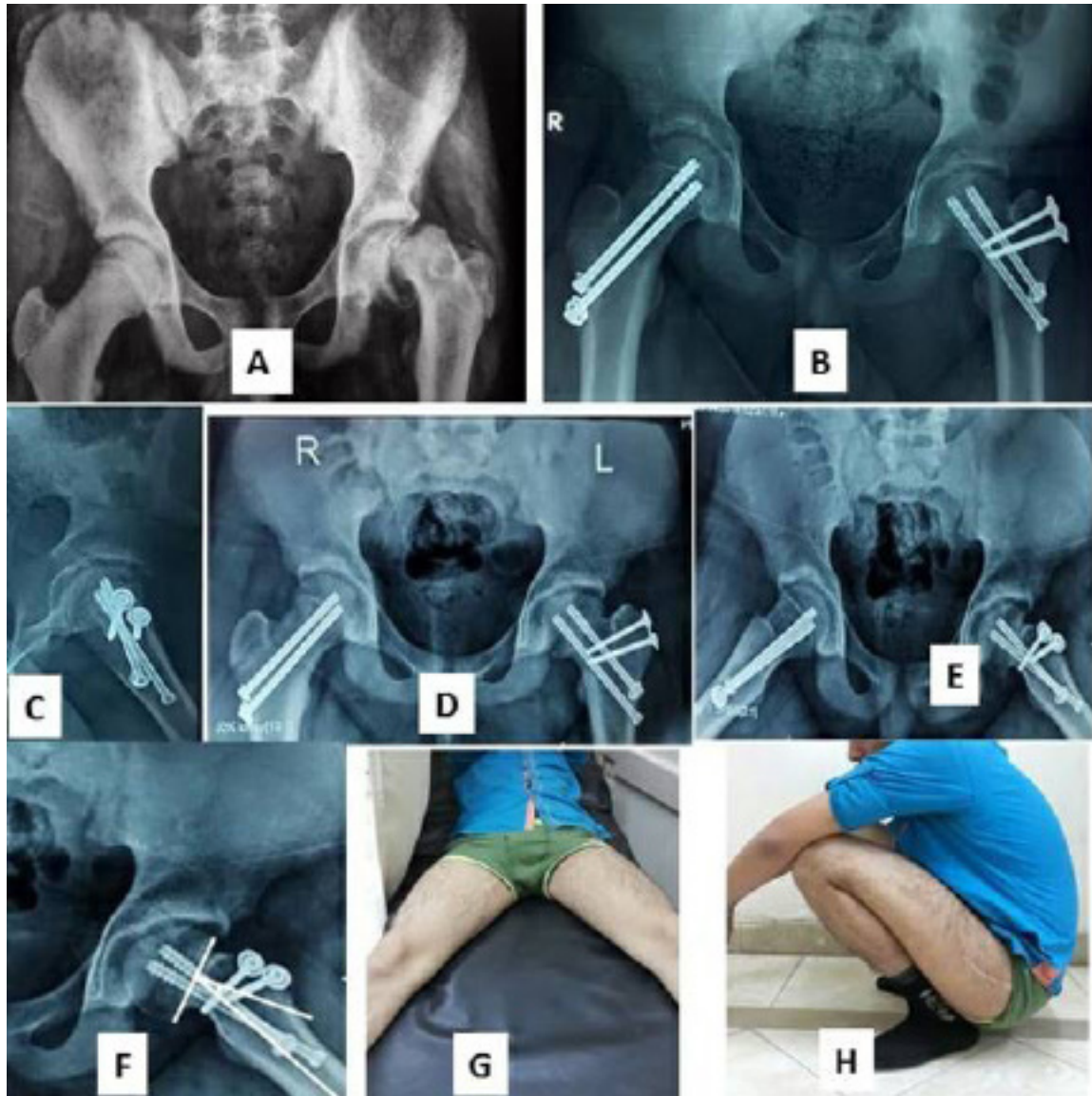
M-S: moderate-severe; All: all grades; HHS: Harris hip score; H&H: Heyman and Herndon score; G-Ex: good-excellent.

**Radiologic results (Table 3)**

(1) Radiographic measurements: The mean slip angle of the femoral head was corrected from  $61 \pm 14.4^\circ$  (range: 41 - 76.3) preoperatively to a mean postoperative value of  $10 \pm 10.1^\circ$  (range: 5.5 - 21) with a mean correction of  $51 \pm 10^\circ$ , ( $p$  value  $< 0.05$ ). The mean alpha angle was corrected from  $90.2 \pm 21^\circ$  (range: 77 - 143.5 ) preoperatively to a postoperative value of  $49.1 \pm 8^\circ$  (range: 44.4 - 62), with a mean correction of  $42.1 \pm 13.2^\circ$ , ( $p$  value  $< 0.05$ ). The mean femoral neck length difference was  $8.1 \pm 6$  mm (range: 4 - 18 mm). (2) Osteonecrosis occurred in one case (5%).

**Postoperative Complications (Table 4)**

In this study, despite postoperative complications occurred in six cases (30%), major complications occurred in only two cases (10%); AVN in one case and secondary FAI in another case. AVN was demonstrated at 16 weeks postoperatively, in a patient, after showing no intraoperative head perfusion. Finally, the functional outcome was classified as failure. Secondary FAI due to a bony spur at the femoral head-neck junction occurred in another case. It was treated by excision of the spur. Finally, the functional rating was fair. No patients developed deep infection, DVT, nerve injuries, implant failure, chondrolysis or non-union.



**Figure 3** 13 ys old boy, with Lt-sided severe unstable SCFE and Rt mild SCFE treated by modified Dunn procedure for Lt SCFE and in-situ fixation of Rt side; (A) preoperative slip, (B,C) one year-postoperative radiographs, (D-F) two years-postoperative radiographs; sufficient correction of slip angle and head-neck offset, complete union of physis and trochanteric osteotomy without chondrolysis or AVN, (G-H) good ROM. The clinical score was good.

**Table 4** Postoperative complications in different studies.

	Infection	Osteo-synthesis failure	Heterotopic ossification	delayed union	AVN	Chondrolysis	Limited ROM	Osteo-arthritis	FAI	Total
Ziebarth et al 2009	0	3 (7.5%)	3 (7.5%)	3 (7.5%)	0	0			1(2.5%)	10 ( 25% )
Slongo et al 2010	0	1 (4.4%)	0	0	1 (4.4%)	0	1 (4.4%)	1 (4.4%)	0	4 (17.6%)
Huber et al 2011	0	4 (13.5%)	0	0	1 (3.5%)	0			0	5 (17%)
Sankar et al 2013	0	4 (15%)	0	0	7 (26%)	0	7 (26%)		1(3.7%)	11 (41%)
Novais et al. 2015	0	2 (13%)	0	0	1 (7%)	0	6 (40%)	1 (7%)	0	3 (20%)
Cosma et al 2016	0	0	0	0	0	0	1 (14.2%)		0	1 (14.2%)
Elmarghany et al 2017	1 (3%) deep	0	0	0	3 (9.4%)	0	3 (9.4%)		0	5 (15.6%)
Persinger et al 2018		1(3.2%)	3(9.7%) Mild asymptomatic		2(6%)	0				6 (19.4%)
Current study	1(5%) superficial	0	2 (10%) Mild asymptomatic	1 (5%)	1 (5%)	0			1(5%)	6 (30%)

## DISCUSSION

In-situ pinning is the traditional and most commonly-used treatment for SCFE, with generally good results and relatively low rate of AVN<sup>[2,5,6,17]</sup>. However, there is recent evidence that the persistent

metaphyseal deformity, in even a mild SCFE, leads to FAI, with a subsequent acetabular chondro-labral damage and early hip osteoarthritis<sup>[2,3,6,13,28]</sup>. Therefore, the goal of optimal treatment of moderate and severe SCFE is to arrest slip progression and to restore normal or near normal morphology of the head-neck

junction. A modified Dunn procedure has been introduced to achieve these optimal goals<sup>[2,7,13,19,20,28,33]</sup>. However, this technique is, technically challenging and more invasive than in situ pinning, with some inherent risk of AVN due to the proximity to the lateral retinacular vessels<sup>[2,4,24]</sup>. When executed by experienced surgeons, the modified Dunn procedure is an ideal option for moderate to severe SCFE<sup>[4,5,13,20,28,33]</sup>.

Radiographic assessment in the current study demonstrated improved all radiographic parameters, indicating normal or near-normal femoral head-neck anatomy; with significant correction of the slip angle and alpha angle, without excessive femoral neck shortening. The mean slip angle of the femoral head was corrected from  $61^\circ \pm 14.4$  preoperatively to  $10^\circ \pm 10.1$  postoperatively, with a mean correction of  $51^\circ \pm 10$ . The mean alpha angle was corrected from  $90.2 \pm 21^\circ$  preoperatively to  $49.1 \pm 8^\circ$  postoperatively, with a mean correction of  $42.1 \pm 13.2^\circ$ . The mean femoral neck length difference was  $8.1 \pm 6$  mm. These results were comparable to that of many other studies<sup>[3,5,6,19,20,28]</sup> (Table 3).

In this series, we restored near-normal postoperative ROM. The mean postoperative values: were  $105.5^\circ \pm 15.7^\circ$  flexion,  $42.4^\circ \pm 7.4^\circ$  ER in  $90^\circ$  flexion,  $36.0^\circ \pm 8.5^\circ$  IR in  $90^\circ$  flexion and  $40.0^\circ \pm 7.5^\circ$  abduction. This coincided with many other studies<sup>[3,6,28]</sup>.

Functional assessment of our cases demonstrated improved functional hip scores to a satisfactory degree. The mean Harris hip score (HHS)<sup>[30]</sup>, finally was  $86.2 \pm 9.6$  and the the Heyman and Herndon score<sup>[32]</sup>, was excellent and good in 15 cases (75%), fair in two cases, poor in two and failed in one. Our mean HHS was comparable to that of the series of Sankar *et al*<sup>[24]</sup>, but lower than that of other studies<sup>[3,6,20,28,34]</sup>, which may be attributed to involvement of more chronic slips, with some persistent postoperative pain and limited ROM because of muscular weakness; which may improve on the long-term. Good and excellent results according to the Heyman and Herndon score<sup>[32]</sup> in our series was higher than that in Novais *et al*<sup>[5]</sup> series, but lower than that in the studies of Cosma *et al*<sup>[19]</sup> and Elmarghany *et al*<sup>[20]</sup>, (Table 3).

In this study, despite postoperative complications occurred in 6 cases (30%), major complications occurred in only two cases (10%); AVN in one case and secondary FAI due to a bony spur at the head-neck junction in another case. The final ratings of these two patients according to the Heyman and Herndon system<sup>[32]</sup> were failed and fair respectively (Table 4).

Femoral head AVN is the most serious complication of SCFE<sup>[2-7,20,24,28,33]</sup>. AVN occurred in one of our patients (5%), who showed no intraoperative head perfusion. Previously reported incidence of osteonecrosis following modified Dunn procedure range from 0% to 26%<sup>[3,5,6,19,20,28,34]</sup> (Table 4). The risk is more after unstable SCFE<sup>[4,24,28,35]</sup>.

The mechanism of vascular injury is controversial. It may be due to direct injury, such as rupture, kinking, or stretching of the retinacular vessels or due to vascular tamponade; secondary to increased intraarticular pressure from bleeding. These may result from the slip itself or from the modified Dunn procedure; during dissection, due to over shortening with resultant vascular kinking, under-shortening, or incomplete removal of posteromedial callus<sup>[4,28,33,35-37]</sup>.

To lessen the risk of osteonecrosis in the treatment of SCFE, especially in unstable slips, many authors<sup>[2,3,6,28]</sup>, believed that the use of the modified Dunn procedure immediately after the development of symptoms would likely beneficial, as it allows a controlled tension-free reduction with direct visualization of the retinacular vessels<sup>[3,22,28]</sup>. Moreover, Jackson *et al*<sup>[33]</sup> demonstrated blood flow restoration in four patients by angiogram and in five by intracranial pressure (ICP)

monitor after the modified Dunn procedure.

Several methods of intraoperative assessment of femoral head perfusion exist. Described methods are bleeding sign from epiphyseal drilling; by a 2 mm K-wire into a non-weightbearing portion of the femoral head to a depth of 1 to 2 cm<sup>[3,19,33]</sup>, laser Doppler flowmetry<sup>[38]</sup> and intracranial pressure (ICP) monitor<sup>[33]</sup>. The existence of flow is not a guarantee against development of AVN, but its absence is predictive of AVN<sup>[33]</sup>. In our study, we used epiphyseal drilling, with demonstrated bleeding in all except one that developed AVN.

Implant failure did not occur in our series. This coincided with the findings of Cosma *et al*<sup>[19]</sup> and Elmarghany *et al*<sup>[20]</sup>, but did not coincide with the findings of many other authors<sup>[3,5,6,24,28,34]</sup>, who reported implant failure in their studies (Table 4). The ideal osteosynthesis in the modified Dunn procedure has not been well established<sup>[5]</sup>. Reported implants included two or three 3.0 mm fully threaded K-wires<sup>[3]</sup>, two 6.5-mm cannulated screws<sup>[19,33]</sup> and one threaded pin with one 7.3 mm fully threaded screw<sup>[28]</sup>. Tannast *et al*<sup>[7]</sup>, reported improved stability after using screws instead of pins that were used in their initial cases.

In this series, two cases (10%) required reoperation; for excision of a bony spurs at the femoral head-neck junction that led to FAI in one patient and removal of screws in another case with AVN. Sankar *et al*<sup>[24]</sup> recorded open osteoplasty of deformity secondary to AVN in one case (3.7%), core decompression for AVN in one case (3.7%), revision of failed osteosyntheses and removal of protruded implants in nine cases (33.5%) and total hip arthroplasty after AVN in one case (3.7%). Elmarghany *et al*<sup>[20]</sup> reported three reoperations in their series; removal of the protruded screws and arthro-diastasis after osteonecrosis in one case, debridement and screw removal for a case of late deep infection and readjustment of bad reduction in one case, (Table 4).

Neck shortening during the procedure is required to ensure a tension-free reduction of the femoral epiphysis. The amount of neck shortening is critical<sup>[5,19,28]</sup>. The optimal is the balance between a too short neck (resulting in instability and limb length discrepancy) and an appropriate neck length<sup>[3,7,19,28]</sup>. Unlike the other cuneiform osteotomies that involve excessive neck shortening, the modified Dunn procedure allows safe reduction by excising only the posterior callus and curetting the physeal plate, hence minimizing the amount of shortening<sup>[5,7,19,28,29,37]</sup>. In our series, we followed this concept and did not perform excessive shortening of the femoral neck. Distal advancement of the greater trochanter allows a relative lengthening of the femoral neck to prevent greater trochanter impingement against the pelvis<sup>[3]</sup>. We performed this advancement in five cases.

The intra- operative findings in our series included: (1) Chondrolabral damage in 15 cases (75%), that was more substantial in stable SCFE and in hips with a longer complaint; (2) Clinically assessed slip stability correlated with intraoperative physis stability only in the unstable SCFE. All clinically unstable SCFE had intraoperative instability. However, even in the clinically stable SCFE, five of 13 hips had partial intraoperative instability; (3) Bleeding of the femoral head after reduction was demonstrated in 19 cases (95%) and was absent in one head, which developed AVN, (Table 1). These findings were comparable to that of Slongo *et al*<sup>[3]</sup> and Zeibarth *et al*<sup>[6]</sup>.

Slongo *et al*<sup>[3]</sup> performed prophylactic fixation of the contralateral hip in all of their patients. We and others<sup>[5,6,7,19,28,35]</sup> fixed the contralateral hip, only if it developed slip.

Other surgical alternatives for treatment of moderate and severe SCFE exist, including in situ pinning<sup>[2,5]</sup>, in situ pinning followed by a staged femoral osteotomy<sup>[5]</sup>, in situ pinning combined with basal

neck or subtrochanteric femoral osteotomy<sup>[4]</sup>. In situ pinning is less technically-demanding, with a relatively low risk of osteonecrosis. However, its principal disadvantages are the lack of deformity correction and residual FAI after higher grades of SCFE, requiring secondary procedures<sup>[2-7,37]</sup>. In situ pinning combined or followed by more distal femoral osteotomies may be a safer and less technically demanding alternative compared to the modified Dunn procedure<sup>[4,5]</sup>. However, the modified Dunn procedure has the advantage of no secondary deformity creation and no second operation<sup>[4,6,7,19,28]</sup>.

The modified Dunn's procedure advantages include: (1) correction at the site of the deformity allowing normalizing the head - neck junction and lessening FAI with its subsequent chondrolabral damage and early osteoarthritis; (2) normal hip ROM and function; (3) visualization of the retinacular vessels in unstable SCFE will lessen the incidence of the retinaculum under tension by the callus or when the hip is reduced; (4) capsule decompression in unstable SCFE; and (5) no secondary deformity, unlike other more distal osteotomies<sup>[3,4,5,7,13,20,22,28,33]</sup>. The modified Dunn's procedure disadvantages include: (1) technically demanding requiring a steep learning curve; (2) not available at most centers; (3) more invasive; (4) the risk of osteonecrosis is higher than in-situ pinning and (5) many hips with in-situ pinning will do well for long periods<sup>[5, 7,24,37]</sup>.

The selection between use of modified Dunn's procedure or in-situ pinning often is based on experience of surgeon<sup>[5]</sup>. The correct meticulous execution of the surgical technique by experienced hands, usually achieves favorable clinical and radiological outcomes, with low rates of AVN - even in acute and higher-grades of SCFE<sup>[7]</sup>. Zeibarth *et al*<sup>[6]</sup>, believed it is worth the investment of effort and skill for a condition that could have lifelong sequelae in an active young population.

The limitations of our study include; a relatively small number of patients, absence of a comparison group and no long-term follow-up data.

## CONCLUSIONS

The modified Dunn procedure could be a reasonable, effective and safe treatment option for moderate and severe SCFE in patients with open physes, as it achieves better radiographic deformity correction of the head-neck junction, thus preventing FAI with its sequelae and better clinical outcome, with a reasonable complication rate. The potential risk of osteonecrosis could be avoided or lessened through the safe execution of the procedure, which requires full understanding of the hip vascular anatomy and good experience of the procedure.

## REFERENCES

1. Lehmann CL, Arons RR, Loder RT, Vitale MG. The epidemiology of slipped capital femoral epiphysis: an update. *J Pediatr Orthop.* 2006; **26**: 286-290. [DOI: 10.1097/01.bpo.0000217718.10728.70].
2. Loder RT, Aronsson DD, Weinstein SL, Breur GJ, Ganz R, Leunig M. Slipped capital femoral epiphysis. *Instr Course Lect.* 2008; **57**: 473-498. [PMID: 18399603].
3. Slongo T, Kakaty D, Krause F, Ziebarth K. Treatment of slipped capital femoral epiphysis with a modified Dunn procedure. *J Bone Joint Surg Am.* 2010 Dec; **92(18)**: 2898-908. [DOI: 10.2106/JBJS.1.01385].
4. Tibor LM, Sink EL. Risks and benefits of the modified Dunn approach for treatment of moderate or severe slipped capital femoral epiphysis. *J Pediatr Orthop.* 2013; **33(suppl 1)**: S99-S102. [DOI: 10.1097/BPO.0b013e3182860050].
5. Novais EN, Hill MK, Carry PM, Heare TC, Sink EL. Modified Dunn procedure is superior to in situ pinning for short-term clinical and radiographic improvement in severe stable SCFE. *Clin Orthop Relat Res* 2015; **473**: 2108-2117. [DOI: 10.1007/s11999-014-4100-1].
6. Ziebarth K, Zilkens C, Spencer S, Leunig M, Ganz R, Kim YJ. Capital realignment for moderate and severe SCFE using a modified Dunn procedure. *Clin Orthop Relat Res.* 2009 Mar; **467(3)**: 704-16. [DOI: 10.1007/s11999-008-0687-4].
7. Tannast M, Jost LM, Lerch TD, Schmaranzer F, Ziebarth K, Siebenrock KA. The modified Dunn procedure for slipped capital femoral. *J Child Orthop* 2017; **11**: 138-146. [DOI: 10.1302/1863-2548-11-170046].
8. Carney BT, Weinstein SL, Noble J. Long-term follow-up of slipped capital femoral epiphysis. *J Bone Joint Surg Am.* 1991; **73**: 667-674. [PMID: 2045391].
9. Hagglund G, Hansson LI, Sandstrom S. Slipped capital femoral epiphysis in southern Sweden. Long-term results after nailing/pinning. *Clin Orthop Relat Res.* 1987; **217**: 190-200. [PMID: 3829499].
10. O'Brien ET, Fahey JJ. Remodeling of the femoral neck after in situ pinning for slipped capital femoral epiphysis. *J Bone Joint Surg Am.* 1977; **59**: 62-68. [PMID: 833177].
11. Jones JR, Paterson DC, Hillier TM, Foster BK. Remodelling after pinning for slipped capital femoral epiphysis. *J Bone Joint Surg Br* 1990; **72**: 568-573. [PMID: 2380205].
12. Bellemans J, Fabry G, Molenaers G, Lammens J, Moens P. Slipped capital femoral epiphysis: a long-term follow-up, with special emphasis on the capacities for remodeling. *J Pediatr Orthop B.* 1996; **5**: 151-157. [PMID: 8866278].
13. Otani T, Kawaguchi Y, Marumo K. Diagnosis and treatment of slipped capital femoral epiphysis: Recent trends to note. *Journal of Orthopaedic Science.* 2018; **23**: 220-228. [DOI: 10.1016/j.jos.2017.12.009].
14. Rab GT. The geometry of slipped capital femoral epiphysis: Implications for movement, impingement, and corrective osteotomy. *J Pediatr Orthop.* 1999; **19**: 419-424. [PMID: 10412987].
15. Leunig M, Casillas MM, Hamlet M, Hersche O, Notzli H, Slongo T, Ganz R. Slipped capital femoral epiphysis. Early mechanical damage to the acetabular cartilage by a prominent femoral metaphysis. *Acta Orthop Scand.* 2000; **71**: 370-375. [DOI: 10.1080/000164700317393367].
16. Fraitz CR, Käfer W, Nelitz M, Reichel H. Radiological evidence of femoroacetabular impingement in mild slipped capital femoral epiphysis. *J Bone Joint Surg Br.* 2007; **89(B)**: 1592-1596. [DOI: 10.1302/0301-620X.89B12.19637].
17. Sink EL, Zaltz I, Heare T, Dayton M. Acetabular cartilage and labral damage observed during surgical hip dislocation for stable slipped capital femoral epiphysis. *J Pediatr Orthop.* 2010; **30**: 26-30. [DOI: 10.1097/BPO.0b013e3181c6b37a].
18. Dodds MK, McCormack D, Mulhall KJ. Femoroacetabular impingement after slipped capital femoral epiphysis: does slip severity predict clinical symptoms? *J Pediatr Orthop.* 2009; **29**: 535-539. [DOI: 10.1097/BPO.0b013e3181b2b3a3].
19. Cosma D, Vasilescu DE, Corbu A, Valeanu M, Vasilescu D. The modified Dunn procedure for slipped capital femoral epiphysis does not reduce the length of the femoral neck. *Pak J Med Sci.* 2016; **32(2)**: 379-384. [DOI: 10.12669/pjms.322.8638].
20. Elmarghany M, Abd El-Ghaffar TM, Seddik M, Akar A, Gad Y, Ragheb E, Aprato A & Massé A. Surgical hip dislocation in treatment of slipped capital femoral epiphysis. *SICOT J.* 2017; **3**: 10. [DOI: 10.1051/sicotj/2016047].
21. Gill TJ, Sledge JB, Ekkernkamp A, Ganz R. Intraoperative assessment of femoral head vascularity after femoral neck fracture. *J Orthop Trauma.* 1998; **12**: 474-8. [PMID: 9781771].
22. Ganz R, Gill TJ, Gautier E, Ganz K, Krügel N, Berlemann U. Surgical dislocation of the adult hip a technique with full access to the femoral head and acetabulum without the risk of avascular necrosis. *J*



- Bone Joint Surg Br.* 2001; **83**: 1119-1124. [PMID: 11764423].
23. Dunn DM. The treatment of adolescentslippingof the upper femoral epiphysis. *J Bone Joint Surg Br.* 1964; **46**: 621-9. [PMID: 14251447].
  24. Sankar WN, Vanderhave KL, Matheney T, Herrera-Soto JA, Karlen JW. The modified Dunn procedure for unstable slipped capital femoral epiphysis: a multicenter perspective. *J Bone Joint Surg [Am]* 2013; **95**: 585-591. [DOI: 10.2106/JBJS.L.00203].
  25. Fahey JJ, O'Brien ET. Acute slipped capital femoral epiphysis: review of the literature and report of ten cases. *J Bone Joint Surg Am.* 1965; **47**: 1105-27. [PMID: 14337771].
  26. Loder RT, Richards BS, Shapiro PS, Reznick LR, Aronson DD. Acute slipped capital femoral epiphysis: the importance of physeal stability. *J Bone Joint Surg Am.* 1993; **75**: 1134-40. [PMID: 8354671].
  27. Southwick WO. Osteotomy through the lesser trochanter for slipped capital femoral epiphysis. *J Bone Joint Surg. (Am).* 1967; **49**: 807-835.[PMID: 6029256].
  28. Persinger F, Davis RL II, Samora WP, Klingele KE. Treatment of Unstable Slipped Capital Epiphysis Via the Modified Dunn Procedure. *J Pediatr Orthop* 2018; **38**: 3-8. [DOI: 10.1097/BPO.0000000000000737].
  29. Leunig M, Slongo T, Kleinschmidt M, Ganz RI. Subcapital correction osteotomy in slipped capital femoral epiphysis by means of surgical hip dislocation. *OperOrthopTraumatol.* 2007; **19**: 389-410. [DOI: 10.1007/s00064-007-1213-7].
  30. Harris WH. Traumatic arthritis of the hip after dislocation and acetabular fractures: treatment by mold arthroplasty. An end-result study using a new method of result evaluation. *J Bone Joint Surg Am.* 1969; Jun; 51(4): 737-55. [PMID: 5783851].
  31. Marchetti P, Binazzi R, Vaccari V, Girolami M, Morici F, Impallomeni C, Commessatti M, Silvello L. Long-term results with cementlessFitek (or Fitmore) cups. *J Arthroplasty.* 2005 Sep; **20**(6): 730-7. [DOI: 10.1016/j.arth.2004.11.019].
  32. Heyman CH, Herndon CH. Epiphyseodesis for early slipping of the upper femoral epiphysis. *J Bone Joint Surg Am.* 1954; **36**: 539-555.[PMID: 13163086].
  33. Jackson JB, Frick SL, Brighton BK, Broadwell SR, Wang EA, Casey VF. Restoration of blood flow to the proximal femoral epiphysis in unstable slipped capital femoral epiphysis by modified Dunn procedure: A preliminary angiographic and intracranial pressure monitoring study. *J Pediatr Orthop.* 2018; **38**: 94-99. [DOI: 10.1097/BPO.0000000000000779].
  34. Huber H, Dora C, Ramseier LE, Buck F, Dierauer S. Adolescent slipped capital femoral epiphysis treated by a modified Dunn osteotomy with surgical hip dislocation. *J Bone Joint Surg Br.* 2011 Jun; **93**(6): 833-8. [DOI: 10.1302/0301-620X.93B6.25849].
  35. Maeda S, Kita A, Funayama K, Kokubun S. Vascular supply to slipped capital femoral epiphysis. *J Pediatr Orthop.* 2001; **21**: 664-667. [PMID: 11521038].
  36. Herrera-Soto JA, Duffy MF, Birnbaum MA, Vander Have KL. Increased intracapsular pressures after unstable slipped capital femoral epiphysis. *J Pediatr Orthop.* 2008; **28**: 723-728. [DOI: 10.1097/BPO.0b013e318186bda3].
  37. Loder RT. What is the cause of avascular necrosis in unstable slipped capital femoral epiphysis and what can be done to lower the rate? *J Pediatr Orthop.* 2013; **33**(suppl 1): S88-S91. [DOI: 10.1097/BPO.0b013e318277172e].
  38. Notzli HP, Siebenrock KA, Hempfing A, Vander Have KL. Perfusion of the femoral head during surgical dislocation of the hip. Monitoring by laser Doppler flowmetry. *J Bone Joint Surg Br.* 2002; **84**: 300-304. [PMID: 11922376].

Peer Reviewer: Wei Sun