

Anteversion of the Acetabular Cup Determined by Digital Radiographic Software as Compared to CT-Based Measurement

Ronen Debi, Omri Lubovsky, Ornit Cohen, Ira Bachar, Eytan M Debbi, Ehud Atoun

Ronen Debi, Omri Lubovsky, Ornit Cohen, Ira Bachar, Ehud Atoun, Department of Orthopedic Surgery, Barzilai Medical Center, Ashkelon, Israel. Affiliated to the Ben-Gurion University of the Negev, Beer sheva, Israel

Eytan M Debbi, Biorobotics and Biomechanics Lab, Faculty of Mechanical Engineering, Technion-Israel Institute of Technology, Haifa, Israel

Conflict-of-interest statement: The author(s) declare(s) that there is no conflict of interest regarding the publication of this paper.

Open-Access: This article is an open-access article which was selected by an in-house editor and fully peer-reviewed by external reviewers. It is distributed in accordance with the Creative Commons Attribution Non Commercial (CC BY-NC 4.0) license, which permits others to distribute, remix, adapt, build upon this work non-commercially, and license their derivative works on different terms, provided the original work is properly cited and the use is non-commercial. See: <http://creativecommons.org/licenses/by-nc/4.0/>

Correspondence to: Ehud Atoun MD, Department of Orthopedic Surgery, Barzilai Medical Center, Ashkelon, Israel. Affiliated to the Ben-Gurion University of the Negev, Beer sheva, Israel.

Email: dratoun@gmail.com

Telephone: +972577678722

Fax: +97246380044

Received: July 19, 2016

Revised: November 11, 2016

Accepted: November 14, 2016

Published online: December 28, 2016

ABSTRACT

AIM: Precision in determining cup positioning in patients after total hip arthroplasty (THA) is critical, especially in seek for the cause of symptoms in cases of postoperative pain, excessive wear and instability. Computed tomography scans (CT) were found to be superior at measuring the anteversion of the acetabular cup as compared to measurements performed on printed radiographs. The purpose of the present study was to compare acetabular anteversion

measured on digital radiographs with dedicated software to measurements carried out via CT.

METHODS: CT scans and radiograph exams were obtained from 62 patients after THA. Acetabular cup anteversion was measured from CT by CT-based image analysis software (Amira®) and from digital radiographs using dedicated measurement tool of a digital software (TraumaCAD®). Anteversion angles of the acetabular cup were calculated and compared.

RESULTS: Radiographic calculated acetabular anteversion angles were significantly lower than CT measurements (average difference of -13.8, $p < 0.001$), with a moderate correlation between methods ($r = 0.534$; $p < 0.001$). There was a significant correlation between radiographic error and anteversion angle ($r = 0.910$; $p < 0.001$), with the radiographs showing greater underestimation of the angle at greater angles.

CONCLUSIONS: Digital radiographic shows imprecision in measuring acetabular cup anteversion. Clinicians must consider this when making clinical decisions based on these radiographs.

Key words: Acetabulum; Cup; Orientation; Anteversion; Total hip arthroplasty; Radiography; X-Ray; CT

© 2016 The Author(s). Published by ACT Publishing Group Ltd.

Debi R, Lubovsky O, Cohen O, Bachar I, Debbi EM, Atoun E. Anteversion of the Acetabular Cup Determined by Digital Radiographic Software as Compared to CT-Based Measurement. *International Journal of Orthopaedics* 2016; 3(6): 658-661 Available from: URL: <http://www.ghrnet.org/index.php/ijo/article/view/1795>

INTRODUCTION

Evaluation of the acetabular cup positioning is critical in the postoperative evaluation of patients following total hip arthroplasty (THA). Poor orientation is highly correlated with pain, excessive wear and instability. Cup abduction and cup anteversion can be measured on printed radiographs using a variety of methods and formulas^[1-5]. While these were found to be precise in measuring cup abduction, they have been found to be unreliable at accurately determining cup anteversion^[6-10].

As an alternative to plain radiographs, computer tomography

scans (CT) can also be used to determine cup anteversion^{11,11-13}. CT measurements methods have been shown to have high precision, and although not a gold standard, are considered to be the most accurate method to date of determining cup anteversion postoperatively^{11,11,14-16}. Nevertheless, there are several downsides to CT, such as patient radiation, complexity in analysis, cost, availability and time. As such, researchers have continued to look for accurate methods of determining cup anteversion on plane radiographs^{11,11,12}.

Digital imaging software has gained popularity in recent years due to its success in precise preoperative planning for THA. Dedicated software was developed to enable easy, fast and accurate measurements of shapes and size of implants on digital radiographs^{10, 11}. This software also incorporate dedicated tools for evaluation of cup anteversion after THA. Their accuracy in this regard, however, has not yet been thoroughly examined.

The purpose of the present study was to examine the accuracy of digital imaging software tools for determining cup anteversion on digital radiographs in comparison to CT-based measurements. The study was designed to test the hypothesis that these tools would be as precise as CT-based tools.

MATERIALS AND METHODS

After receiving approval from the local ethical committee (IRB no. 0385-11) we retrospectively reviewed the notes and radiology files of 980 consecutive patients that underwent THR Between 2002 to 2006, in the Hadassah mount Scopus hospital. We identified patients that underwent a postoperative CT scan containing the pelvis in addition to a postoperative pelvic AP X ray. CT scans were performed due to variety of reasons in the days, months or years after surgery, most of them because of non-orthopedic indications (Suspected pulmonary embolism, pelvic and abdominal pathology etc...) yet had enough data to enable cup orientation analysis.

A conventional anteroposterior radiograph projection was taken of each patient. The film-focus distance was 1000 mm. The central beam was directed and the pubic symphysis and both hip joints (operated and non-operated) were in view. All radiographs were processed using the TraumaCAD[®] digital software system (TraumaCad, Voyant Health, Petah tikva, Israel). The software was used to measure the anteversion angles of the acetabular cup in each patient. The software extrapolates anteversion angle by measuring the area of the elliptical projection of the cup: The more area, the greater the magnitude of the anteversion (Figure 1).

Patient underwent a CT scan, using a GE Light Speed VCT (GE Corp, Fairfield, CT, USA) helical scans with 2.5-mm slices spaced 1.25 mm apart. CT image data for each patient were analyzed using the Amira[®] visualization and analysis software using a costume written code. (Amira, Visualization Sciences Group, Burlington, MA, USA). The software allows for the calculation cup anteversion by labeling the acetabular cup edge and the Anterior Pelvic Plain (APP) as a reference plane. Three landmark points define the APP: the foremost pubis landmark point (PUBIS), and the left and right anterior–superior iliac spine (ASIS-L, ASIS-R). The APP is directly computed from these three points. The Acetabular Cup anteversion is defined by a set of ten points on the acetabular cup edge. The points are identified on the acetabular cup boundary and selected on sequential CT axial cuts (Figure 2).

The data distributions were examined using Kolmogorov-Smirnov tests for normality. T-tests were used to examine the difference between digital radiographic measurements and CT-based measurements. Pearson correlation coefficients were determined for the relationship between system measurements. Additionally, the

angle differences were measured as a function of angles size using a correlation and regression analysis. Significance was set at $p < 0.05$.

RESULT

A total of 62 patients were found to have both post operative CT scan and digital X-rays of their pelvic. This study cohort consisted of 47 females and 15 males, with a mean age of 67.2 ± 12.8 years.

There was a significant average difference of $13.79 \pm 13.51^\circ$ between radiographic and CT-based anteversion angle measurements ($p < 0.001$), with radiographic measurements showing smaller acetabular anteversion angles. There was a significant, moderate correlation between angle measurements of both systems ($r = 0.534$; $p < 0.001$; Figure 3). The difference in anteversion angles between systems showed a high correlation with angle size ($r = -0.910$; $p < 0.001$; Figure 4), with a regression slope of -0.78 .

DISCUSSION

The orientation of the acetabular cup is a critical factor in patient follow-up after THA. Poor orientation can result in postoperative pain, prosthetic instability and accelerated wear¹⁷⁻²³. CT provides

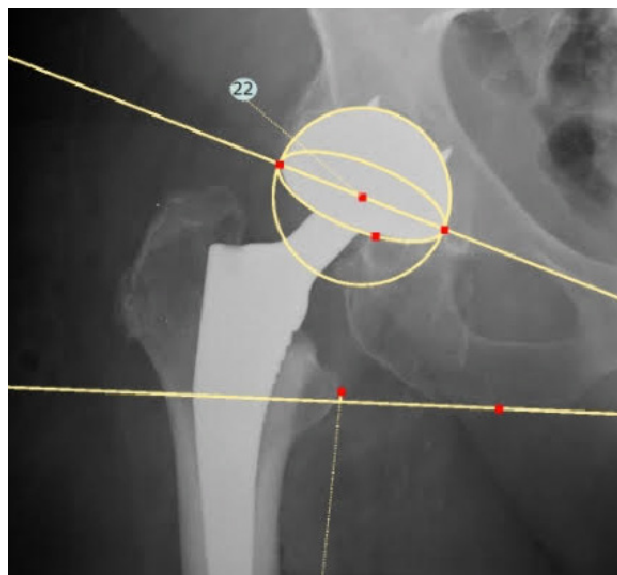


Figure 1 Measurement of acetabular cup anteversion angle on digital X ray.

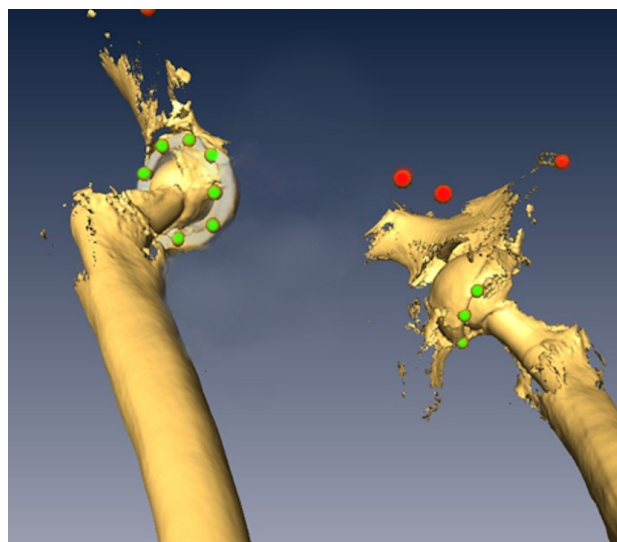


Figure 2 Measurement of acetabular cup anteversion angle on CT.

an accurate measurement of cup orientation, but expose the patient for higher dose of radiation, can be time consuming and costly^[1-4]. Therefore, traditionally, manual measurements have been used to measure abduction angle of the acetabular cup on the printed radiographs since they are relatively inexpensive, easy to interpret, more available and give low radiation exposure^[24]. Today, digital radiographs are widely spread and images are saved on picture archive and computerized systems (PACS) rather than being printed. We evaluated the accuracy of cup anteversion measurements on digital images by dedicated software.

The results of our study showed a significant difference between radiographic and CT-based anteversion angle measurements. Additionally, the range of error was relatively large, suggesting imprecision. Several other studies have also documented a significantly large error in anteversion angle as measured by printed radiography^[11]. Marx *et al* evaluated five algorithms for measuring radiographic acetabular anteversion and found that most show a significantly smaller angle ranging 14.3 to 14.5° (69-88% error) from CT-based measurements^[1,11-13]. They also found remarkably high standard deviations in measurements (10.2° to 10.8°)^[12]. The most accurate algorithm was Widmer's, which showed a difference of 6.4° (21.4% error) from CT-based measurements^[12]. The present study showed a difference of $13.79 \pm 13.51^\circ$ (48.4% error) from CT-based measurements. This suggests that the digital methods employed here are approximately as accurate as Widmer's algorithm, and superior to most other methods of calculating radiographic acetabular anteversion.

The present study also examined the correlation between angle difference and the CT-based angle measurements. Results indicated a very high correlation between the differences in anteversion measured and CT-based angle values ($r = 0.910$; regression slope -0.78). This trend was also studied by Marx *et al*, who showed similar trends of moderate correlations and regression slopes, with the lowest being for Widmer's algorithm^[12]. This demonstrates that the underestimation in angle showed by radiographic measures worsens as the true angle increases, and therefore much of the change is unaccounted for by radiographic measurements. Interestingly, the current study and Widmer's observed the lowest errors at anteversion angles in range of 10-20°.

The results of the present study suggest that calculating the elliptic parameters of the projection of the acetabular implant using digital imaging tools is not accurate at measuring cup anteversion as compared to measurements on postoperative CT. The source of error in radiographic measurements of acetabular anteversion angles can result from the variable pelvic tilt in each patient. Additionally, an observation of anteversion may actually be retroversion, as the two are indistinguishable on AP radiographs.

A further observation from the study results is that there may be a method of correcting for the radiographic error observed. A simple correction was first suggested by Ackland and Pradhan^[12], but considering the high correlation between true anteversion angle and error, a more complex correction is likely necessary. Correcting for the correlation alone is also possible, but this increases imprecision dramatically and therefore cannot be used alone either. Future studies should examine possible mathematical corrections for the radiographic measurements in hope of improving these calculations.

There are several limitations to the present study. This was a retrospective study of non-consecutive patients due to the need to obtain postoperative CT scans of the pelvic which are not routinely performed. We have used CT-based calculations of cup anteversion angle for comparison with the radiographic calculations. CT-based

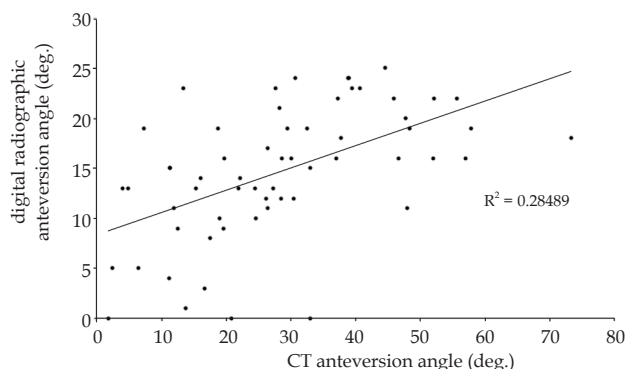


Figure 3 Correlation between digital radiographic measurements and CT-based measurements of acetabular anteversion angle.

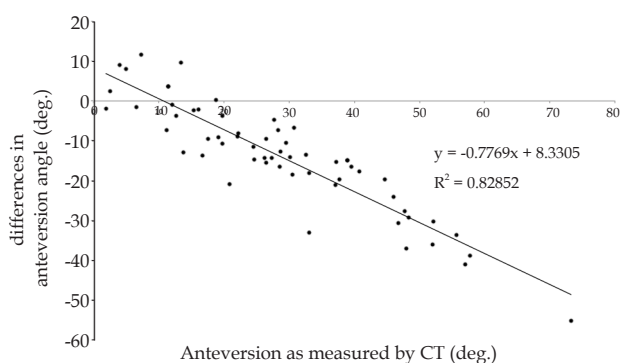


Figure 4 Correlation between differences between system measurements and CT-based measurements of acetabular anteversion angle.

calculations are not true measurements of cup abduction angle, but have been shown in previous studies to be of high accuracy^[7,9], and thus CT was assumed to be a valid reference tool.

REFERENCES

- Ghelman B, Kepler CK, Lyman S, Della Valle AG. CT outperforms radiography for determination of acetabular cup version after THA. *Clin Orthop Relat Res* 2009; **467**: 2362-2370. [DOI: 10.1007/s11999-009-0774-1]
- Biedermann R, Tonin A, Krismer M, Rachbauer F, Eibl G, Stockl B. Reducing the risk of dislocation after total hip arthroplasty - The effect of orientation of the acetabular component. *J Bone Joint Surg Br* 2005; **87B**: 762-769. [DOI: 10.1302/0301-620x.87b6]
- Kennedy JG, Rogers WB, Soffe KE, Sullivan RJ, Griffen DG, Sheehan LJ. Effect of acetabular component orientation on recurrent dislocation, pelvic osteolysis, polyethylene wear, and component migration. *J Arthroplasty* 1998; **13**: 530-534. [DOI: S0883-5403(98)90052-3]
- McCullum DE, Gray WJ Dislocation after total hip arthroplasty. Causes and prevention. *Clin Orthop Relat Res* 1990; 159-170
- Debbi E LO, Friks S, Rivkin G, Debi R, Atoun E. Acetabular Cup Abduction Angle Determined by Digital Radiographic Software as Compared to CT-Based Measurement. *International Journal of Orthopaedics* 2004; **1**: 52-54. [DOI: ISSN 2311-5106]
- Visser JD, Konings JG. A new method for measuring angles after total hip arthroplasty. A study of the acetabular cup and femoral component. *J Bone Joint Surg Br* 1981; **63B**: 556-559
- Ackland MK, Bourne WB, Uthoff HK. Anteversion of the acetabular cup. Measurement of angle after total hip replacement. *J Bone Joint Surg Br* 1986; **68**: 409-413
- Hassan DM, Johnston GH, Dust WN, Watson LG, Cassidy D.

- Radiographic calculation of anteversion in acetabular prostheses. *J Arthroplasty* 1995; **10**: 369-372. [DOI: S0883-5403(05)80187-1]
9. Pradhan R. Planar anteversion of the acetabular cup as determined from plain anteroposterior radiographs. *J Bone Joint Surg Br* 1999; **81**: 431-435
 10. Widmer KH. A simplified method to determine acetabular cup anteversion from plain radiographs. *J Arthroplasty* 2004; **19**: 387-390. [DOI: S0883540303006090]
 11. Kalteis T, Handel M, Herold T, Perlick L, Paetzel C, Grifka J. Position of the acetabular cup -- accuracy of radiographic calculation compared to CT-based measurement. *Eur J Radiol* 2006; **58**: 294-300. [DOI: 10.1016/j.ejrad.2005.10.003]
 12. Marx A, von Knoch M, Pfortner J, Wiese M, Saxler G. Misinterpretation of cup anteversion in total hip arthroplasty using planar radiography. *Arch Orthop Trauma Surg* 2006; **126**: 487-492. [DOI: 10.1007/s00402-006-0163-0]
 13. Varghese B, Muthukumar N, Balasubramaniam M, Scally A. Reliability of measurements with digital radiographs--a myth. *Acta Orthop Belg* 2011; **77**: 622-625
 14. Olivecrona H, Weidenhielm L, Olivecrona L, Beckman MO, Stark A, Noz ME, Maguire GQ, Jr., Zeleznik MP, Svensson L, Jonson T. A new CT method for measuring cup orientation after total hip arthroplasty: a study of 10 patients. *Acta Orthop Scand* 2004; **75**: 252-260. [DOI: 10.1080/00016470410001169]
 15. Blendea S, Eckman K, Jaramaz B, Levison TJ, Digioia AM, 3rd. Measurements of acetabular cup position and pelvic spatial orientation after total hip arthroplasty using computed tomography/radiography matching. *Comput Aided Surg* 2005; **10**: 37-43. [DOI: 0.3109/10929080500178032]
 16. Steppacher SD, Tannast M, Zheng G, Zhang X, Kowal J, Anderson SE, Siebenrock KA, Murphy SB. Validation of a new method for determination of cup orientation in THA. *J Orthop Res* 2009; **27**: 1583-1588. [DOI: 10.1002/jor.20929]
 17. Steinberg EL, Shasha N, Menahem A, Dekel S. Preoperative planning of total hip replacement using the TraumaCad system. *Arch Orthop Trauma Surg* 2010; **130**: 1429-1432. [DOI: 10.1007/s00402-010-1046-y]
 18. Kumar PG, Kirmani SJ, Humberg H, Kavarthapu V, Li P. Reproducibility and accuracy of templating uncemented THA with digital radiographic and digital TraumaCad templating software. *Orthopedics* 2009; **32**: 815. [DOI: 10.3928/01477447-20090922-08]
 19. Bertz A, Indrekvam K, Ahmed M, Englund E, Sayed-Noor AS. Validity and reliability of preoperative templating in total hip arthroplasty using a digital templating system. *Skeletal Radiol* 2012; **41**: 1245-1249. [DOI: 10.1007/s00256-012-1431-4]
 20. Schmidutz F, Steinbruck A, Wanke-Jellinek L, Pietschmann M, Jansson V, Fottner A. The accuracy of digital templating: a comparison of short-stem total hip arthroplasty and conventional total hip arthroplasty. *Int Orthop* 2012; **36**: 1767-1772. [DOI: 10.1007/s00264-012-1532-7]
 21. Efe T, El Zayat BF, Heyse TJ, Timmesfeld N, Fuchs-Winkelmann S, Schmitt J. Precision of preoperative digital templating in total hip arthroplasty. *Acta Orthop Belg* 2011; **77**: 616-621
 22. Whiddon DR, Bono JV, Lang JE, Smith EL, Salyapongse AK. Accuracy of digital templating in total hip arthroplasty. *Am J Orthop (Belle Mead NJ)* 2011; **40**: 395-398
 23. Brew CJ, Simpson PM, Whitehouse SL, Donnelly W, Crawford RW, Hubble MJ. Scaling digital radiographs for templating in total hip arthroplasty using conventional acetate templates independent of calibration markers. *J Arthroplasty* 2012; **27**: 643-647. [DOI: 10.1016/j.arth.2011.08.002]
 24. Huppertz A, Radmer S, Asbach P, Juran R, Schwenke C, Diederichs G, Hamm B, Sparmann M. Computed tomography for preoperative planning in minimal-invasive total hip arthroplasty: radiation exposure and cost analysis. *European journal of radiology* 2011; **78**: 406-413. [DOI: 10.1016/j.ejrad.2009.11.024]

Peer reviewer: Bulent Karslioglu