

Profunda Femoris Artery Branch Pseudoaneurysm following Total Hip Arthroplasty

Bikram Karmakar, Mark Horsley

Bikram Karmakar, Mark Horsley, Orthopaedic Surgery, Royal Prince Alfred Hospital, Missenden Rd, Camperdown, NSW 2050, Australia

Correspondence to: Bikram Karmakar, Orthopaedic Surgery, Royal Prince Alfred Hospital, Missenden Rd, Camperdown, NSW 2050, Australia

Email: bkar2007@uni.sydney.edu.au

Telephone: +61424996042

Received: May 10, 2015 Revised: June 20, 2015

Accepted: June 26, 2015

Published online: August 23, 2015

ABSTRACT

We discuss the case of patient who suffered a profunda femoris artery branch pseudoaneurysm following total hip arthroplasty. Notably this is a rare occurrence following anterolateral approach total hip arthroplasty. Adding to the diagnostic difficulty was the timing of presentation occurring in the subacute rather than the acute post-operative period. Presentation of a pseudoaneurysm following hip surgery can be variable. It is vital to note diagnostic clues as pseudoaneurysm can pose catastrophic consequences to the patient.

© 2015 The Authors. Published by ACT Publishing Group Ltd.

Key words: Profunda femoris artery; Pseudoaneurysm; Total hip arthroplasty

Karmakar B, Horsley M. Profunda Femoris Artery Branch Pseudoaneurysm following Total Hip Arthroplasty. *International Journal of Orthopaedics* 2015; 2(4): 379-382 Available from: URL: <http://www.ghrnet.org/index.php/ijo/article/view/1215>

INTRODUCTION

Arterial injuries occur rarely following total hip arthroplasty. Pseudoaneurysm formation of the profunda femoris artery branches is particularly rare and is identified only sporadically in case reports^[1,2]. Pseudoaneurysm formation can lead to haemodynamic compromise in the acute setting but is also an important differential that must be considered in the subacute post operative period as well. We discuss a case involving the diagnosis of a pseudoaneurysm of a profunda femoris artery branch in the subacute period following hip arthroplasty using the anterolateral approach.

CASE DESCRIPTION

A 64 year old gentleman underwent an elective primary right cemented total hip replacement for management of osteoarthritis. Prior to the surgery, the patient mobilised independently and had no significant medical co-morbidities. His height was 182 centimetres and weight was 75 kilograms (BMI-22.6). Pre-operatively he had a range of motion of 90 degrees flexion with no fixed flexion deformity, internal rotation in flexion was 0 degrees and external rotation in flexion was 20 degrees. A modified Hardinge anterolateral approach in the supine position was used by the primary surgeon with the aid of two surgical assistants.

There were no technical difficulties during the operation nor was there excessive bleeding noted. During the approach to the hip joint, a separate curved retractor was placed anteriorly over the anterior rim of the acetabulum. A two pronged retractor was placed posteriorly to retract the proximal femur. The inferior capsule was divided sharply and a sharp Hohmann retractor was placed deep to the transverse acetabular ligament. An anterior capsulectomy was performed and the hip dislocated with gentle external rotation. In preparing

the femur a two pronged retractor was placed lateral to the greater trochanter and a broad Hohmann retractor was placed posterior to the divided femoral neck. No retractor was placed around the lesser trochanter. The stem was cemented and fixation of the acetabular cup occurred without cement or screws.

The patient was given DVT prophylaxis with clexane 40mg per day. Haemoglobin on postoperative day 1 was 105 g/L and on day 2 was 96 g/L compared to preoperative haemoglobin of 138 g/L. The patient was not symptomatic of anaemia and there was no neurovascular compromise. He mobilised on day 1 post operatively. He progressed appropriately with physiotherapy and was transferred to a rehab hospital as a bridge to managing independently at home.

At post-operative day 9 the patient was transferred back to the emergency department after noticing increased right hip swelling after rolling on to that side the previous night. He had significant pain on mobilising having previously mobilised without pain. His haemoglobin was 90g/L but he was not symptomatic with his anaemia. A hip x-ray was performed and demonstrated no evidence of fracture or dislocation. He was given analgesia and transferred back to his rehab hospital without further investigation.

The patient returned at his scheduled 6 week follow up. After discharge from rehab he had resumed many of his normal activities including gardening and riding his bike. He reported increased right hip swelling but required no analgesia and was otherwise well, afebrile and vitally stable. Doppler ultrasound of his hip demonstrated a large haematoma on the lateral aspect of the hip measuring 3.5×4.1×11 cm with an estimated volume of 310 millilitres. Significantly there was also flow evidenced on the medial aspect of the collection with yin-yang colour form (Figure 1) and 'to and fro' waveform pattern (Figure 2). These patterns have been described as suggestive of pseudoaneurysm^[3,4]. Angiogram was subsequently performed and confirmed the presence of a moderate sized pseudoaneurysm from the lateral segmental branch of the profunda artery (Figure 3). Cannulation was attempted but this caused vasospasm. The lateral segmental branch was subsequently occluded with multiple 4 mm and 5 mm coils (Figure 4). There were no complications following the embolisation with slow resorption of the haematoma. The patient was discharged the following day. He was reviewed 6 weeks after the procedure and had no residual issues and was mobilising independently.

DISCUSSION

Vascular injury during hip arthroplasty is rare. Nachbur *et al*^[5] reported the incidence of vascular injuries in surgeries of the hip joint to be 0.25% between 1970 and 1978. Calligaro *et al*^[6] reported arterial complications in 8 out of 9581 (0.08%) patients who underwent total hip arthroplasty between 1989 and 2002. Nachbur *et al* suggested that causes of arterial injury during hip surgery include perforation from the tip of a Hohmann retractor, intimal injury during manoeuvres with subsequent thrombus formation, thrombus formation secondary to the heat of polymerisation, direct trauma as well as trauma from bone cement, screws and osteophytes from the acetabulum^[5].

Pseudoaneurysm of the Profunda femoris artery after primary hip arthroplasty is extremely rare. It may occur with different approaches to the hip. The timing of presentation varies. Sharma *et al* reported a patient 2 months following a primary total hip arthroplasty performed with an anterolateral approach presenting with peripheral ischaemia. Angiogram subsequently revealed pseudoaneurysm of the profunda femoris artery^[7]. In another case report the patient underwent a posterior approach to the total hip replacement during

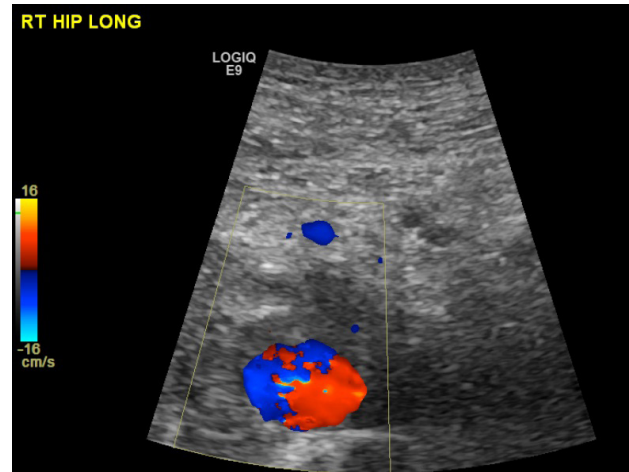


Figure 1 Doppler ultrasound appearance of yin-yang colour form suggestive of pseudoaneurysm.

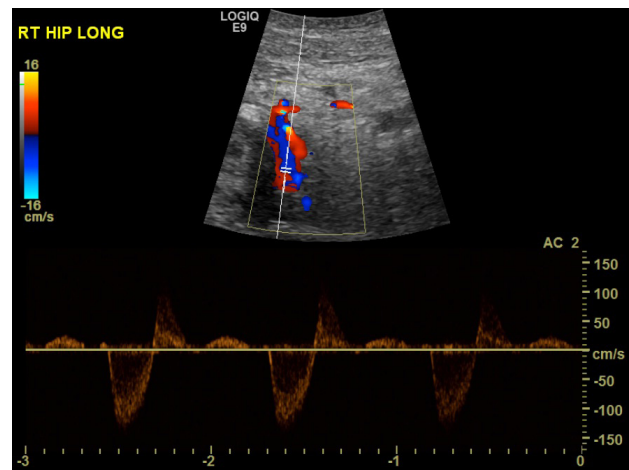


Figure 2 Doppler ultrasound appearance 'to and fro' waveform suggestive of pseudoaneurysm.

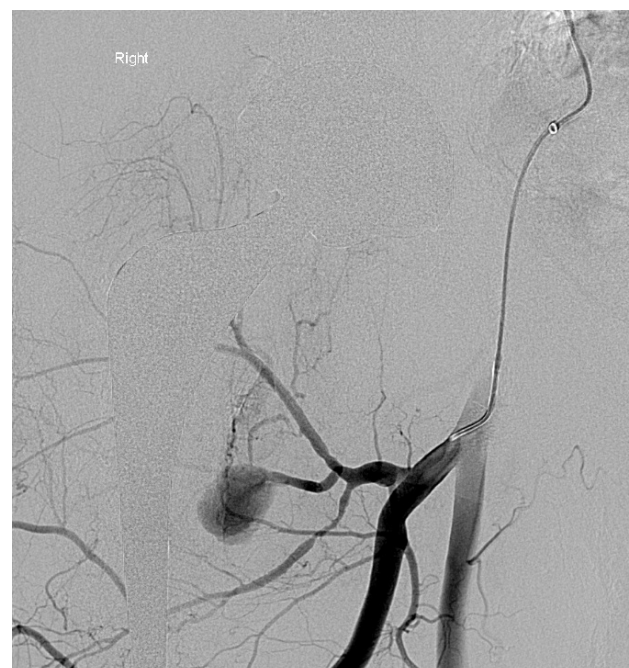

Figure 3 Angiogram appearance of pseudoaneurysm of lateral segmental branch of profunda femoris artery and relation to stem of hip prosthesis.

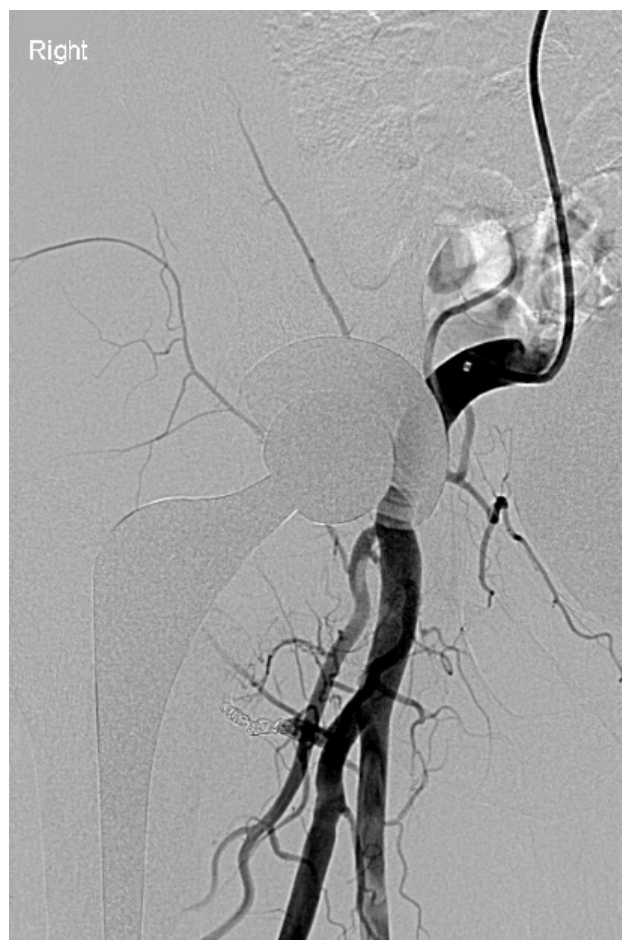

Figure 4 Angiogram post occlusion of pseudoaneurysm with multiple coils.

which significant bleeding occurred intraoperatively when an anterior osteophyte from the acetabulum was removed using an osteotome. However, no bleeding point was identified at the time of surgery. The patient was stabilised following blood transfusions but on day 18 was anticoagulated following cerebral infarction. Pseudoaneurysm of the profunda femoris artery at the level of the lesser trochanter was diagnosed on angiography 39 days post operatively following wound breakdown^[2]. Lund et al described a case of pseudoaneurysm of the medial circumflex femoral artery following cemented Charnley Elite system using the anteromedial approach however, the timeframe of diagnosis was not reported by the authors^[1]. Hall et al described a case of avulsion of a posterior branch of the profunda femoris artery following primary hip arthroplasty; the approach used was not documented. Again the patient became unstable immediately postoperatively with falling haemoglobin despite 9 units of blood transfused^[8]. The patients in all of these cases had an increasing non-pulsatile thigh swelling^[1,2,7,8].

The approach to the hip joint may implicate which vessel is more likely to be injured. Sharma et al performed a questionnaire on members of the British hip society regarding vascular injuries experienced during hip arthroplasty. There were 12 cases of vascular injury that occurred during primary hip arthroplasty and pseudoaneurysm of the profunda femoris artery occurred in 2 cases. On one occasion this occurred with the anterolateral approach and the other time with a posterior approach. The anterolateral approach was utilised in 4 of the remaining 10 cases and was associated with injury to the femoral artery on 3 of those occasions and the external iliac artery in the remaining case^[7].

More commonly pseudoaneurysm formation of the profunda femoris artery has been noted with revision hip arthroplasty or fracture displacement or fixation. A profunda femoris pseudoaneurysm was diagnosed in one case report 4 years after a Birmingham resurfacing procedure using the anterolateral approach with the patient in the lateral position^[9]. Laohapoonrungeesee and Sirirungruangsam reported two cases of profunda femoris artery pseudoaneurysm following Gamma nail and Dynamic hip screw procedures for intertrochanteric fractures. Pseudoaneurysm was diagnosed two months post procedure in the Gamma nail case. The area of aneurysm in their case corresponded to the site of screw protrusion on angiography. Pseudoaneurysm developed almost immediately postoperatively in the Dynamic hip screw case. Hence, the authors suggested shorter interval was likely due to pseudoaneurysm developing from intra-operative trauma from drill bits or placement of retractors^[10].

Although pseudoaneurysm of the profunda femoris artery has been diagnosed following hip operations it remains a rare complication following primary hip arthroplasty. The sharp Hohmann retractor placed deep to the transverse acetabular ligament was the nearest retractor to the aneurysm and hence this may be the cause of the pseudoaneurysm in this case report. Alternative causes that we propose include excessive traction with this retractor or possibly the division of the inferior capsule. We suggest more care during the insertion of the inferior retractor as well as use of a blunt Hohmann retractor. Furthermore, the retraction of the inferior Hohmann may obscure any initial bleeding and therefore damage to the artery may be unrecognised at the time of the operation. The literature would suggest it is rare for pseudoaneurysm to form in any location following the anterolateral approach. Our case highlights the need to be extra vigilant in assessing for potential vascular injury after total hip arthroplasty as indicators such as acute bleeding, peripheral ischaemia, pulsatile mass or an acutely unstable patient that may otherwise provide diagnostic clues do not have to be present for a diagnosis of a pseudoaneurysm of a profunda femoris branch to be considered.

CONCLUSION

Pseudoaneurysm of the profunda femoris artery is a rare complication of hip surgery especially with the anterolateral approach. Although the patient had a relatively uncomplicated recovery, pseudoaneurysm formation can be a potentially catastrophic complication. Many possible causes have been offered to explain acute pseudoaneurysm post hip operations. There is no clear explanation of the development of pseudoaneurysm post hip replacement in the subacute period. The inferior retractor deep to the transverse acetabular ligament is a possible cause of trauma to branches of the profunda femoris artery. We would also advocate for there to be a low threshold to perform imaging in cases of thigh swelling in the subacute period. Doppler ultrasonography is a useful non-invasive test that can be performed on patients presenting with swelling post hip surgery.

CONFLICT OF INTERESTS

There are no conflicts of interest with regard to the present study.

REFERENCES

- 1 Lund, J. M., Clarke, J. M. F., & Cockburn, J. F. (2002). Medial Circumflex Femoral Artery Pseudoaneurysm Following Total Hip Replacement Treated by Coil Embolisation. *European Journal of*

- Vascular and Endovascular Surgery, 24(2), 182-183.
- 2 Nozawa, M., Irimoto, M., Maezawa, K., Hirose, T., Shitoto, K., & Kurosawa, H. (2000). False Aneurysm of the Profunda Femoris Artery After Total Hip Arthroplasty. *The Journal of Arthroplasty*, 15(5), 671-674.
 - 3 Kapoor, B. S., Haddad, H. L., Saddekni, S., & Lockhart, M. E. (2009). Diagnosis and Management of Pseudoaneurysms: An Update. *Current Problems in Diagnostic Radiology*, 38(4), 170-188.
 - 4 Gaitini, D., Razi, N. B., Ghersin, E., Ofer, A., & Soudack, M. (2008). Sonographic evaluation of Vascular Injuries. *Journal of Ultrasound in Medicine*, 27(1), 95-107.
 - 5 Nachbur, B., Meyer, R. P., Verkkala, K., & Zurcher, R. (1979). The Mechanisms of Severe Arterial Injury in Surgery of the Hip Joint. *Clinical Orthopaedics and Related Research*, 141, 122-133.
 - 6 Calligaro, K. D., Dougherty, M. J., Ryan, S., & Booth, R. E. (2003). Acute arterial complications associated with total hip and knee arthroplasty. *Journal of Vascular Surgery*, 38, 1170-1177.
 - 7 Sharma, D. K., Kumar, N., Mishra, V., & Howell, F. R. (2003). Vascular injuries in total hip replacement arthroplasty: a review of the problem. *American Journal of Orthopaedics*, 32(10), 487-491.
 - 8 Hall, C., Khan, W. S., Ahmed, S. I., & Sochart, D. H. (2009). A rare case of arterial avulsion presenting with occult blood loss following total hip arthroplasty: a case report. *Journal of Medical Case Reports*, 3, 9320.
 - 9 Thomas, M. S., O'Hara, J. N., & Davies, A. M. (2012). Profunda femoris pseudoaneurysm following Birmingham hip resurfacing: an important differential diagnosis for a periarticular cystic mass. *Skeletal Radiology*, 41(7), 853-856.
 - 10 Laohapoonrungrsee, A., & Sirungruangsarn, Y. (2005). Pseudoaneurysm of Profunda Femoris Artery Following Internal Fixation of Intertrochanteric Fracture: Two Cases Report. *Journal of the Medical Association of Thailand*, 88(11), 1703-1706.

Peer reviewers: Wei Huang, MD, PhD, Professor, Department of Orthopaedic Surgery, The First Affiliated Hospital of Chongqing Medical University, No.1 Youyi Road, Yuzhong District, Chongqing 400016, China; Mohd Yusof Baharuddin, Research Fellow, Centre for Biomedical Engineering Transportation Research Alliance, Universiti Teknologi Malaysia, 81310 Skudai, Johor, Malaysia.