

Hemophagocytic Lymphohistiocytosis

Tarun Kumar Dutta, B Hitha

Tarun Kumar Dutta, B Hitha, Department of Clinical Hematology, Jawaharlal Institute of Postgraduate Medical Education & Research (JIPMER), Puducherry 605006, India

Correspondence to: Tarun Kumar Dutta, Professor, Head, Department of Clinical Hematology, Jawaharlal Institute of Postgraduate Medical Education & Research (JIPMER), Puducherry 605006, India.

Email: tkduttajipmer@yahoo.co.uk

Telephone: +91-9443602330

Received: January 4, 2015 Revised: March 16, 2015

Accepted: March 21, 2015

Published online: April 30, 2015

ABSTRACT

Hemophagocytic lymphohistiocytosis (HLH) is a disease characterised by pathological immune activation, fatal hyperinflammation, tissue injury and death if left untreated. It may be primary (genetic or familial) due to mutation in the genes involved in granule dependent cytolytic secretory pathway or sporadic, associated with a variety of triggers. The disease is characterized by fever, cytopenias, splenomegaly, hypertriglyceridemia and/or hypofibrinogenemia and hemophagocytosis. The clinical picture may be mimicked by many conditions like infections, systemic inflammatory response syndrome, rheumatological diseases, malignancies etc, causing the timely diagnosis a challenge. Early recognition and institution of chemoimmunotherapy improves the chance of survival in this potentially fatal disease.

© 2015 ACT. All rights reserved.

Key words: Targeted therapy; Personalized medicine

Dutta TK, Hitha B. Hemophagocytic Lymphohistiocytosis. *International Journal of Hematology Research* 2015; 1(1): 7-11
Available from: URL: <http://www.ghrnet.org/index.php/ijhr/article/view/1009>

INTRODUCTION

Hemophagocytic lymphohistiocytosis (HLH) is a rare but fatal disorder characterised by uncontrolled activation of immune system resulting in a pathological systemic inflammatory state with multiorgan involvement, tissue destruction and high mortality rate if left untreated. The incidence of HLH is estimated to be 1.2/1000000 individuals^[1]. The first description of HLH dates back to 1952 when it was called “familial hemophagocytic reticulosis” in a case report published by Farquhar JW and Claireaux AE^[2]. The identification of perforin mutation in 1999 by Stepp *et al* as the first genetic mutation associated with HLH was a major leap in understanding the genetic basis of the disease^[3]. Since then, major advances have occurred in the diagnostic and therapeutic aspects of HLH. Even so, our understanding of the disease is still incomplete. HLH is a rare disease. The estimated prevalence in various parts of the world is as – 1/100000 cases in USA; 1.2/1000000 cases in Sweden; 0.342 in Japan and 7.5/1000 in Turkey^[4]. The disease occurs in all age groups and all ethnic groups.

PATHOGENESIS

The clinical features of HLH arise due to three basic defects: (1) Abnormal stimulation and uncontrolled activation of cytotoxic CD8 T lymphocytes and macrophages and depressed NK cell activity, following an immune trigger; (2) Hypercytokinemia with markedly elevated proinflammatory cytokines leading to systemic inflammatory response and organ dysfunction; (3) Proliferation and tissue infiltration by macrophages and hemophagocytes with uncontrolled tissue destruction.

Tissues of haematopoietic and lymphoid function are directly involved; other organs are secondarily damaged by circulating cytokines and chemokines^[5]. Cytopenias result mainly from suppression of hematopoiesis by elevated inflammatory cytokines such as TNF- α and IFN- γ and from engulfment of hematopoietic cells by bone marrow macrophages^[6]. The serum concentrations of these cytokine levels in HLH are markedly elevated. HLH

patients have low numbers of hematopoietic stem cells (HSCs), and hematopoietic stem cells from HLH patients down-regulate CD47 and are prone to be engulfed by macrophages more actively than normal HSCs. Inflammatory cytokines can down-regulate the expression of CD47 selectively in HSCs^[7].

Types of HLH

HLH is broadly divided into primary and secondary forms (Table 1).

Primary form occurs in children who have genetic defects leading to abnormalities in proteins that play important role in cytolytic secretory pathway causing abnormal cytotoxic function of T cells and NK cells. Examples are Familial HLH1, FHLH2 (perforin 1 gene mutation), FHLH3 (MUNC13.4), FHLH4 (STX11), FHLH5 (STXBP2), Chediak Higashi, Griscelli2, Hermansky Pudlak2, XLP syndrome (X linked lymphoproliferative syndrome)^[4] (Table 1).

Secondary form occurs in adolescents, adults or elderly in the context of an underlying disorder which may be an infection (bacterial, viral, protozoal), rheumatological disorder (systemic onset juvenile idiopathic arthritis, adult onset still's disease, systemic lupus erythematosus (SLE) and malignancies (lymphoma, leukemia and solid tumors)^[8].

Macrophage activation syndrome (MAS) is the type of HLH arising in the context of rheumatological disorders.

In a series of eight cases from our institute, various diseases associated with HLH were tuberculosis, EBV infection, lymphoma, scrub typhus and dengue fever. Scrub typhus and dengue fever are exclusively uncommon causes in the West. Three patients died including one with scrub typhus and overall mortality was 38% at a median follow up of 13 months (unpublished report).

Clinical Features (Table 2)

The important clinical features are fever, hepatosplenomegaly, cytopenias, coagulopathy and bleeding manifestations, liver dysfunction (acute hepatitis and liver failure), neurological abnormalities (seizure, altered sensorium, cranial nerve palsy), skin rash and pulmonary dysfunction.

In patients with FUO, the presence of cytopenias and highly elevated ferritin should prompt physicians to suspect HLH. Cytopenia occurs in more than 80% of patients at disease presentation^[6]. HLH

should also be considered in the differential diagnosis of hepatitis and acute liver failure. Nearly 95% of HLH patients have features of disseminated intravascular coagulation (DIC)^[5]. Prevalence of haemophagocytosis in association with HLH diagnosis ranges from 25 to 100%, with 1-10 haemophagocytes per 500 cells in cases reported as positive^[9]. Skin manifestations include generalized maculopapular erythematous rashes, generalized erythroderma, oedema, panniculitis, morbilliform erythema, petechiae, and purpura^[10]. Neurological symptoms, including seizures, meningismus, decreased level of consciousness, cranial nerve palsy, psychomotor retardation, ataxia, irritability and hypotonia; and are encountered in more than one third of the patients^[5].

The importance of recognising this rare disorder cannot be underestimated considering a reported mortality of 95% if left untreated^[1]. Early diagnosis and institution of treatment brings down the mortality to 8-24 %^[4]. Hence HLH should be considered as a medical emergency. The crucial challenge as far as HLH is concerned is establishing a timely diagnosis. HLH is a syndromic diagnosis made when a constellation of clinical features and laboratory abnormalities coexist; since most of the signs and symptoms of HLH are nonspecific and they can occur in any systemic inflammatory state.

Differential Diagnosis

The disease itself is a great mimicker. Following conditions may be considered in differential diagnosis (Table 3).

In adults HLH may be mistaken for infection with sepsis syndrome, hepatitis, leishmania donovani infection, haematological malignancy etc. In pediatric age group, HLH like clinical presentation may be misinterpreted as a metabolic disorder with organomegaly and hypertriglyceridemia, Kawasaki syndrome^[11], Langerhans cell histiocytosis and neonatal hemochromatosis^[4]. These factors along with the rarity of the disease, lack of specificity of the diagnostic criteria and absence of a single gold standard test which clinches the diagnosis result in substantial delay in diagnosing HLH in most instances. This delay is detrimental, as early initiation of treatment before significant organ damage is mandatory for adequate recovery. Maintaining a high index of suspicion is the only solution for this dilemma. HLH should be suspected in any patient with prolonged and unexplained fever, hepatosplenomegaly, unexplained liver dysfunction, cytopenias, coagulopathy and central nervous system (CNS) dysfunction, in the background of any disease which can trigger HLH. Occasionally features of severe sepsis and SLE may be totally indistinguishable from HLH, when absence of hyperfibrinogenemia, extreme hyperferritinemia and hypertriglyceridemia distinguish sepsis from HLH. Extreme hyperferritinemia (level>30000 µg/mL) is almost diagnostic of HLH^[1].

Table 1 Classification.

| | |
|------------------------|---|
| Primary HLH : | Familial HLH1, FHLH2 (perforin 1 gene mutation), FHLH3 (MUNC13.4), FHLH4 (STX11), FHLH5 (STXBP2), Chediak Higashi, Griscelli2, Hermansky Pudlak2, XLP syndrome (X linked lymphoproliferative syndrome) ^[4] . |
| Secondary HLH : | |
| Infections | Bacterial including tuberculosis, viral, protozoal |
| Collagen disease | Systemic onset juvenile idiopathic arthritis, adult onset still's disease, systemic lupus erythematosus (SLE) |
| Malignancy | lymphoma, leukemia and solid tumors |

Table 2 Clinical Features of HLH.

| |
|---|
| Fever |
| Hepatosplenomegaly |
| Cytopenias |
| Coagulopathy & bleeding manifestations |
| Liver dysfunction (acute hepatitis & liver failure) |
| CNS dysfunction (seizure, altered sensorium, cranial nerve palsy) |
| Skin rash |
| Pulmonary dysfunction |

Table 3 Differential diagnosis.

| |
|--|
| 1. Infections - Sepsis syndrome, SIRS, Leishmania donovani infection |
| 2. Fever of unknown origin |
| 3. Hepatitis or acute liver failure |
| 4. Rheumatological disorders |
| 5. Hematological malignancies |
| Pediatric age group |
| 6. Langerhans cell histiocytosis |
| 7. Kawasaki's disease |
| 8. Hemochromatosis |
| 9. Metabolic diseases with pancytopenia and hepatomegaly |

Diagnostic Criteria

To overcome these difficulties, the Histiocytic Society proposed standard diagnostic criteria based on the common clinical findings, laboratory and histopathological findings in 1991. The HLH-1994 criteria included: (1) Fever; (2) Splenomegaly; (3) Cytopenias affecting at least two out of three lineages in peripheral blood; (4) Hypertriglyceridemia and/or hypofibrinogenemia; (5) Hemophagocytosis in bone marrow, spleen or lymph nodes (Table 4).

The major drawback of this diagnostic criteria was the lack of specificity. Liver dysfunction and CNS dysfunction which often give us clue to diagnosis are not included in this criteria. The criteria was updated by the Histiocytic Society in 2004 to include three more criteria: (1) Hyperferritinemia; (2) Low/absent NK cell activity; (3) Elevated soluble CD25 level. The presence of severe abnormality in any of these is particularly helpful in diagnosis. Serum Ferritin level $>10000 \mu\text{g/mL}$ has 93% specificity; $>30000 \mu\text{g/mL}$ has 100% specificity in making the diagnosis^[11]. Similarly, sCD25 level (sIL2r) reflects the degree of activation of T cells and is useful in diagnosis as well as follow up. Very high levels are never seen outside the setting of HLH. The HLH-2004 diagnostic criteria is given in table 4^[12].

Criticism to this diagnostic criteria

The major drawback of these diagnostic criteria was the lack of specificity. Liver dysfunction and CNS dysfunction which often give us clue to diagnosis are not included in these criteria^[9].

Newer Tests

The new laboratory tests evolving are CD163 (marker for activation of scavenger macrophages), decreased intensity of CD107a signalling on peripheral blood mononuclear cell surface (suggestive of a genetic cause for failure of degranulation), perforin protein expression by flow cytometry, gene sequencing of FHLH and XLP genes^[11]. Mutation analysis should be requested for all suspected familial HLH^[5]. Needless to say, the diagnosis of HLH can be made without need to fulfil 5/8 criteria if the characteristic genetic defect can be demonstrated. It should include analysis of known HLH mutations - PRF 1, UNC 13 D, STX 11 and UNC 18 B.

Table 4 Diagnostic criteria for HLH.

| Diagnostic guidelines for HLH: the HLH-2004 criteria: | HLH -94 Criteria: |
|---|---|
| HLH diagnosed if one of either (A) or (B) below is fulfilled: | 1) Fever |
| (A) A molecular diagnosis consistent with HLH (Familial HLH) | 2) Splenomegaly |
| (B) Diagnostic criteria for HLH fulfilled (Five of the Eight criteria below) | 3) Bicytopenia |
| (a) Initial diagnostic criteria | 4) Hypertriglyceridemia and/or hypofibrinogenemia |
| 1. Fever $\geq 38.5^\circ\text{C}$ | 5) Hemophagocytosis |
| 2. Splenomegaly | |
| 3. Cytopenia (affecting at least two of three lineages in the peripheral blood): Hemoglobin $<90\text{g/L}$; Platelets $<100 \times 10^9/\text{L}$ Neutrophils $<1.0 \times 10^9/\text{L}$ | |
| 4. Hypertriglyceridemia and/or hypofibrinogenemia Fasting triglycerides $\geq 265 \text{ mg/dL}$; Fibrinogen $\leq 1.5 \text{ g/L}$ | |
| 5. Hemophagocytosis in bone marrow, spleen or lymph nodes | |
| No evidence of malignancy | |
| (b) New diagnostic criteria | |
| 6. Low or absent NK cell activity (according to local laboratory reference) | |
| 7. Ferritin $\geq 500 \text{ ng/mL}$ | |
| 8. Soluble CD25 $\geq 2,400 \text{ U/mL}$. | |

TREATMENT

The mainstay of treatment of HLH is a combination of immunotherapy and chemotherapy (Table 5).

HLH 1994 Protocol (Figure 1)

The first international treatment protocol for HLH was organized by International Histiocytic Society in 1994. This included 8 week induction therapy with corticosteroids, dexamethasone, etoposide, cyclosporine and intrathecal methotrexate. Corticosteroids are used to suppress hypercytokinemia, and chemotherapy with etoposide blocks cell division and proliferation^[5]. This was combined with intrathecal methotrexate for patients in whom CNS HLH did not remit with two weeks of dexamethasone^[12]. Cyclosporine inhibits T cell activation (IL-2 inhibition) (Figure 2)^[13]. In HLH 94 trial, mortality was reduced from 95% to 30-35 % and reported 3 year survival was 55 %^[14].

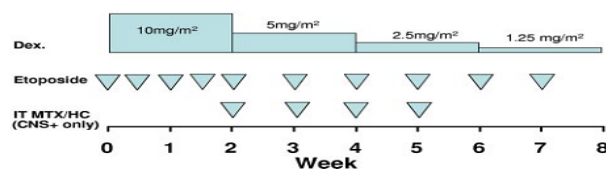HLH 2004 Protocol (Figure 3)

In HLH-2004, the 1994 protocol was revised. It consists of 1-8 week therapy with etoposide, cyclosporine and dexamethasone. At the end of 8 weeks, if the disease is resolved and is nongenetic, the therapy is stopped. However, if a reactivation occurs, they have to be initiated on continuation treatment followed by hematopoietic stem cell transplant (HSCT). Those patients with familial HLH and those with persistent disease (even if nongenetic) would receive continuation treatment followed by HSCT^[9].

Table 5 Drugs used in Treatment of HLH & MAS.

| Drug | Dose |
|-----------------------------------|--|
| First choice-treatment | |
| Methylprednisolone (IV) | 30 mg/kg/ day (for 3-5 days) followed by 2-3 mg/kg/ d in 4 divided doses |
| Oral Prednisolone | 1mg/kg/ day |
| Cyclosporine A | 2-7 mg/kg/ day IV followed by 2-5 mg/kg/ d oral |
| Other treatment strategies | |
| High-dose IV immunoglobulin | 400 mg/kg/ day (for 5 days) |
| Antithymocyte globulin | 10 mg/kg/ day (for 5 days) |
| Etanercept | 0.4 mg/kg/ dose (twice weekly) $\times 4$ weeks |
| Anakinra | 2mg/kg/ d s/c (maximum 100 mg/ d) |
| Etoposide | 150mg/m ² per dose |

HLH-94 PROTOCOL



- Etoposide -150mg/m² per dose
- Intrathecal methotrexate and hydrocortisone (ITMTX/HC) should be given to patients with evidence of CNS involvement
1year- 6/8mg(MTX/HC) ;1-2years-8/10mg ; 2-3years-10/12mg;
3years-12/15mg.
- Weekly intrathecal therapy is generally continued until atleast 1week after resolution of CNS involvement (both clinical and CSF indices)

Figure 1 Induction therapy for HLH based on the HLH-94 study.

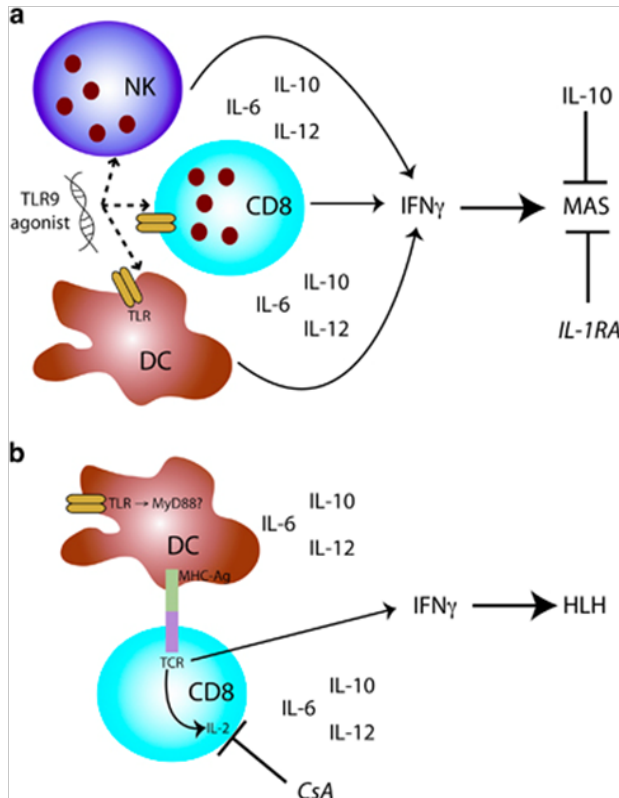


Figure 2 Mechanism of HLH and Action of Cyclosporine in HLH. Adapted from: A Ravelli, A A Grom, E M Behrens and R Q Cron. Macrophage activation syndrome as part of systemic juvenile idiopathic arthritis: diagnosis, genetics, pathophysiology and treatment. *Genes and Immunity* (2012) 13, 289–298

HLH-2004 protocol

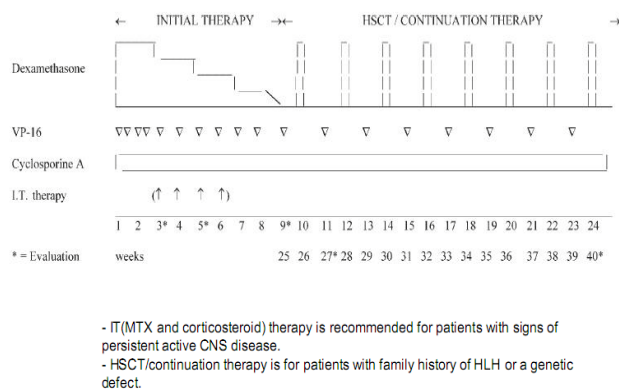


Figure 3 Treatment of HLH based on HLH 2004 protocol.

Familial HLH

Patients with familial HLH have high chance of recurrence and long term survival is not possible without hematopoietic stem cell transplant^[11,12]. All primary HLH patients treated with stem cell transplant after myeloablative conditioning are likely to have survival of 70% with family donor stem cell transplant and 50 % with haploidentical transplant^[1]. Alternative immunosuppressive drugs used are antithymocyte globulin (ATG) and intravenous gamma globulin (IV Ig). Supportive care with antibiotics, antifungals and antiviral agents may be needed^[9].

All patients of HLH need not be started on full protocol.

Corticosteroids alone may be tried for the initial treatment of secondary HLH, with the intention to proceed to the full protocol if there is no resolution within first 48 hours or if there is rapid progression^[11,12]. Macrophage activation syndrome, HLH associated with systemic onset juvenile idiopathic arthritis (SoJIA), may be treated with corticosteroid monotherapy or in combination with cyclosporine. Other agents used are anakinra, etanercept, IV Ig etc. Therapy may be stopped on complete resolution of clinical and laboratory findings.

CONCLUSION

HLH is a rare and underdiagnosed disease. High mortality in the absence of timely treatment makes an early diagnosis mandatory. The disease is a big masquerader, hence high index of suspicion has to be maintained to recognize the situation early. Because of the low specificity of the diagnostic criteria, the significance of newer molecular markers like sCD25, sCD163, CD107a and genetic testing is great. Mortality has improved significantly over the past few decades due to the institution of chemo-immunotherapy and stem cell transplant. Trials are underway which include the hybrid immunotherapy with ATG and etoposide; and these are likely to improve the treatment outcomes in future.

CONFLICT OF INTERESTS

The authors have no conflicts of interest to declare.

REFERENCES

- Weitzman S. Approach to Hemophagocytic Syndromes. *ASH Education Book* 2011; (1): 178-183
- Farquhar JW, Claireaux AE. Familial haemophagocytic reticulosis. *Arch Dis Child* 1952; **1**(27): 519-525
- Stepp SE, Dufourcq-Lagelouse R, Le Deist F, Bhawan S, Certain S, Mathew PA et al. Perforin gene defects in familial hemophagocytic lymphohistiocytosis. *Science* 1999; **286**: 1957-1959
- Flavia GN, Rosado MD, Kim AS. Hemophagocytic Lymphohistiocytosis. An Update on Diagnosis and Pathogenesis. *American Journal of Clinical Pathology* 2013; **139**: 713-727
- Usmani GN, Woda BA, Newburger PE. Advances in understanding the pathogenesis of HLH. *Br J Hematol*. 2013; **161**: 609-622
- Maciejewski J, Sella C, Anderson S, Young NS. Fas antigen expression on CD34+ human marrow cells is induced by interferon gamma and tumor necrosis factor alpha and potentiates cytokine-mediated hematopoietic suppression *in vitro*. *Blood*. 1995; **85**: 3183-3190
- Kuriyama Katsuto T, Takenaka, Kohno K, Yamauchi T, Daitoku IS. Engulfment of hematopoietic stem cells caused by down-regulation of CD47 is critical in the pathogenesis of hemophagocytic lymphohistiocytosis. *Blood* 2012; **120**: 4058-4067
- Jordan MB, Allen CE, Weitzman S, Filipovich AH, McClain KL. How I treat hemophagocytic lymphohistiocytosis. *Blood* 2011; **118**: 4041-4052.
- Gupta A, Tyrrell P, Valani R, Benseler S, Weitzman S, Abdelhalim M. The role of the initial bone marrow aspirate in the diagnosis of hemophagocytic lymphohistiocytosis. *Pediatric Blood & Cancer* 2008; **51**: 402-404
- Chen RL, Hsu YH, Ueda I, Imashuku S, Takeuchi K, Tu BP, Chuang SS. Cytophagic histiocytic panniculitis with fatal hemophagocytic lymphohistiocytosis in a paediatric patient with perforin gene mutation. *Journal of Clinical Pathology* 2007; **60**: 1168-1169.
- Hendricks M, Pillay S, Davidson A, De Decker R, Lawrenson J. Kawasaki disease preceding haemophagocytic lymphohistiocytosis.

- sis: challenges for developing world practitioners. *Pediatric Blood & Cancer* 2010; **54**: 1023-1025.
- 12 Henter JI, Horne A, Arico M, Egeler RM, Filipovich AH, Imashuku S et al. HLH-2004: diagnostic and therapeutic guidelines for hemophagocytic lymphohistiocytosis. *Pediatr Blood Cancer* 2007; **48**: 124-131
- 13 A Ravelli, A A Grom, E M Behrens, R Q Cron. Macrophage activation syndrome as part of systemic juvenile idiopathic arthritis: diagnosis, genetics, pathophysiology and treatment. *Genes and Immunity* 2012; **13**: 289-298
- 14 Jan-Inge Henter, AnnaCarin Samuelsson-Horne, Maurizio Arico`, R. Maarten Egeler, Go`ran Elinder, Alexandra H. Filipovich. Treatment of hemophagocytic lymphohistiocytosis with HLH-94 immunochemotherapy and bone marrow transplantation. *Blood* 2002; **100**: 2367-2373

Peer reviewer: Nasim Valizadeh, Department of Hematology/ Medical Oncology, Shariati Hospital, Kargar Avenue, Tehran, Iran.