

Is there a Histopathologic Correlation of Prostatic PI-RADS Score 3 Lesions in Transition Zone in MRI with the Dynamic Contrast Curve Type? A Retrospective Single-center Study

Sigmund Stuppner, Antonio Ruiu

Sigmund Stuppner, Antonio Ruiu, Department of Diagnostic and Interventional Radiology of the Bolzano Hospital, Italy

Conflict-of-interest statement: The author(s) declare(s) that there is no conflict of interest regarding the publication of this paper.

Open-Access: This article is an open-access article which was selected by an in-house editor and fully peer-reviewed by external reviewers. It is distributed in accordance with the Creative Commons Attribution Non Commercial (CC BY-NC 4.0) license, which permits others to distribute, remix, adapt, build upon this work non-commercially, and license their derivative works on different terms, provided the original work is properly cited and the use is non-commercial. See: <http://creativecommons.org/licenses/by-nc/4.0/>

Correspondence to: Sigmund Stuppner, Department of Diagnostic and Interventional Radiology of the Bolzano Hospital, Italy
Email: stuppnersigmund@web.de
Telephone: +00390471-908494

Received: February 26, 2019
Revised: April 7, 2018
Accepted: April 10, 2018
Published online: May 19, 2019

ABSTRACT

OBJECTIVES: To evaluate the correlation of classified PI-RADS score 3 lesions in TZ with dynamic enhancement in multiparametric-prostatic MRI.

METHODS: We reviewed retrospectively 24 patients over a period of two years. Contrast curve types of prostatic PI-RADS 3 lesions in the TZ were elaborated with a dedicated MRI-software. Histopathologic results after prostatic biopsies were evaluated to determine, if there is a correlation with any curve type after endovenous contrast medium.

RESULTS: We found no significant statistical correlation between the curve type and the histopathological results in the transition zone of the prostate.

CONCLUSIONS: Contrast enhancement evaluation to determine specific curve types in focal prostatic PI-RADS 3 lesions in the

transition zone has no diagnostic value

Key Points: (1) Transition Zone (TZ)- prostatic cancer is more difficult to detect with trans-rectal biopsy than prostatic cancer in the PZ. (2) Dynamic contrast enhanced perfusion-MRI does not improve the localization and characterization of prostatic PI-RADS 3 lesions in the TZ

Key words: Prostate; Perfusion; Biopsy

© 2019 The Author(s). Published by ACT Publishing Group Ltd. All rights reserved.

Stuppner S, Ruiu A. Is there a Histopathologic Correlation of Prostatic PI-RADS Score 3 Lesions in Transition Zone in MRI with the Dynamic Contrast Curve Type? A Retrospective Single-center Study. *International Journal of Radiology* 2019; 6(1): 217-220 Available from: URL: <http://www.ghrnet.org/index.php/ijr/article/view/2351>

Abbreviations

TZ: Transition zone
PZ: Peripheric zone
PI RADS: Prostate Imaging Reporting and Data System
PSA: Prostate-specific antigen (PSA)
DCEP-MRI: Dynamic Contrast-Enhanced Perfusion MRI
mp-MRI: multiplanar-MRI
EWS: Extended Workstation (EWS)
PZpm: Peripheric zone postero-medial
ROI: Region of interest
BPH: Benign prostatic hyperplasia

INTRODUCTION

Prostate cancer is the most frequent cancer type in males, but only about 20-30% of prostatic cancer originate in the TZ. The diagnosis is based on the prostate-specific antigen (PSA) screening in males over 40 years and transrectal ultrasound (TRUS)-guided prostate biopsy. Prostate multiparametric MRI is indicated in patients with increasing PSA values (over 2.5-3 ng/mL) and negative prostate biopsies and in patients with suspected trans-rectal palpation results. Multiparametric-magnetic resonance imaging (mp-MRI) is indicated

in localization and staging of clinically significant prostate cancer. Today every prostatic mp-MRI is performed with contrast agent, to assess the dynamic contrast perfusion (Dynamic Contrast-Enhanced Perfusion MRI) of prostatic tissue. In 2015, with the support of the American College of Radiology, was developed the PI-RADS Version 2. The goal was to promote global standardization and to reduce variability in reporting Prostatic MRI^[1]. DCEP MRI can be useful in combination with T2 Sequences and DWI-Imaging in the characterization of focal prostatic lesions in the peripheral (PZ) and in the transition zone (TZ). Furthermore, enhancement alone is not definitive for clinically significant prostate cancer, and absence of early enhancement does not exclude the possibility^[2].

The transition zone (TZ)

The TZ surrounds the part of the prostatic urethra, that passes through the prostate. This zone gets bigger with increasing age, a condition called benign prostatic hyperplasia (BPH). TZ prostate cancers have a relatively lower Gleason score^[3], local stage^[4] and biochemical recurrence rate^[5] in comparison with peripheral zone cancers prostate cancer. Transition zone (TZ) tumors are estimated to account for approximately 30% of prostate cancer cases and pose a clinical challenge because of the difficulty of their detection^[6,7].

MATERIAL AND METHODS

This single center retrospective study was performed from two radiologists with an experience over 10 years. There wasn't a conflict of interest anytime. We conducted a systematic review to identify patients with typical PI-RADS 3 lesions in the TZ.

All patients presented a previous negative transrectal ultrasound (TRUS) guided prostate biopsy and were sent by urologists after performing PSA blood test and negative transrectal examination. Median age of all patient was 65 and the median PSA level was 8 ng/ml. Exclusion criteria of our study were patients with active surveillance biopsies, a bad compliance with consecutive motion artifacts and patients with first biopsies.

We retrospectively found 24 patients with clear radiological diagnosed PI-RADS 3 lesions in the TZ. MRI examinations were performed all on the same MRI scanner manufactured by Philips at a field strength of 1.5 Tesla using a standardized MRI protocol that included T2-weighted imaging in axial, sagittal and coronal axis (TR: 3000-4761.01; TE: 120; slice thickness: 3-3.5 mm; Percent Phase Field of View of 100; Acquisition Matrix: 216 × 175), an axial T1- weighted imaging (TR: 427.59; TE: 10; slice thickness: 5 mm; Percent Phase Field of View of 90.48; Acquisition Matrix: 300 × 293), axial DWI sequences (single-shot spin-echo EPI sequences with b-values from 0-2.000 s/mm²; TR: 3000 ms; TE: 94.62 ms; slice thickness: 3,5 mm; Percent Phase Field of View of 88.89; Acquisition Matrix: 68 × 67) and a axial DCE-MRI sequences (TR: 3.89; TE: 1.82; slice thickness: 4 mm; Percent Phase Field of View of 90,29; Acquisition Matrix: 176 × 174, 30-40 phases) after a bolus of Gd-DTPA (Gadovist, Bayer AG) at a constant dose of 0.1 mmol/kg and a rate of 2 ml/s for all patients. After the exam all sequences were sent to the Med Station (Extended MR Workstation (EWS)).

To evaluate a specific curve type (0 = non-diagnostic curve, 1= curve type 1, 2 = curve type, 2 and 3 = curve type 3), we positioned an oval ROI over every suspected T2 lesion in the TZ with signs of DWI-restriction signs.

Statistical analysis

Data was analyzed using R-Studio version 3.3.2. P values <0.05 were considered statistically significant.

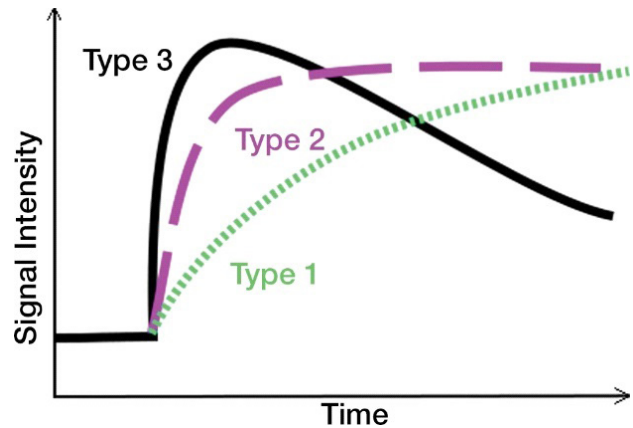


Figure 1 Curve types [1].

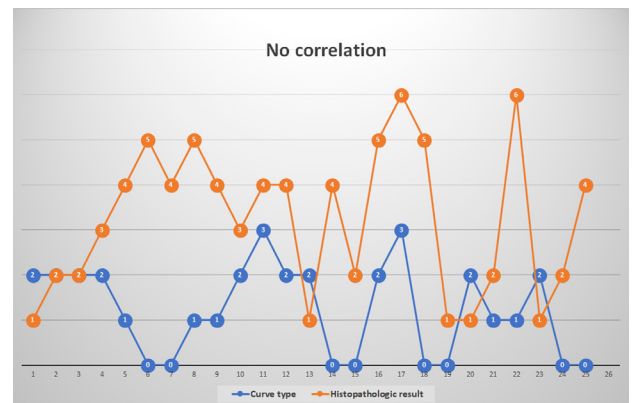


Figure 2 The orange numbers represent the different histopathologic results and the blue numbers the different curve types.

RESULTS

All 24 patients with confirmed radiological PI-RADS 3 lesions in the prostatic transition zone are presented in Table 1. We correlated the histopathological results with specific numbers (Table 2), to calculate the Pearson's product-moment correlation between curve types and histopathological results with a value of R correlation of - 0.0787, and a p-value of 0.7148 (Table 3). Although technically a negative correlation, the relationship between our variables was only weak (the nearer the value is to zero, the weaker the relationship). In our retrospective study the size of the suspected T2 lesions in the TZ wasn't considered. We found 9 patients with curve type 0 (37.5%), 4 patients with curve type 1 (16.6%), 10 patients with curve type 2 (41.6%) and 2 patients with curve type 3 (8.3%). Forms of chronic prostatitis were the most histological result (18 patients - 75%).

Clinical significant adenocarcinoma was found in only 4 patients (16,6%).

DISCUSSION

Prostatic lesions located in the transition zone are detected first with T2w sequences, the dominant sequences in PI-RADS v2 [8]. Signal intensity in a lesion should be visually compared to the average signal of "normal" transition zone. PI-RADS 3 lesions are characterized as heterogeneous signal intensity with obscured margins (and include characteristics that do not qualify as PI-RADS 2, 4, or 5), together with focal mildly to moderately hypointense on ADC, and isointense to mildly hyperintense on high b-value DWI. The interpretation of the transition zone is considered to provide a greater challenge than the peripheral zone. While a normal peripheral

Table 1 Location, curve types and histopathologic results

Patient	Location	Curve type	Histopathologic result
A	TZ left midgland	rapid increasing curve with continuous enhancement - type 2	chronic atrophic prostatitis
B	TZ anterior/posterior basal	rapid increasing curve with continuous enhancement -type 2	chronic prostatitis
C	TZ anterior basal right	rapid increasing curve with continuous enhancement -type 2	chronic prostatitis
D	TZ left apical	rapid increasing curve with continuous enhancement -type 2	secretory stasis and aspecific moderate chronic prostatitis
E	TZ right apical	slowly increasing curve with continuous enhancement- type 1 curve	focal riactized chronic prostatitis
F	TZ right anterior apical	nondiagnostic curve	adenocarcinoma Gleason Score 6 (3+3) - pT2c G1
G	TZ anterior mid left	nondiagnostic curve	focal riactized chronic prostatitis
H	TZ anterolateral basal left	slowly increasing curve with continuous enhancement- type 1 curve	adenocarcinoma Gleason Score 7 (3+4) - pT2 G2
I	TZ anterior basal right	slowly increasing curve with continuous enhancement- type 1 curve	focal riactized chronic prostatitis
J	TZ anterior right basal	rapid increasing curve with continuous enhancement -type 2	secretory stasis and microlithiasis
K	TZ left mid gland	rapid increasing curve with slowly wash out-type 3	focal riactized chronic prostatitis
L	TZ apical pl left	rapid increasing curve with continuous enhancement -type 2	focal riactized chronic prostatitis
M	TZ apical pl right	rapid increasing curve with continuous enhancement - type 2	chronic atrophic prostatitis
N	TZ basal posterior right	nondiagnostic curve	focal riactized chronic prostatitis
O	TZ a basal right	nondiagnostic curve	focal chronic prostatitis
P	TZ anterior midgland right	rapid increasing curve with continuous enhancement - type 2	adenocarcinoma GS 6-7 (3+3/3+4)
Q	TZ anterolateral basal left	rapid increasing curve with slowly wash out-type 3	acute bacterial prostatitis
R	TZ apical anterior right	nondiagnostic curve	adenocarcinoma GS 6 (3+3)
S	TZ anterior basal right	nondiagnostic curve	chronic atrophic prostatitis
T	TZ anterior basal right	nondiagnostic curve	chronic atrophic prostatitis
U	TZ anterior midgland left	rapid increasing curve type with continous enhancement - type 2	focal chronic prostatitis
V	TZ apical anterior left	slowly increasing curve with continuous enhancement- type 1	acute bacterial prostatitis
W	TZ posterior midgland left	rapid increasing curve with continous enhancement- type 2	chronic atrophic prostatitis
X	TZ apical anterior right	nondiagnostic curve	focal chronic prostatitis
Y	TZ apical posterior right	nondiagnostic curve	focal riactized prostatitis

zone is brightly hyperintense on T2w images, and therefore hypointense abnormalities can be easily identified, the transition zone shows heterogeneous signal intensities related to the presence of nodules of benign prostatic hyperplasia, and therefore the identification of suspicious abnormalities can be more difficult^[9]. In our opinion radiologist tend sometimes to overestimate prostatic suspected lesions in the TZ, so a second opinion from another radiologist is indicated. We also reviewed the sizes of each T2-lesion in the TZ which we characterized as PI-RADS 3 lesions. The 4 lesions that resulted as prostatic carcinoma had a maximal axial diameter of 5 mm, 8 mm, 9 mm and 8 mm, considering, that our study has several limitations, like the small number, the single center study and the lack of interobserver reliability

To understand the contrast distribution in pathologic TZ tissue, we must analyze the microscopic architecture. A study from 2012 revealed that the microvasculature of transition zone tumor showed increased heterogeneity compared to benign prostatic hyperplasia and peripheral zone tumors, possibly explaining the difficulty of TZ tumor detection on DCEP-MRI. Comparing TZ tumor to normal TZ, a tendency towards an increase in the extend of the vascularity was observed in TZ tumors^[10]. There is a similar study from 2015^[11], analyzing the perfusion curve types from prostatic adenocarcinomas, but in the peripheric zone. To understand the micro-perfusion of chronic prostatitis in the TZ we must analyze the “prostatic microcosmos” The key histologic features of prostate carcinoma pertinent to MR imaging are increased cellular density, decreased luminal volume, reduced extracellular space, and neoangiogenesis^[11] A study from 2010 showed the histologic mimickers of prostatic adenocarcinoma, like atrophy, crowded benign glands, adenosis (atypical adenomatous hyperplasia), and basal cell hyperplasia, depending on the study and type of tissue sample. In a review of 535 consecutive needle biopsies, 7 (1.3%) were classified as false-positives. These 7 cases comprised 5 cases of adenosis (atypical adenomatous hyperplasia) and 2 cases of atrophy. A second investigation on needle core biopsy tissue found partial atrophy and crowded benign glands to be the most frequent benign mimickers of prostatic carcinoma^[12]. In prostatitis, a frequent finding in our study, an increased vessel leakiness can mimic a curve type 3 with rapid contrast extravasation and slowly “wash out”.

Table 2 Correlation between curve types and histopathological result.

Patient	Curve type	Histopathologic result
A	2	chronic atrophic prostatitis =1
B	2	chronic prostatitis = 2
C	2	chronic prostatitis = 2
D	2	secretory stasis and aspecific moderate chronic prostatitis = 3
E	1	focal riacutized chronic prostatitis= 4
F	0	adenocarcinoma Gleason Score 6 (3+3) - pT2c G1 = 5
G	0	focal riacutized chronic prostatitis = 4
H	1	adenocarcinoma Gleason Score 7 (3+4) - pT2 G2 = 5
I	1	focal riacutized chronic prostatitis = 4
J	2	secretory stasis and microlithiasis = 3
K	3	focal riacutized chronic prostatitis = 4
L	2	focal riacutized chronic prostatitis = 4
M	2	chronic atrophic prostatitis = 1
N	0	focal riacutized chronic prostatitis = 4
O	0	focal chronic prostatitis = 2
P	2	adenocarcinoma GS 6-7 (3+3/3+4) = 5
Q	3	acute bacterial prostatitis = 6
R	0	adenocarcinoma GS 6 (3+3) = 5
S	0	chronic atrophic prostatitis = 1
T	2	chronic atrophic prostatitis = 1
U	1	focal chronic prostatitis = 2
V	1	acute bacterial prostatitis = 6
W	2	chronic atrophic prostatitis = 1
X	0	focal chronic prostatitis = 2
Y	0	focal riacutized prostatitis = 4

Curve type 0 = non-diagnostic curve.

The problematic of prostatic tissue characterization, in particular of the TZ, is the post biopsy microarchitecture transformation of prostatic tissue, although a study from 2017 concluded that a biopsy-induced hemorrhage in the prostate gland is not absorbed sufficiently over time and the extent of hemorrhage and the short interval between biopsy and MRI may not impair tumor detection or staging on multiparametric MRI^[13]. In our opinion another fact to consider is the post-biopsy focal fibrosis formation in the TZ, a factor that can cause alteration of prostatic perfusion and of the curve types In conclusion, we suggest, that radiologists should overthink contrast administration in non-suspected PI-RADS 4 or 5 lesions after visualizing T2 and diffusion weighted images.

REFERENCES

- Hansford BG, Peng Y, Jiang Y, Vannier MW, Antic T, Thomas S, McCann S, Oto A. Dynamic Contrast-enhanced MR Imaging Curve-type Analysis: Is It Helpful in the Differentiation of Prostate Cancer from Healthy Peripheral Zone? *Radiology*. 2015 May;**275**(2): 448-57. [DOI: 10.1148/radiol.14140847]. Epub 2015 Jan 5.
- PI-RADS™ Prostate Imaging – Reporting and Data System 2015 version 2
- Augustin H, Erbersdobler A, Hammerer PG, Graefen M, Huland H. Prostate cancers in the transition zone: Part 2; clinical aspects.

Table 3 Result Details & Calculation.

X Values $\sum = 30$ Mean = 1.25
$\sum (X - Mx)^2 = SSx = 24.5$
Y Values $\sum = 80$ Mean = 3.333
$\sum (Y - My)^2 = SSy = 59.333$
X and Y Combined
$N = 24 \sum (X - Mx) (Y - My) = -3$
R Calculation
$r = \sum ((X - Mx) (Y - My)) / \sqrt{(SSx)(SSy)}$
$r = -3 / \sqrt{(24.5) (59.333)} = -0.0787$
Meta Numerics (cross-check)
$r = -0.0787$

X: X Values; Y: Y Values; Mx: Mean of X Values; My: Mean of Y Values; X - Mx & Y - My: Deviation scores; (X - Mx)² & (Y - My)²: Deviation Squared; (X - Mx) (Y - My): Product of Deviation Scores.

BJU Int. 2004 Dec;**94**(9): 1226-9. PMID: 15610094]; [DOI: 10.1111/j.1464-410X.2004.05147.x]

- Greene DR1, Wheeler TM, Egawa S, Weaver RP, Scardino PT. Relationship between clinical stage and histological zone of origin in early prostate cancer: morphometric analysis. *Br J Urol*. 1991 Nov;**68**(5): 499-509. [PMID: 1747726]
- King CR1, Ferrari M, Brooks JD. Prognostic significance of prostate cancer originating from the transition zone. *Urol Oncol*. 2009 Nov-Dec;**27**(6): 592-7. [DOI: 10.1016/j.urolonc.2008.05.009]. Epub 2008 Sep 16.
- Haas GP1, Sakr WA. Epidemiology of prostate cancer. *CA Cancer J Clin*. 1997 Sep-Oct;**47**(5): 273-87. [PMID: 9314822]
- Akin O1, Sala E, Moskowitz CS, Kuroiwa K, Ishill NM, Pucar D, Scardino PT, Hricak H. Transition zone prostate cancers: features, detection, localization, and staging at endorectal MR imaging. *Radiology*. 2006 Jun;**239**(3): 784-92. Epub 2006 Mar 28. [PMID: 16569788]; [DOI: 10.1148/radiol.2392050949]
- Barentsz JO1, Richenberg J, Clements R, Choyke P, Verma S, Villeirs G, Rouviere O, Logager V, Fütterer JJ; European Society of Urogenital Radiology. ESUR prostate MR guidelines 2012. *Eur Radiol*. 2012 Apr;**22**(4): 746-57. [DOI: 10.1007/s00330-011-2377-y]. Epub 2012 Feb 10.
- Schoots IG. MRI in early prostate cancer detection: how to manage indeterminate or equivocal PI-RADS 3 lesions? *Transl Androl Urol*. 2018 Feb;**7**(1): 70-82. [DOI: 10.21037/tau.2017.12.31]
- van Niekerk CG1, Witjes JA, Barentsz JO, van der Laak JA, Hulsbergen-van de Kaa CA. Microvasculature in transition zone prostate tumors resembles normal prostatic tissue. *Prostate*. 2013 Apr;**73**(5): 467-75. [DOI: 10.1002/pros.22588]. Epub 2012 Sep 19.
- Kitzing YX, Prando A, Varol C, Karczmar GS, Maclean F, Oto A. Benign Conditions That Mimic Prostate Carcinoma: MR Imaging Features with Histopathologic Correlation. *Radiographics*. 2016 Jan-Feb;**36**(1): 162-75. [DOI: 10.1148/rg.2016150030]. Epub 2015 Nov 20.
- Hameed O, Humphrey PA. Pseudoneoplastic mimics of prostate and bladder carcinomas. *Arch Pathol Lab Med*. 2010 Mar;**134**(3): 427-43. [DOI: 10.1043/1543-2165-134.3.427]
- Moan-Hyung Choi, Seung Eun Jung, Yong Hyun Park, Ji Youl Lee Yeong-Jin Choi. Multiparametric MRI of Prostate Cancer after Biopsy: Little Impact of Hemorrhage on Tumor Staging. *iMRI* 2017; **21**: 139-147. [DOI: 10.13104/imri.2017.21.3.139]