

CASE REPORT

Cavernous Hemangioma Based on Posterior Fossa Dura

Yasushi Shibata, MD, PhD, Ryota Mashiko, MD, PhD, Norio Takayashiki, MD, PhD

Yasushi Shibata, Ryota Mashiko, Department of Neurosurgery, Mito Medical Center, Mito Kyodo General Hospital, University of Tsukuba, Miyamachi 3-2-7, Mito, Ibaraki 3100015, Japan
Norio Takayashiki, Department of Pathology, Mito Medical Center, Mito Kyodo General Hospital, University of Tsukuba, Miyamachi 3-2-7, Mito, Ibaraki 3100015, Japan

Conflict-of-interest statement: The author(s) declare(s) that there is no conflict of interest regarding the publication of this paper.

Open-Access: This article is an open-access article which was selected by an in-house editor and fully peer-reviewed by external reviewers. It is distributed in accordance with the Creative Commons Attribution Non Commercial (CC BY-NC 4.0) license, which permits others to distribute, remix, adapt, build upon this work non-commercially, and license their derivative works on different terms, provided the original work is properly cited and the use is non-commercial. See: <http://creativecommons.org/licenses/by-nc/4.0/>

Correspondence to: Yasushi Shibata, Department of Neurosurgery, Mito Medical Center, Mito Kyodo General Hospital, University of Tsukuba, Miyamachi 3-2-7, Mito, Ibaraki 3100015, Japan.
Email: yshibata@md.tsukuba.ac.jp
Telephone: +81-29231-2371
Fax: +81-29221-5137

Received: February 2, 2018

Revised: April 7, 2017

Accepted: April 9, 2018

Published online: April 28, 2018

ABSTRACT

There are 2 types of intracranial cavernous hemangioma, namely cerebral cavernous malformation and dural cavernous hemangioma. Most dural cavernous hemangiomas are located in the middle cranial fossa. We experienced a rare case of cavernous hemangioma located on the posterior fossa dura, which mimicked meningioma.

Key words: Cavernous hemangioma; Posterior fossa; Dura

© 2018 The Author(s). Published by ACT Publishing Group Ltd. All rights reserved.

Shibata Y, Mashiko R, Takayashiki N. Cavernous Hemangioma Based on Posterior Fossa Dura. *International Journal of Radiology* 2018; 5(1): 161-162 Available from: URL: <http://www.ghrnet.org/index.php/ijr/article/view/2267>

INTRODUCTION

There are 2 types of intracranial cavernous hemangioma, namely cerebral cavernous malformation and dural cavernous hemangioma. Most dural cavernous hemangiomas are located in the middle cranial fossa. We experienced a rare case of cavernous hemangioma located on the posterior fossa dura, which mimicked meningioma.

CASE REPORT

A 56-year-old man was referred to our department after a brain tumor was incidentally found by MRI. He reported that he occasionally suffered mild headaches. A neurological examination showed no abnormalities. MRI revealed a solid enhanced tumor in the left posterior fossa attached to the dura (Figure 1). Although cerebral angiography showed no clear tumor staining, the patient was preoperatively diagnosed with meningioma. The tumor was resected. The tumor was reddish in color and bled easily. The tumor which was attached to the lateral sinus was carefully dissected. The tumor was totally removed and the attachment was coagulated. Pathologically, the tumor consisted of spindle cells (Figure 2). An immunostaining was negative for bcl2, EMA, S100, CD34, and CD99, thus he was diagnosed with cavernous hemangioma. The post-surgical course was uneventful. No recurrence has been observed thus far.

DISCUSSION

Reports of dural cavernous hemangiomas outside the middle cranial fossa are rare. Lewis summarized 18 cases of dural cavernous angiomas outside the middle cranial fossa, including 2 cases that they encountered in 1994^[1]. Among these 18 cases, 6 cases were located at the tentorium and only 1 case was located in the posterior fossa. Our search of the literature revealed 3 additional cases of dural cavernous hemangioma in the posterior fossa that were not included in Lewis's summary^[2-4]. Two cases of cavernous hemangioma attached to the cerebellar falx were reported in 2009 and 2010^[5,6]. Thus, a total 6 cases of cavernous hemangioma originating from the posterior fossa dura have been reported to date. The radiological and surgical findings of dural cavernous hemangioma mimic those of meningioma.

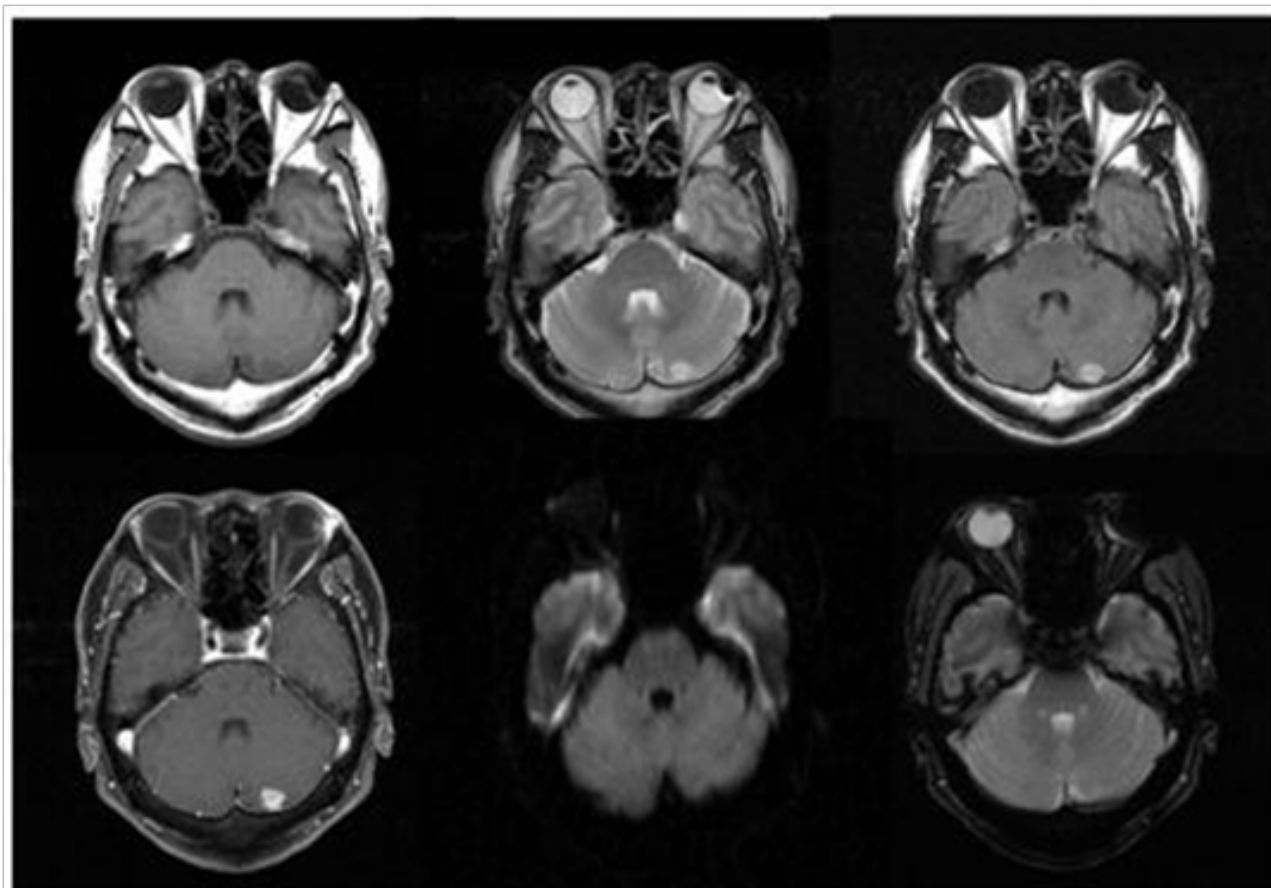


Figure 1 MR images before surgery (T1, T2, FLAIR, Gd-T1, DWI, T2*).

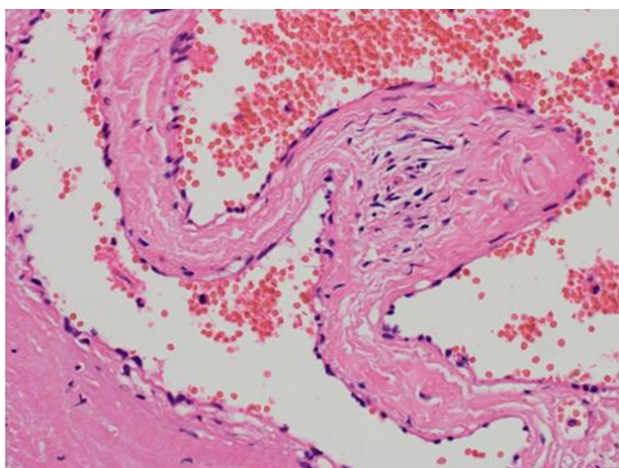


Figure 2 Pathological findings of surgical specimen (Hematoxylin-Eosin staining).

REFERENCES

1. Lewis AI, Tew JM, Jr., Payner TD, Yeh HS. Dural cavernous angiomas outside the middle cranial fossa: a report of two cases. *Neurosurgery*. 1994; **35**: 498-504
2. Goel A, Achwal S, Nagpal RD. Dural cavernous haemangioma of posterior cranial fossa. *J Postgrad Med*. 1993; **39**: 222-3.
3. Sundaresan N, Eller T, Ciric I. Hemangiomas of the internal auditory canal. *Surg Neurol*. 1976; **6**: 119-21.
4. Boockvar JA, Stiefel M, Malhotra N, Dolinskas C, Dwyer-Joyce C, LeRoux PD. Dural cavernous angioma of the posterior sagittal sinus: case report. *Surgical Neurology*. 2005; **63**: 178-81.
5. Ito M, Kamiyama H, Nakamura T, Nakajima H, Tokugawa J. Dural cavernous hemangioma of the cerebellar falx. *Neurol Med Chir (Tokyo)*. 2009; **49**: 410-2.
6. Melone AG, Delfinis CP, Passacantilli E, Lenzi J, Santoro A. Intracranial Extra-axial Cavernous Angioma of the Cerebellar Falx. *World Neurosurgery*. 2010; **74**: 501-4.