

Contribution of Computed Tomography in the Detecting of Headache Origin in Adults in Sub-Saharan Africa

Kouamé N'goran, Nikiema Zakari, Gaimou Blé P, Boubé A, Manewa Fotso Sorel, N'Goan Domoua-Anne-Marie, N'gbesso Roger Daniel

Kouamé N'goran, Gaimou Blé P, Boubé A, Manewa Fotso Sorel, N'Goan Domoua-Anne-Marie, N'gbesso Roger Daniel, Department of Radiology, University Hospital of Yopougon, Abidjan 21 BP 632 21, Cote d'Ivoire

Nikiema Zakari, Department of Radiology, Sourou Sanou University Hospital, 01 BP 676 Bobo-Dioulasso, Burkina Faso

Correspondence to: Kouamé N'Goran, Senior Lecturer, Department of Radiology University Hospital of Yopougon. 21 BP 632 Abidjan 21, Cote d'Ivoire

Email: kngoran@yahoo.fr

Telephone: +225 09475730

Received: November 21, 2015 Revised: December 20, 2015

Accepted: December 29, 2015

Published online: March 7, 2016

ABSTRACT

OBJECTIVE: To determine the etiology of headache in sub-Saharan Africa.

PATIENTS AND METHODS: a prospective study of six months duration carried out at the military hospital of Abidjan. It included all patients who underwent a brain CT for headache. The CT scans were performed in spontaneous contrast, supplemented according to the context by another complementary acquisition after injection of iodinated contrast medium. The epidemiological and clinical data were obtained from the patients' examination interview.

RESULTS: The total number of our patients was 129. There was a predominance with 52% ($n = 67$) of women against 48% men ($n = 62$). The average age was 44 years. The associated clinical symptoms were: motor deficit (30.2%) and fever (11%). In 58.8% of cases there were no associated signs. In 17 cases there was a notion of combined hormonal taking, 20 cases of hypertension and 10 cases of trauma. CT revealed in 46.2% of cases a cause for headache. These etiologies were dominated by stroke (24%), followed by sinusitis (9.3%), abscesses and encephalitis (7.8%) and trauma (5.4%).

CONCLUSION: In sub-Saharan Africa headache is frequently explored in neuroradiology. This is a serious symptom for which CT revealed in 46.2% of cases an underlying cause dominated by decreasing order of frequency: stroke, sinusitis and brain abscess.

© 2016 ACT. All rights reserved.

Key words: Brain CT scan; Headache; Sub-Saharan Africa

Kouamé N, Nikiema Z, Blé Gaimou P, A Boubé, Manewa FS, N'Goan-Domoua AM, N'gbesso RD. Contribution of Computed Tomography in the Detecting of Headache Origin in Adults in Sub-Saharan Africa. *International Journal of Radiology* 2015; 3(1): 102-105 Available from: URL: <http://www.ghrnet.org/index.php/ijr/article/view/1486>

INTRODUCTION

Headache is a common reason for consultation in primary care medicine and emergency departments^[1]. In the United States, it accounts for about 1-3% of consultations in the emergency units, that is approximately one million patients per year^[2-3]. There are two types of headache: primary headache that does not show detectable organic substrate particularly in imaging and symptomatic or secondary headache attributed to an organic disease particularly neurological, requiring assessment^[4].

Although in most cases no further investigation is necessary, the anamnesis of the physical examination may suggest in some cases a secondary cause, thus requiring brain imaging. The choice of imaging method will then depend on the degree of emergency and clinical suspicion. Brain CT is the examination of choice in an emergency case, with or without contrast medium injection according to the suspected disease, while MRI, more sensitive, is especially useful in the ambulatory examination of intracranial tumor or infectious pathologies^[1]. Given the unavailability of MRI in sub-Saharan Africa,

we carried out this study focusing on CT scanning and investigating of headache symptoms in order to show the role of CT in the management of headache and determine etiologies of headache in sub-Saharan Africa.

PATIENTS AND METHODS

This is a descriptive prospective study carried out over a period of six months (October 1, 2014 to March 31, 2015) at the Military Hospital of Abidjan. It focused on all patients who underwent a head CT scan for headache.

The scanning was performed using a brand HITACHI ECLOS 16 slices CT scanner. All patients underwent helical acquisition without contrast medium injection. According to the context (notion of fever or combined hormonal taking or suspect image on the spontaneous contrast acquisition), another complementary acquisition was performed after iodinated contrast medium IV (IntraVenus) injection. Epidemiological and clinical data were obtained through the interview of patients with a survey sheet. The parameters studied were age, gender, traumatic history or not, notion of combined hormonal taking or not, accompanying signs of headache, CT protocol and CT image findings.

RESULTS

The total number of patients was 129. There was a predominance with 52% (*n* = 67) of women against 48% men (*n* = 62). The average age was 44 years, with extremes ranging from 17 to 80 years and a predominance of the age group between 40 and 49 years. The associated signs were motor deficit (39 cases that is 30.2%) and fever (14 cases that is 11%). In 58.8% of cases there were no associated clinical symptoms. In 17 cases (25.4%), there was a notion of combined hormonal taking, 20 cases of hypertension and 10 cases of trauma. In 79 cases (61.2%), an acquisition after iodinated contrast medium injection was performed. In 53, 8% (*n* = 69) of cases CT findings were normal (Table 1). CT revealed in 46.2% (*n* = 60) of cases a cause for headache. These causes were dominated by stroke (24%), followed by sinusitis (9.3%), abscesses and encephalitis (7.8%) and trauma (5.4%). Strokes were ischemic in 25 cases, hemorrhagic in 5 cases and venous in 1 case (thrombophlebitis).

DISCUSSION

In our investigated group women were more affected by headache than men with a sex ratio of 0.92. Thus 67 patients (53%) were females and 62 patients (47%) males. The female preponderance of headache observed in our study is in agreement with the literature data. In a retrospective study of 100 records of patients admitted to a medical emergency department in the United States, 74% of patients

Table 1 Distribution of patients according to the result of the scanner.

CT findings	Frequency	Percentage (%)
Pathological	60	46.2
Vascular	31	24
Ischemic stroke	25	19.4
Hemorrhagic stroke	5	3.9
Thrombophlebitis	1	0.8
ENT (sinusitis)	12	9.3
Infectious	10	7.8
Abscess	7	5.4
Encephalitis	3	2.3
Trauma	7	5.4
Normal	69	53.8
Total	129	100

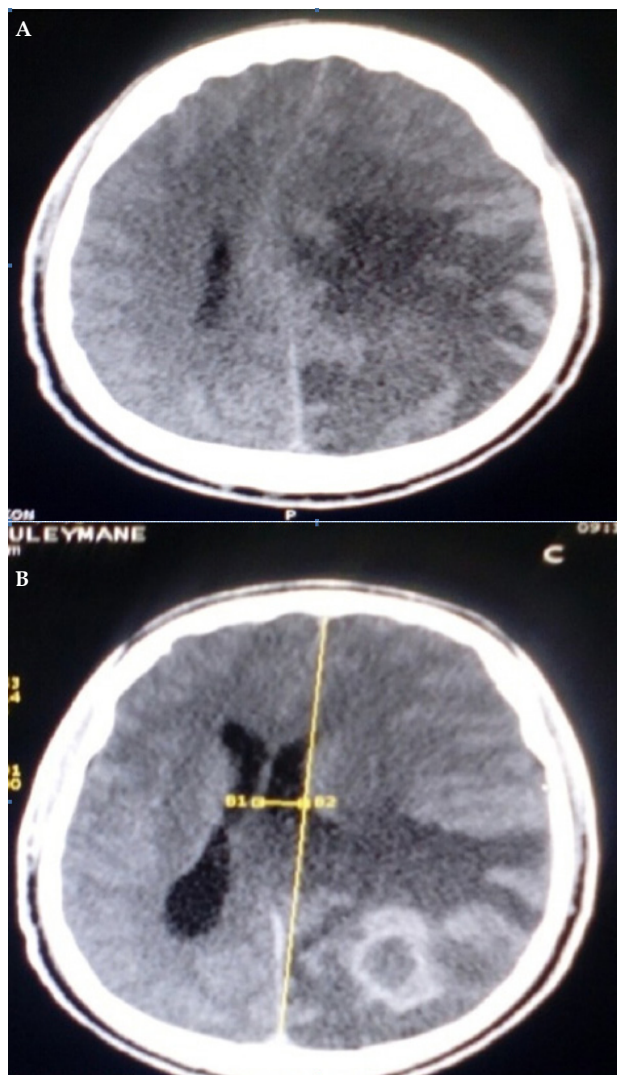


Figure 1 Patient aged 27 years, headache and fever. Brain scanner in axial sections without (A) and with injection of iodinated contrast medium (B). Brain abscess.

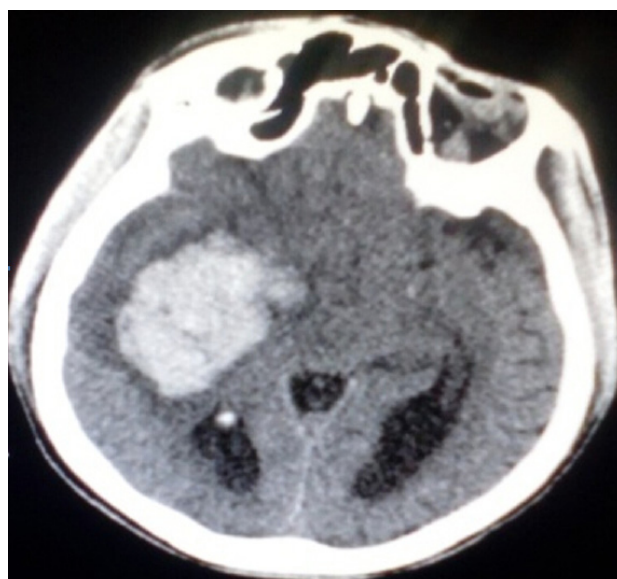


Figure 2 Patient aged 43 years, headache and hypertension. Brain scanner in axial section without injection. Hemorrhagic stroke.

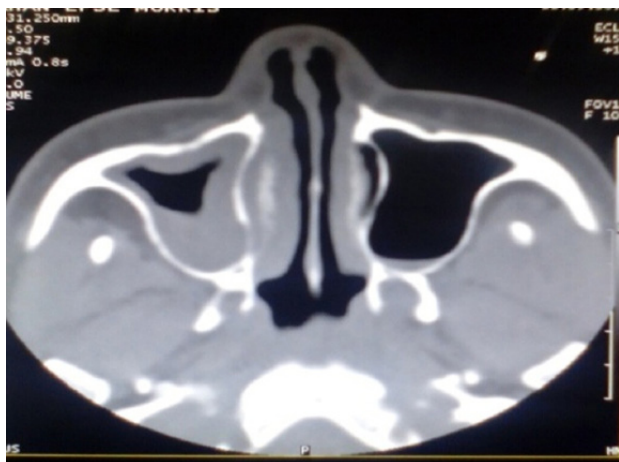

Figure 3 Patient aged 32 years, headache without accompanying signs. Brain scanner in axial section bone window: bilateral maxillary sinusitis.

were women^[5]. In the study of El Amrani^[6], women were most affected by headache with a prevalence between 16-88% for women and 9-69% for men.

In our study the average age of patients was 44 years with extremes ranging from 17 years to 80 years. The predominant population was between 40 years to 49 years. Our results differ from those of Dousset in France^[7] who found a predominance of the age group between 35 and 40 years. The difference in age between this study and the study by Dousset in France^[7] could be explained by the economical and educational differences in both countries. According to Pruvo^[8], symptomatic headache of intracranial lesions is rare; it requires explorations because certain conditions incriminated put at stake the prognosis for life. The first step of the diagnosis is clinical; it specifies the characteristics of pain and accompanying symptoms. Additional tests are required secondly in case of new-onset headache, change in the characteristics of the evolution of known headache, worsening of the intensity or increase in the frequency of known cephalalgic seizures or headache associated with other clinical signs. In our study, the associated signs were motor deficits (39 cases that is 30.2%) and fever (14 cases that is 11%). In 58.8% of cases there were no associated signs. In addition there were 17 cases (25.4%) of a notion of combined hormonal taking, 20 cases of hypertension and 10 cases of trauma. Despite this, in more than 54% of cases the CT was normal. This demonstrates the high incidence of primary headache in accordance with the literature^[4,8-10].

The role of neuroimaging in headache is recognized by all. But its systematic use in the presence of headache is controversial^[1,4,8-9]. Our study, although prospective has not considered the clinical criteria of the feasibility or not of neuroimaging. All examinations requested for headache whatever the motive have been taken into account. These examinations consisted of the performance of a head CT scan without and after iodinated contrast medium IV-injection according to the case^[10]. No other neuroimaging was performed in our study. MRI, considered as the best diagnostic means of headaches was not possible for two reasons. Firstly, it is a costly examination and it is little available. Then in our country we only have MRI of low fields; which limits its diagnostic efficacy. Secondly, we can't communicate directly with the attending physician. We can do it only by a written report in which we have sometimes suggested MRI in addition. Patients with normal headache and with a normal scanner are mostly ambulant.

In our study, 129 cephalalgic patients have had a CT. Sixty examinations were abnormal including 25 cases (19%) that were strokes. This result is consistent with those obtained in other studies

in Africa. Lougue in Burkina Faso^[11], in a similar study had found 86 normal examinations and 78 abnormal examinations including 36 cases (22%) of lesions that were strokes. Strokes were ischemic in 25 cases, hemorrhagic in 5 cases and venous in 1 case (thrombophlebitis). The other etiologies of headache demonstrated on CT scan in our study were sinusitis (9.3%), abscess and encephalitis (7.8%) and trauma (5.4%). In a study carried out by Naggara^[4] in a Danish population, infectious headache accounted for 63% of secondary headache and was the most common. ENT headache accounted for 15%; Traumatic headache 4%; cluster headache 1% and finally non-vascular headache 0.5%. According to Lougue^[11], toxoplasmosis on HIV comes in the 2nd place of causes of headache in Burkina Faso (17%) after stroke. In our study, abscess and encephalitis came in the 3rd place with a percentage of 7.8%.

CONCLUSION

Headache, a symptom commonly explored in neuroradiology, affects in sub-Saharan Africa, particularly the Ivory Coast, elderly patients on average from 44 years and over and mostly females. This is a serious symptom which revealed in 46% of cases an underlying cause dominated by decreasing order of frequency stroke, sinusitis and brain abscess. If in 54% of cases brain CT with and without contrast medium injection does not reveal lesions, it yet makes evoke a higher proportion of primary headache. We believe that it is essential to continue explorations by perfusion CT or MRI. Here we have the opportunity to suggest equipping African hospitals with high field MRI.

CONFLICT OF INTEREST

None of the authors have a conflict of interest with regard to the work in the manuscript.

REFERENCES

- 1 Pala KC, Delémont C, Platon A. Céphalées: quelle imagerie? *Rev Med Suisse* 2013; **9**: 1720-1725
- 2 Godwin SA, Villa J. Acute headache in the ED: Evidence-Based Evaluation and Treatment Options. *Emerg Med Pract* 2001; **3(6)**: 1-32.
- 3 Gilbert JW, Johnson KM, Larkin GL, Moore CL. Atraumatic headache in US emergency departments: recent trends in CT/MRI utilisation and factors associated with severe intracranial pathology. *Emerg Med J* 2012 Jul; **29(7)**: 576-81
- 4 Naggara O, Gauvrit JY, Oppenheim C, Rodrigo S, Pruvo JP, Meder JF: Imagerie des céphalées. *Feuillets de Radiologie* 2005; **45(5)**: 345-354
- 5 Soma SS, Prakash D, Ling Z. Analysis of headache management in a busy emergency room in the United States. *Headache* 2008; **48**: 931-938
- 6 El Amrani M, Lutz G, Boulan P et Massiou H. Céphalées essentielles bénignes non migraineuses. EMC, Neurologie, 17-055-A-55.
- 7 Dousset V, Henry P, Michel P. Epidémiologie des céphalées. *Revue neurol* 2000; **156(43)**: 24-29
- 8 Pruvo JP, Gauvrit JY, Lucas C, Leclerc X, Médér JF. Evolution de l'exploration des céphalées en imagerie d'urgence. *Journal de Radiologie* 2005; **86(10)**: 1236-1237
- 9 Gauvrit JY, Leclerc X, Moulin T, Oppenheim C, Savage J, Pruvo JP, Meder JF. Céphalées dans un contexte d'urgence. *J. Neuroradiol* 2004; **31**: 262-270
- 10 Detsky ME, McDonald DR, Baerlocher MO, Tomlinson GA, McCrory DC, Booth CM. Does the patient with headache have a migraine or need neuroimaging? *JAMA* 2006; **296**: 1274-1283

- 11 Lester M, et al. Imaging in the evaluation of headache. *Med Clin N Am* 2013; **97**: 243-65.
- 12 Lougué LC, Cissé R, Dravé A, Bamouni YA, Tapsoba TL, Siko A, Napon M, Diallo O, Zoungrana R, Kaboré J. Apport de la TDM cérébrale dans le bilan des céphalées. *Journal de Radiologie* 2005; **86(10)**: 1344-5.