

Challenges in Radiology Education

Birendra Raj Joshi

Birendra Raj Joshi, Institute of Medicine, Tribhuvan University, Nepal

Correspondence to: Birendra Raj Joshi, Institute of Medicine, Tribhuvan University, Nepal.

Email: bjoshi01@yahoo.com

Telephone: + 9771 5549747

Received: August 7, 2014 Revised: October 20, 2015

Accepted: October 29, 2015

Published online: December 10, 2015

ABSTRACT

Education in radiology is different from the other subjects. Objective based learning [OBL] utilizes thought provoking exercises to fulfill the objectives. Objective Structured Imaging Examination (OSIE) is introduced. Students are given an image. Several simple questions are formulated related to this image. The students are encouraged to learn the facts in simple steps.

© 2015 ACT. All rights reserved.

Key words: Education; Objective; Radiology

Joshi BR. Challenges in Radiology Education. *International Journal of Radiology* 2015; 2(2): 58-59 Available from: URL: <http://www.ghrnet.org/index.php/ijr/article/view/1177>

REVIEW

Education is something that we human race invented to outshine our life or to understand life itself. Education widens the horizon of our knowledge, equips us with required life skills and multiplies our rational thinking. In the modern era, it is a weapon to tackle challenges and foster a healthy life and encourage students to survive in this competitive world.

Are the students really learning what they need to learn? Are the methods of learning appropriate? All our educational attempts should

facilitate the students to learn and should motivate them to keep pace with time. It should prepare them for the broader virtual classroom that is the world which is outside the small physical classroom.

Educational system should promote personal initiative, creativity and rational deduction of conclusion with the ability to defend the statements. The system should not encourage only memorizing. It should promote understanding of the essential elements to build basic foundation so that complex situation can be solved in simple manner. Education in radiology is different from the other subjects. Radiology is a vast subject in terms of systems covered and modalities that can be used to diagnose the same pathology. The challenges are unique and should be addressed for the requirements of undergraduates and post-graduates in mind.

Complex situation may be understood in several simple steps. Objective based learning [OBL] utilizes thought provoking exercises to fulfill the objectives and self-assessment process to measure the degree of understanding of the subject matter. Using this principle, Objective Structured Imaging Examination (OSIE) is introduced. Students are given a situation. In radiology, this is an image. Several simple questions are formulated related to this image. Hence, the students are encouraged to learn the facts in simple steps. Not only this will arouse interest, it will encourage them to solve complex conditions in multiple simple ways.

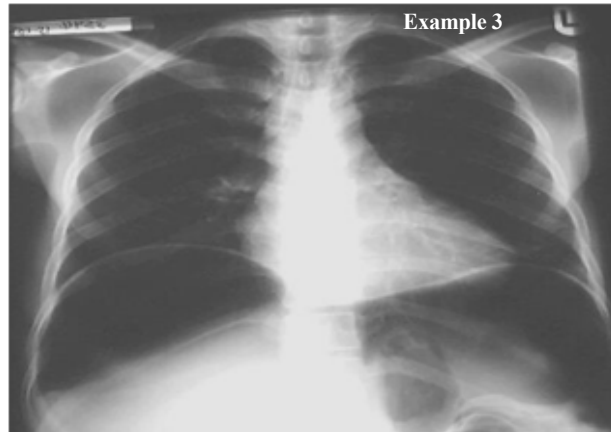
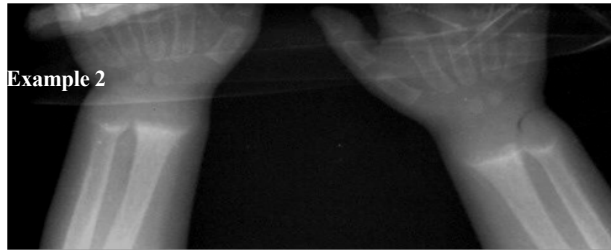
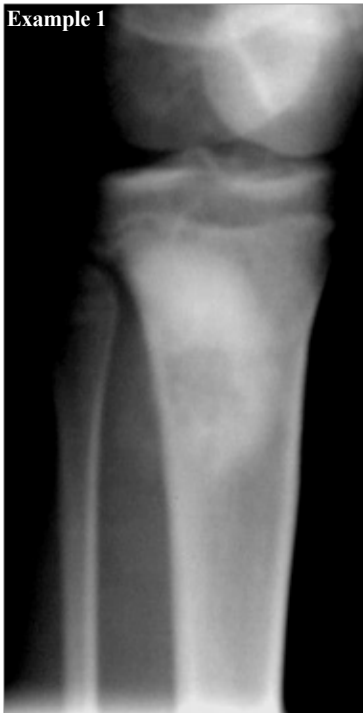Three simple examples are given below:

Example 1

1. What are the findings?
2. What is the diagnosis?
3. What is the age group?
4. What are the complications?

Answer

1. Irregular lucency in the metaphyseal/diaphyseal region with surrounding sclerosis of upper tibia. There is an associated soft tissue mass which can just be seen on the fibular aspect.
2. Osteogenic sarcoma
3. Young adults of 16-20 years.



4. Lung calcifying metastasis, pneumothorax.

Example 2

1. What are the findings?
2. What is the diagnosis?
3. What are the complications?
4. What is the differential diagnosis?

Answer

1. Widening of the growth plate
Indistinct metaphyseal margin
Loss of the white line adjacent to the metaphyseal margin (the zone of provisional calcification).
Fraying and splaying of the metaphyses which often show a cupped appearance – due to weight bearing on the unossified bone
Thin bony spur extending from the corner of the metaphysis
Indistinct cortex due to uncalcified subperiosteal osteoid
2. Rickets
3. Bowing and deformities of the bones develop later -characteristically bowing of the legs, triradiate pelvis, scoliosis, biconcave vertebral bodies, indrawing of the lower part of the chest wall (Harrison's sulcus).
4. Rickets may be confused with Blount's disease, which is a

developmental abnormality involving the upper tibial metaphysis with a large "beak" medially and genu varus deformity. Early walking may be contributory.

Example 3

1. What are the findings?
2. What is the diagnosis?
3. What may be the cause of this?
4. What may be the iatrogenic cause of this?

Answer

1. A very large amount of free air within the peritoneal cavity lying beneath both diaphragms. The liver & spleen are pushed downwards and the diaphragms upwards.
2. Pneumoperitoneum.
3. Typhoid or duodenal ulcer perforation.
4. Laparotomy.

Visual impression will help the learning process. Monotonous studying will be discouraged. Personal evaluation can also be done repeatedly so that a graph of improvement can be deduced. This will also inspire them to learn more quickly and effectively.