

A Novel Pharmacological Treatment of Pseudophakic Presbyopia

Almamoun Abdelkader

Almamoun Abdelkader, MD, Department of Ophthalmology, Faculty of medicine, Al-Azhar University, Cairo, Egypt

Conflict-of-interest statement: The author has no funding or conflict of interest regarding the publication of this paper.

Open-Access: This article is an open-access article which was selected by an in-house editor and fully peer-reviewed by external reviewers. It is distributed in accordance with the Creative Commons Attribution Non Commercial (CC BY-NC 4.0) license, which permits others to distribute, remix, adapt, build upon this work non-commercially, and license their derivative works on different terms, provided the original work is properly cited and the use is non-commercial. See: <http://creativecommons.org/licenses/by-nc/4.0/>

Correspondence to: Almamoun Abdelkader, MD, Assistant professor of ophthalmology, Faculty of Medicine, Al-Azhar University. Consultant of cornea and refractive surgery, Head of Ophthalmology Department, Saudi German Hospital, Aseer, Kingdom of Saudi Arabia, P.O Box 2553.

Email: mamounkader@gmail.com

Telephone: +(966) 17 235 5000

Fax: +(966) 17 2354500

Received: October 6, 2018

Revised: December 10, 2018

Accepted: December 13, 2018

Published online: December 31, 2018

ABSTRACT

AIM: To assess the effectiveness of combining an alpha agonist (brimonidine) with parasympathomimetic drops (carbachol) to induce therapeutic miosis with the goal of reducing the impact of presbyopia in people who are pseudophakic.

METHODS: A randomly allocated, double-masked, placebo-controlled, prospective clinical investigation. Included were forty emmetropic and presbyopic pseudo-phakes, aged 30 to 80, who had uncorrected distance visual acuity of at least 20/20 in each of their eyes and no other optic abnormalities. There were a couple of sets of subjects. In the non-dominant eyes of the intervention group (n =

25 eyes), one dosage of 3% carbachol mixed with 0.2% brimonidine eye drops was applied. 15 eyes made up the control group got placebo drops. The exact impartial evaluator measured the initial pupil size and the subjects' close and far visual acuities prior to treatment, as well as at one, two, four, and eight hours post-treatment in the identical lighting conditions.

RESULTS: When carbachol with brimonidine drops were given to pseudophakic individuals, all showed significant improvements in near vision ($p < 0.0001$). Not a single individual preferred the placebo, and all were enthusiastic with the drops.

CONCLUSIONS: Making the pupil small creates a pinhole camera like effect which safely improves near visual acuity in pseudophakic presbyopes via increased depth of focus.

Key words: Presbyopia; Pseudophakia; Carbachol; Brimonidine; Depth of focus; Miosis

© 2018 The Author(s). Published by ACT Publishing Group Ltd. All rights reserved.

Abdelkader A. A Novel Pharmacological Treatment of Pseudophakic Presbyopia. *International Journal of Ophthalmic Research* 2018; 4(2): 291-294 Available from: URL: <http://www.ghrnet.org/index.php/ijor/article/view/2442>

INTRODUCTION

Increasing the depth of focus and improving the ability to accommodate can both help with near vision. Similar to a smaller aperture in a camera, reducing the pupil can result in a boost in the depth of focus. Typical conventional techniques for treating presbyopia include invasive surgeries and corrective lenses. Several techniques are used during invasive surgeries on the sclera, crystalline lens, and cornea (inlays). For individuals who dislike invasive operations or using corrective lenses, there is still a need for novel non-invasive methods of treating presbyopia.

Presbyopia symptoms are present in patients after cataract lens extraction. Methods of corrections of pseudophakic presbyopia primarily include: (1) implantation of multifocal and accommodative (IOLs); (2) pseudophakic monovision induced by monofocal IOLs^[1] and (3) corneal inlays. The corneal inlay from

Irvine, California, USA produces a pinhole-like effect that raises the depth of focus and enhances near vision acuteness^[2-7]. In this setting, I tried to achieve this aim with no surgical procedures using drops.

In this study, I described a noninvasive therapeutic alternative for presbyopic pseudophakes that involves using ocular drops incorporating two drugs: 0.2% brimonidine, an alpha agonist, and 3% carbachol, a parasympathomimetic (patients receiving treatment). Some patients received placebo eye drops as a control. This pilot study attempts to assess the effectiveness of combining an alpha agonist with a parasympathomimetic medication for short-term enhancement of near vision in pseudophakic individuals by intensifying the depth of focus.

PATIENTS AND METHODS

The RCRC Independent Review Board, LLC 2111 West Baker Lane, Suite 400 Austin, Texas 78758 gave authorization before this study could start. Written informed consent was obtained from each participant, and the Helsinki Declaration's principles were adhered to in the research. The pharmacological stimulation procedure was created in compliance with Dr. Herbert Kaufman's prior invention^[8].

Participants in the research project were volunteers chosen at random. When an uncorrected end-point print size of \geq Jaeger (J) 5 was enhanced by ≥ 1 optotype with the use of a lens $\geq +1.00$ D, presbyopia was deemed to be existent. Every participant with pseudophakic condition was found to have satisfactory ocular and physical health. All individuals underwent a dilated fundus examination prior to being deemed qualified to participate in the study. The assessment investigated the retinal detachment vulnerability and negative reactions to the drops. Ages ranging from 30 to 80 years old, emmetropic pseudophakes (cycloplegic spherical equivalent (SE), ± 0.25 D; astigmatism, ≤ 0.25 D), round pupils, acceptable implant location, and binocular uncorrected distance visual acuity $\geq 20/20$ were among the eligibility established standards. Patients having refractive errors that exceeded 0.25 diopters, ocular media opacities, variable pupil size, and medications that could interfere with carbachol and brimonidine were among the exclusion specifications.

Procedures

The patients' non-dominant eye was given just one dosage of 3% carbachol mixed with 0.2% brimonidine, or a placebo, administered in a veiled manner. Prior to medical care and at 1, 2, 4, and 8 hours later, the same impartial evaluator estimated the patient's initial pupil size and their near and distant visual acuities under the same lighting conditions. The typical Snellen projector chart was used to evaluate distance visual acuity at a distance of 4 meters. Utilizing a hand-held Rosenbaum chart with Jaeger notation, near visual acuity (NVA) was tested at 40 cm, consistently utilizing the same luminance of 160 cd/m². A Colvard portable infrared pupillometer (Oasis Medical, Glendora, CA, USA) was used to assess pupil size (PS). The subjects' satisfaction with their near- and far-sightedness as well as any negative symptoms were also tracked.

Statistical analysis

Employing the statistical program MedCalc version 16.8, the Mann-Whitney U test was implemented to analyze the data. P-values below 0.05 were regarded as statistically significant. The mean, range, and standard deviation (SD) of the data were reported.

RESULTS

The study comprised forty emmetropic and presbyopic pseudophakes,

aged 30 to 80, who had uncorrected distance visual acuity of not less than 20/20 in each of their eyes. Of the 25 eyes in the therapy group, 16 were male and 9 were female, with a mean age of 54.21 ± 14.49 years (range, 30-80 years). The control group, consisting of 10 males and 5 females, had a mean age of 54.42 ± 3.1 years (range, 40-75 years). There was not a significant distinction in the two groups' mean ages or sexes. After one hour of therapy, the mean near visual acuity (NVA) in the treatment group increased considerably ($p < 0.0001$) from $J-7.5 \pm 1$ before treatment to $J-1.42 \pm 0.5$ at one hour, $J-1.57 \pm 0.5$ at two hours, $J-2.14 \pm 0.5$ at four hours, and $J-2.35 \pm 0.49$ after eight hours. The mean pupil size (PS) dropped significantly from 4.1 ± 0.5 mm prior to treatment to 1.2 ± 0.3 mm at one hour, 1.6 ± 0.3 mm at two hours, 2 ± 0.2 mm at four hours and 2.5 ± 0.4 mm at eight hours following drops ($p < 0.0001$).

Placebo (control) group

In this group, there was not a statistically significant variance in mean (NVA) or mean pupil size before therapy, nor at any stage following treatment. Table 1 is a summary of the data. The mean variances in near visual acuity (Jaeger) and pupil size (mm) over time for the treatment and control groups are displayed in Figures 1 and 2, respectively.

Distance visual acuity

Prior to treatment, all individuals had uncorrected distant vision of 20/20 in their two eyes, and this level of acuity persisted throughout the whole post-treatment timeframe.

Groups' satisfaction

Group receiving carbachol plus brimonidine (treatment group)

If these drops were readily accessible, each individual who took carbachol plus brimonidine would take advantage of them. They expressed contentment with their close-up and distant sight. Out of the 25 respondents, 8 (32%) said the result was tremendous for the first 8 hours before fading over time. In the therapy group, no individual complained a feeling of burning, headache, or browache.

Placebo group

The placebo group's patients all stated that the drops did not enhance their near vision, leading them to stop using the drug.

DISCUSSION

The objective of this pilot study was to further enhance pseudophakic participants' near eyesight pharmacologically. The pinhole result, which increases depth of focus, is the basis for pharmaceutical therapy of presbyopia, as opposed to corrective lenses. The idea is efficiently implemented in corneal inlays placed in the non-dominant eye to improve close vision by deepening the focus despite some worries about the Pulfrich effect and implant centering^[7,9,10]. I tried utilizing drops to specifically target this consequence without intervening with it excessively.

When comparing the improvement in near visual acuity of all participants receiving 3% Carbachol plus brimonidine to placebo ($p < 0.0001$), there was an enormous advance.

In the current research, pseudophakic presbyopes with reduced pupil size and enhanced depth of focus were treated with a mixture of 3% carbachol and 0.2% brimonidine. The two medications in question have been safely and successfully treating glaucoma for many years; they have FDA approval. In scotopic situations, brimonidine has been shown to efficiently minimize pupil dilatation, which in turn lessens scotopic sensations following laser refractive

procedures.

When receiving monocular treatment, a fellow eye's pupil that is normally untreated may exhibit some fuzzy near vision, but it will still be able to see distant things clearly and experience no reduction in light perception. After the images were combined, every individual in the treatment group could see clearly up close and far away without experiencing any darkness. For an 8-hour impact, one daily dose of carbachol with brimonidine can be applied.

CONCLUSION

For many pseudophakic presbyopes, a single daily dose of one drop of carbachol and brimonidine could provide satisfactory reading vision. Future research is being planned to investigate the utility of this topical treatment in presbyopia with various refractive deficiencies.

ACKNOWLEDGEMENT

Herbert E. Kaufman headed up the study's principal researcher and collaborated with data interpretation.

REFERENCES

- Charman WN. Developments in the correction of presbyopia II: surgical approaches. *Ophthalmic Physiol Opt* 2014; **34**(4): 397-426.[DOI: 10.1111/opo.12129]; [PMID: 24716827]
- Seyeddain O, Hohensinn M, Riha W, Nix G, Rückl T, Grabner G, Dextl AK. Small-aperture corneal inlay for the correction of presbyopia: 3-year follow-up. *J Cataract Refract Surg*. 2011; **38**(1): 35-45.[DOI: 10.1016/j.jcrs.2011.07.027]; [PMID: 22018596]
- Seyeddain O, Riha W, Hohensinn M, Nix G, Dextl AK, Grabner G. Refractive surgical correction of presbyopia with the AcuFocus small aperture corneal inlay: two-year follow-up. *J Refract Surg*. 2010; **26**(10): 707-15. [DOI: 10.3928/1081597X-20100408-01]; [PMID: 20438021]
- Dextl AK, Seyeddain O, Riha W, Hohensinn M, Rückl T, Reischl V, Grabner G. One-year visual outcomes and patient satisfaction after surgical correction of presbyopia with an intracorneal inlay of a new design. *J Cataract Refract Surg*. 2012; **38**(2): 262-9. [DOI: 10.1016/j.jcrs.2011.08.031]; [PMID: 22138501]
- Tabernero J, Schwarz C, Fernández EJ, Artal P. Binocular visual simulation of a corneal inlay to increase depth of focus. *Invest Ophthalmol Vis Sci*. 2011; **52**(8): 5273-7. [DOI: 10.1167/iops.10-6436]; [PMID: 21436279]
- Fernández EJ, Schwarz C, Prieto PM, Manzanera S, Artal P. Impact on stereo-acuity of two presbyopia correction approaches: monovision and small aperture inlay. *Biomed Opt Express*. 2013; **4**(6): 822-30. [DOI: 10.1364/BOE.4.000822]; [PMID: 23761846]; [PMCID: PMC3675862]
- Naroo SA, Bilkhu PS. Clinical utility of the KAMRA corneal inlay. *ClinOphthalmol*. 2016; **10**: 913-9. [DOI: 10.2147/OPTH.S89132]; [PMID: 27274194]; [PMCID: PMC4876093]
- Kaufman HE. Preparations and methods for ameliorating or reducing presbyopia. US patent number 8455494 B2.
- Huseynova T, Kanamori T, Waring GO 4th, Tomita M. Small-

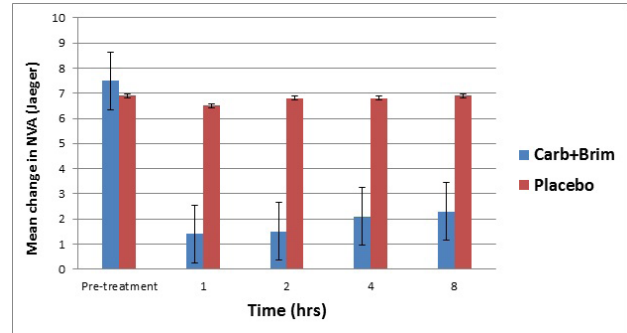


Figure 1 Distribution of mean change in near visual acuity (Jaeger) over time for treatment and control groups.

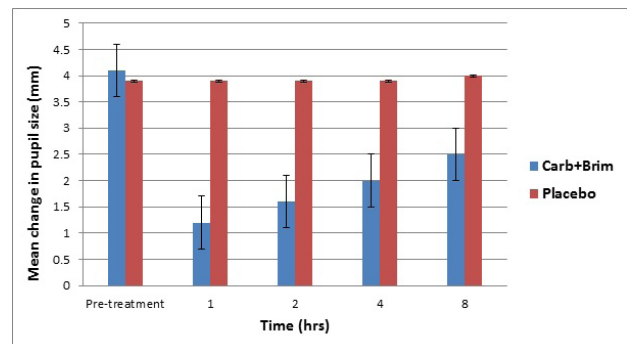


Figure 2 Distribution of mean change in pupil size (mm) over time for treatment and control groups.

Table 1 Mean change in near visual acuity (NVA) (J) and pupil size (PS) (mm) overtime using 3% Carbachol plus 0.2% brimonidine drops vs placebo.

Time (Hrs)		Carb+Brim drops	Placebo	P value
Pre-treatment	NVA	7.5	6.9	0.1
	PS	4.1	3.9	0.4
1- hour	NVA	1.4	6.5	< 0.0001
	PS	1.2	3.9	< 0.0001
2- hour	NVA	1.5	6.8	< 0.0001
	PS	1.6	3.9	< 0.0001
4- hour	NVA	2.1	6.8	< 0.0001
	PS	1.9	3.9	< 0.0001
8- hour	NVA	2.3	6.8	< 0.0001
	PS	2.5	4	< 0.0001

- aperture corneal inlay in presbyopic patients with prior phakic intraocular lens implantation surgery: 3-month results. *ClinOphthalmol*. 2013; **7**: 1683-6.[DOI: 10.2147/OPTH.S50397]; [PMID: 24003304]; [PMCID: PMC3755705]
- Huseynova T, Kanamori T, Waring GO 4th, Tomita M. Outcomes of small aperture corneal inlay implantation in patients with pseudophakia. *J Refract Surg*. 2014; **30**(2): 110-6.[DOI: 10.3928/1081597X-20140120-06]; [PMID: 24763476]

Peer Reviewer: Muawyah Al Bdour