

CASE REPORT

A Clinically Documented Appearance of Choroidal Polyps in A Patient with AMD: A Case Report

Carolina Arruabarrena MD, Daniele Ferrari MD

Carolina Arruabarrena, Retinal Department of Hospital Príncipe de Asturias, Alcalá de Henares, Spain

Daniele Ferrari, Department of Ophthalmology, Hospital universitario Príncipe de Asturias, Alcalá de Henares, Spain

Conflict-of-interest statement: The author(s) declare(s) that there is no conflict of interest regarding the publication of this paper.

Open-Access: This article is an open-access article which was selected by an in-house editor and fully peer-reviewed by external reviewers. It is distributed in accordance with the Creative Commons Attribution Non Commercial (CC BY-NC 4.0) license, which permits others to distribute, remix, adapt, build upon this work non-commercially, and license their derivative works on different terms, provided the original work is properly cited and the use is non-commercial. See: <http://creativecommons.org/licenses/by-nc/4.0/>

Correspondence to: Daniele Ferrari, Carretera Alcala-Meco Km 30 s/n, Alcala de Henares, Madrid, Spain.

Email: ferro.dani@hotmail.it

Telephone: +34918878100 ext 2189

Received: May 22, 2018

Revised: August 10, 2018

Accepted: August 14, 2018

Published online: October 4, 2018

ABSTRACT

AIM: To report the insurgence of a polypoidal choroidal lesions during the follow-up of a type 1 choroidal neovascular membrane (CNV) in an aged-related macular degeneration (AMD) treated with antiangiogenic documented by indocyanine green fluoresceinography (ICGA).

METHODS AND RESULTS: A 69-year-old man with an AMD disciform scar on his left eye developed a CNV type 1 in his right eye. He was treated with three monthly loading doses and PrN ranibizumab for 15 months until changing to aflibercept. Due to the limited response to anti-VEGF treatment we decided to perform an ICGA which showed a CNV without other lesions associated. After another 9 months of continuous treatment the patient developed a

macular haemorrhage. We performed a pneumatic displacement and ICGA was repeated showing a polypoidal change in the edge of the CNV (NV-AMD related polyps). Therefore we started a combined treatment with photodynamic therapy and aflibercept injections.

CONCLUSIONS: Polypoidal changes coexisting with a CNV have been documented in a range of different diseases including AMD. Some studies have demonstrated clinical and statistically significant differences between idiopathic polypoidal choroidal vasculopathy (PVC) and NV-AMD-related polyps so they could be considered as distinct entities. But, to our knowledge, this is the first report on NV-AMD-related polyps that documents with ICGA the sequence in which CNV and polyps appear.

Key words: Age-related macular degeneration (AMD); Polypoidal choroidal vasculopathy; Branching vascular network (BVN); Type 1 choroidal neovascularization (CNV)

© 2018 The Author(s). Published by ACT Publishing Group Ltd. All rights reserved.

Arruabarrena C, Ferrari D. A Clinically Documented Appearance of Choroidal Polyps in A Patient with AMD: A Case Report. *International Journal of Ophthalmic Research* 2018; **4(2)**: 287-290 Available from: URL: <http://www.ghrnet.org/index.php/ijor/article/view/2347>

INTRODUCTION

Despite traditionally PCV has been considered as a specific subtype of CNV formation, important studies^[1] reported differences between PVC and AMD, from the aetiology and the usual location of the lesion, to the mechanisms of the lesion development, describing them as different diseases. To further complicate the situation, polypoidal changes in choroidal neovascular diseases including AMD have been reported; and finally polyp lesions have been classified into idiopathic PVC and secondary PVC^[5]. The latter includes NV-AMD-related polyps that are focal polypoidal morphological changes commonly seen within the spectrum of type 1 neovascular tissue^[6].

Our case shows that these polypoid choroidal lesions appear during the evolution of a CNV type 1 despite intensive anti-VEGF treatment.

METHODS AND RESULTS

A 69-years-old man with a personal history of arterial hypertension and a sleep apnoea syndrome and an ophthalmological history of exudative AMD in his left eye (LE) treated with anti-VEGF developing a disciform scar, with the Best corrected Visual Acuity (BCVA) of LE lower than 20/400.

He returned to our attention in April 2013 complaining of blurred vision in his right eye (RE). BCVA was 20/40 and he was diagnosed of a type 1 AMD CNV in his RE and started anti-VEGF treatment with ranibizumab in three monthly loading doses and pro re nata (PrN) strategy.

In June 2014, after 15 months and 12 ranibizumab injections without signs of remission, we switched to aflibercept with three monthly loading doses and bimonthly re-injections and the BCVA reached 20/32. In March 2015, after 11 month of aflibercept treatment, BCVA decreased to 20/40 and we observed a constant CNV growth. Due to the poor response to anti-VEGF, an ICGA was performed without evidence of polyps and the treatment was switched to monthly aflibercept.

But on December 2015, the patient went to our emergency service because of loss of vision in his RE.

His VA was lower than 20/400 and a huge macular haemorrhage was seen in this eye.

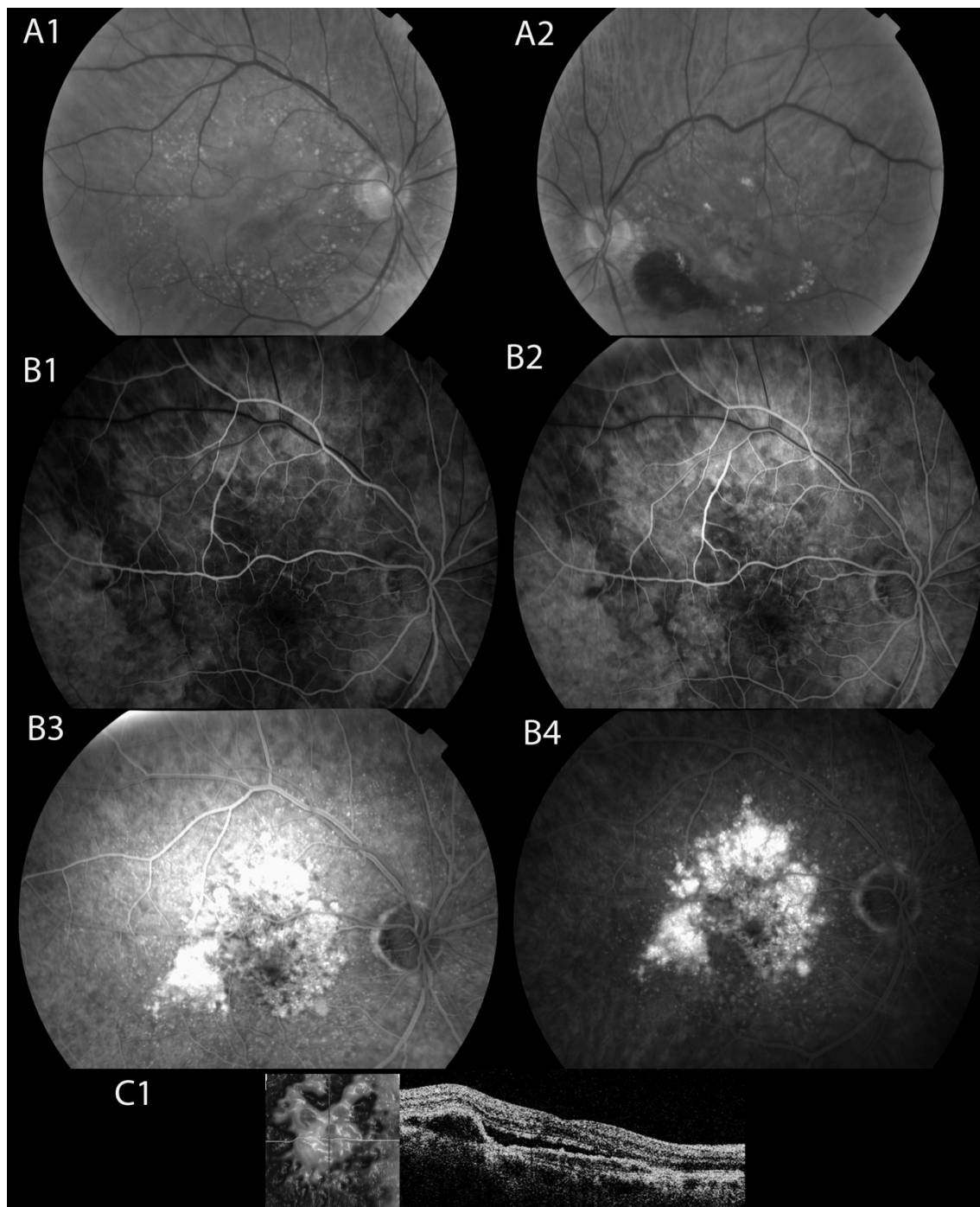


Figure 1 At the top, Fundus color retinographies of both eyes showing in the RE a flat PED with drusen around. In the middle four AFG images showing an occult NV-AMD with a unknown origin leakage pattern. In the bottom the OCT image with a active PED with a great amount of subretinal fluid.

We attempted a pneumatic displacement; an anterior chamber paracentesis and a 0.1 mL of rt-PA and 0.4 mL of sulphur fluoride (SF6) intravitreal injection were done. After two days we notice a blood displacement outside of the macular region. We repeated the ICGA after two weeks showing an extramacular polyp connected to

the CNV and we associated a photodynamic therapy (PDT) to the monthly aflibercept treatment^[2,3].

On February 2016 after a pneumatic displacement with rt-PA^[4] and SF6 injection, 3 aflibercept and one PDT the BCVA of the RE is 20/40.

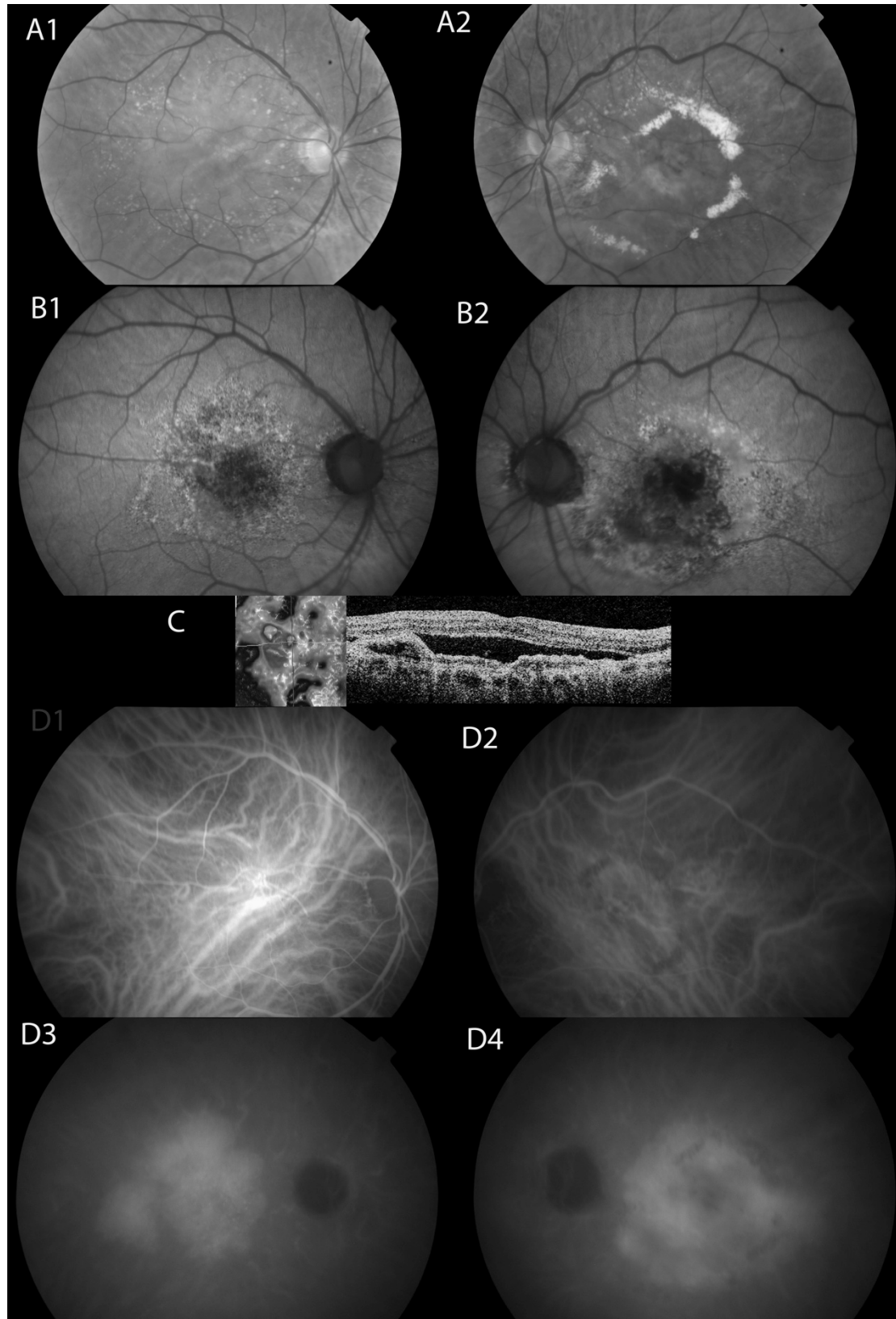


Figure 2 At the top. Fundus retinographies and autofluorescence of both eyes two years later. In the middle the OCT image and in the bottom the ICGA images of both eyes showing a big leaking plaque without polyps in both eyes.

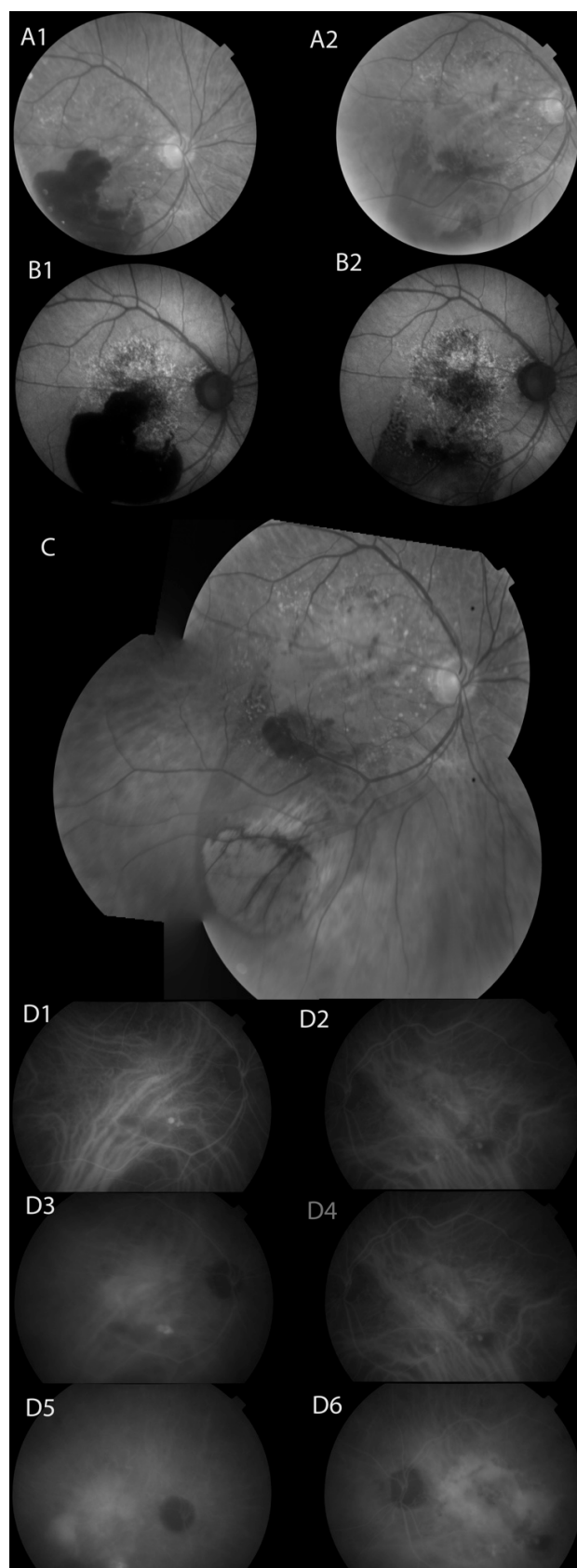


Figure 3 At the top. Fundus retinography of the RE with the initial haemorrhage and two days after the pneumatic displacement. In the middle a photomontage of the RE two weeks after the displacement and in the bottom an ICGA of both eyes showing extramacular polyps in both eyes and a big leaking plaque in the final images of the ICGA.

CONCLUSIONS

Since the first description of the PVC by Yannuzzi *et al.*^[7] in 1982 many authors described the differences between isolated idiopathic PVC and AMD-related PVC. They defined clinical diagnostic criteria associated to multimodal images to distinguish these two entities^[6]. While idiopathic PVC in ICGA confirmed polypoidal lesions showing early hyperfluorescent spots and branching vascular networks, ICGA in AMD-related PVC showed the presence of large neovascular complex, which on SD-OCT was confirmed to be located between Bruch's membrane and the retinal pigment epithelium, and the polyps typically represented only a small portion at the end of a much larger type 1 CNV.

All these articles prove the presence of polyps in an AMD context but we haven't found anyone that assesses or investigates the moment when this change occurs.

In our case, we documented the appearance of one polyp in a patient with a type 1 CNV-AMD. We performed two different ICGA separated seven months, demonstrating the appearance of a new polyp in the second angiography, despite intensive antiangiogenic treatment: the first lesion in our patient was the type 1 CNV that was followed by the polyp formation. We don't know if the history of arterial hypertension played a role in the development of the polyps.

The NV-AMD-related PVC is a variant of the classic AMD and a cause of haemorrhagic complication, but we have to understand carefully the pathogenic of this change in the evolution of the disease and suspect it to offer the best therapy to our patients.

REFERENCES

1. Balaratnasingam C, Lee WK, Koizumi H, Dansingani K, Inoue M, Freund KB. Polypoidal Choroidal Vasculopathy: A Distinct Disease or Manifestation of Many? *Retina* 2016; **36**(1): 1-8. [PMID: 26414957]; [DOI: 10.1097/IAE.0000000000000774]
2. Hara C, Sawa M, Sayanagi K, Nishida K. One-year results of intravitreal aflibercept for polypoidal choroidal vasculopathy. *Retina* 2016; **36**(1): 37-45. [PMID: 26383709]; [DOI: 10.1097/IAE.0000000000000767]
3. Koh AH; Expert PCV Panel, Chen LJ, Chen SJ, Chen Y, Giridhar A, Iida T, Kim H, Yuk Yau Lai T, Lee WK, Li X, Han Lim T, Ruamviboonsuk P, Sharma T, Tang S, Yuzawa M. Polypoidal choroidal vasculopathy: evidence-based guidelines for clinical diagnosis and treatment. *Retina* 2013; **33**(4): 686-716. [PMID: 23455233]; [DOI: 10.1097/IAE.0b013e3182852446]
4. Kitagawa Y, Shimada H, Mori R, Tanaka K, Yuzawa M. Intravitreal Tissue Plasminogen Activator, Ranibizumab, and Gas Injection for Submacular Hemorrhage in Polypoidal Choroidal Vasculopathy. *Ophthalmology* 2016; **123**(6): 1278-86. [PMID: 26949121]; [DOI: 10.1016/j.ophtha.2016.01.035]
5. Coscas G, Lupidi M, Coscas F, Benjelloun F, Zerbib J, Dirani A, Semoun O, Souied EH. Toward a specific classification of polypoidal choroidal vasculopathy: idiopathic disease or subtype of age-related macular degeneration. *Invest Ophthalmol Vis Sci* 2015; **56**(5): 3187-95.
6. Maruko I, Iida T, Saito M, Nagayama D. Combined cases of polypoidal choroidal vasculopathy and typical age-related macular degeneration. *Graefes Arch Clin Exp Ophthalmol* 2010; **248**(3): 361-8. [PMID: 20072785]; [DOI: 10.1007/s00417-009-1276-2]
7. Yannuzzi LA, Sorenson J, Spaide RF, Lipson B. Idiopathic polypoidal choroidal vasculopathy (IPCV). *Retina* 1990; **10**(1): 1-8. [PMID: 1693009]