

CASE REPORT

An Idiopathic Papillophlebitis Associated Macular Edema Case Treated with Intravitreal Ranibizumab

Burak Simsek, Sevil Ari Yaylali, Nadim Bromand

Burak Simsek, Istanbul Medeniyet University Goztepe Educational and Research Hospital, Turkey

Sevil Ari Yaylali, Associate Professor of Ophthalmology, FEBO, FICO, Istanbul Medeniyet University, Goztepe Educational and Research Hospital Istanbul, Turkey

Nadim Bromand, Istanbul Medeniyet University Goztepe Educational and Research Hospital, Turkey

Conflict-of-interest statement: The author(s) declare(s) that there is no conflict of interest regarding the publication of this paper.

Correspondence to: Burak Simsek, Istanbul Medeniyet University Goztepe Educational and Research Hospital, Turkey.

Email: drburaksimsek@gmail.com

Telephone: +90-53579938/36

Received: August 15, 2016

Revised: October 13, 2016

Accepted: October 17, 2016

Published online: December 31, 2016

ABSTRACT

A 43-year-old woman presented with a complaint of acute loss of vision in the right eye. Visual acuity in the right eye at time of presentation was 0.2. Fundus examination revealed optic disc edema, venous engorgement and tortuosity and retinal hemorrhages. Fluorescein angiography showed macular edema and a leakage from optic nerve head and retinal veins. The spectral domain optical coherence tomography (sd-OCT) revealed cystoid macular edema. She had no other pertinent medical history. Radiological imaging, systemic and hematologic evaluation was within normal limits except an elevated erythrocyte sedimentation rate. Intravitreal ranibizumab injection was performed. Improvement in visual acuity and partially regression of macular and optic disc edema were observed at first month examination. A recurrence of the macular edema was detected at the second month. At the second month examination after second ranibizumab injection visual acuity improved to 0.9, macular and optic disc edema completely regressed. There was no recurrence in

macular edema during 9 months follow-up. In spite of the possible recurrence, intravitreal ranibizumab can be an effective treatment modality in the management of the idiopathic papillophlebitis associated macular edema.

Key words: Idiopathic papillophlebitis; Macular edema; Ranibizumab

© 2016 The Author(s). Published by ACT Publishing Group Ltd. This is an open access article under the CC BY-NC-ND license (<http://creativecommons.org/licenses/by-nc-nd/4.0/>).

Simsek B, Yaylali SA, Bromand N. An Idiopathic Papillophlebitis Associated Macular Edema Case Treated with Intravitreal Ranibizumab. *International Journal of Ophthalmic Research* 2016; 2(4): 201-203 Available from: URL: <http://www.ghrnet.org/index.php/ijor/article/view/1825>

INTRODUCTION

Papillophlebitis is an uncommon ophthalmological pathology with an uncertain etiology^[1]. Firstly it was described as an entity like the atherosclerotic central vein occlusion and was misdiagnosed as optic neuritis and papilledema^[2]. In fact, this disorder is a syndrome with unilateral optic disc edema and retinal hemorrhages in varying degrees with engorgement and tortuosity of the retinal veins in a healthy adult^[1,2]. Basically it is a subtype of central retinal vein occlusion. Pathophysiologically, it is thought that there is an inflammation of the central retinal vein in the optic nerve head or retrolaminar region^[3].

Several treatment options for papillophlebitis as steroids, vascular endothelial growth factor inhibitors (anti-VEGF), antiplatelet and anticoagulant drugs have been previously described^[4-6]. In this study, we presented visual and anatomical response of intravitreal ranibizumab in a case with idiopathic papillophlebitis associated macular edema.

CASE REPORT

A 43 year-old female patient applied to our clinic with a complaint of decreased visual acuity in the right eye for the past one week. In

the ophthalmological examination, visual acuity was 2/10 in right eye, 10/10 in left eye. There were no signs of anterior chamber or vitreous inflammation. Fundus examination revealed optic disc edema, venous engorgement and tortuosity, retinal hemorrhages and macular edema in the right eye and normal appearance in the left eye. Fluorescein angiography showed macular edema and a leakage from optic nerve head and retinal veins in the right eye (Figure 1A, B). The spectral domain optical coherence tomography (sd-OCT) revealed cystoid macular edema in the right eye (Figure 2A). Systemic and laboratory evaluations for infectious and inflammatory causes and hypercoagulability were unremarkable except an elevated erythrocyte sedimentation rate. The magnetic resonance imaging (MRI) of brain and orbit were normal. Since the patient did not accept the intravitreal steroid injection, intravitreal ranibizumab injection was performed. At first month examination the visual acuity increased to 0.7 and optic disk boundaries were more distinguishable. Intraretinal cysts were completely but subretinal fluid was partially regressed on the sd-OCT (Figure 2B). A recurrence of the macular edema was detected at the second month (Figure 2C). The second intravitreal ranibizumab injection was performed. At the fourth month visual acuity improved

to 0.9, macular and optic disc edema completely regressed (Figure 2D). There was no recurrence in macular edema during 9 months follow-up.

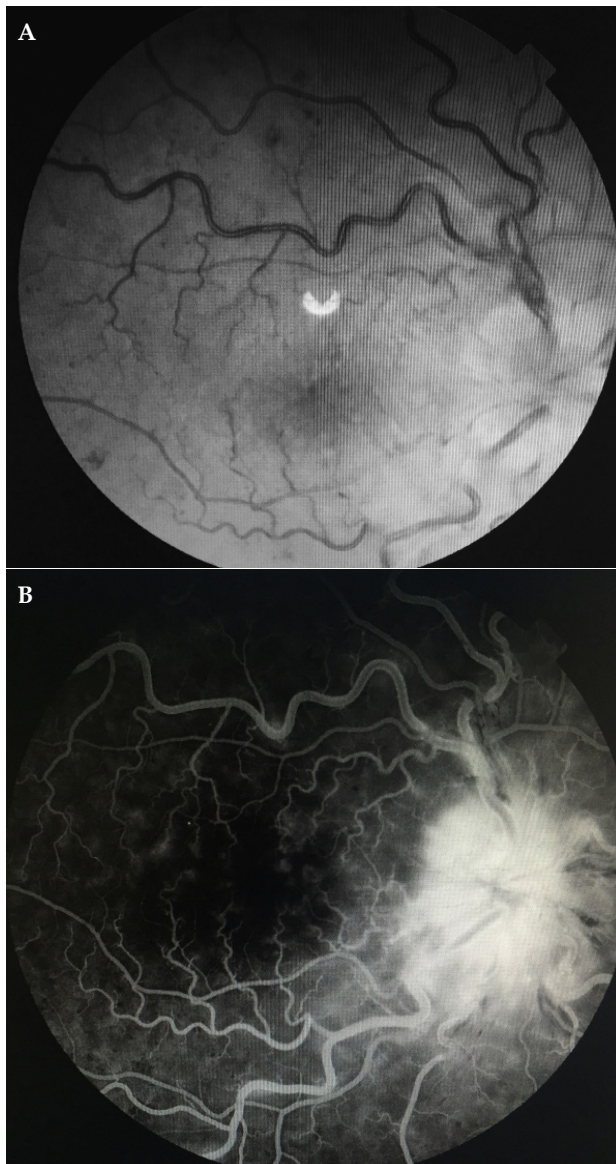


Figure 1 Fundus photography (A) and florescein angiography image (B) of right eye before treatment.

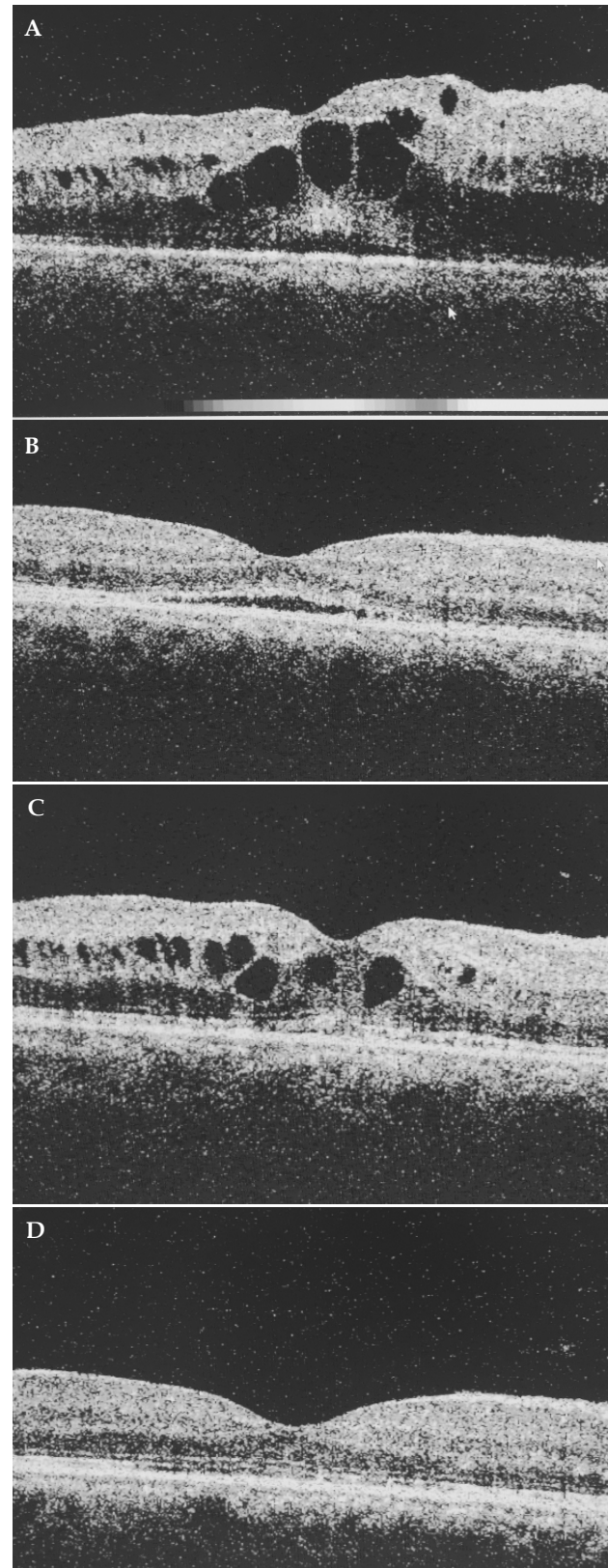


Figure 2 OCT images of right eye before treatment (A), in the first month visit after first ranibizumab injection (B), recurrence after 2 months of ranibizumab injection (C), after 2 months of second ranibizumab injection (D).

DISCUSSION

There is no proven treatment method for papillophlebitis associated macular edema^[5]. Chang *et al* published 4 papillophlebitis cases with macular edema which were successfully treated with intravitreal triamcinolone acetonide^[7]. Lima *et al* reported a papillophlebitis case accompanying central retinal vein and artery occlusion which was successfully treated with intravitreal triamcinolone and bevacizumab^[6]. Spontaneous slow resolution in 3–6 months in the papillophlebitis cases^[1,2,8,9] was also reported. Both patients with 20/40 and better final visual acuity in 54 % of papillophlebitis cases followed up to at least 6 months and patients with worse final visual acuity were reported^[4,10].

In our study the regression of the fluids in the macula in the first month and recurrence at the second months when the effect of intravitreal ranibizumab weaken prove that the regression of the macular edema is not coincidence. Since the theory that inflammation plays a role in pathophysiology, steroids look like more reasonable treatment method for papillophlebitis. However the well-known role of the VEGF in multiple retinal vascular pathologies associated macular edema suggests the possibility of its contribution of this pathology. So anti-VEGF treatment might be safer treatment method for faster visual recovery while papillophlebitis resolves spontaneously and could be used in patients with concern about corticosteroids related side effects.

In our knowledge this is the first report that describes the effect of ranibizumab in papillophlebitis associated macular edema.

CONCLUSION

In spite of the possible recurrence intravitreal ranibizumab can be an effective and safe treatment modality in the management of the idiopathic papillophlebitis associated macular edema

REFERENCES

- 1 Lonn LI, Hoyt WF. Papillophlebitis: a cause of protracted yet benign optic disc edema. *Eye, Ear, Nose Throat Mon* 1966; 45: 62-68. [PMID: 5920162]
- 2 Ellenberger C, Messner KH. Papillophlebitis: benign retinopathy resembling papilledema or papillitis. *Ann Neurol* 1978; 3: 438-440. [PMID: 727723]
- 3 Hayreh SS. Optic disc vasculitis. *Br J Ophthalmol* 1972; 56: 652-676. [PMID: 4653856]; [PMCID: PMC1215368.]
- 4 Fong ACO, Schatz H, McDonald HR, Burton TC, Maberley AL, Joffe L, Zegarra H, Nadel AJ, Johnson RN. Central retinal vein occlusion in young adults (papillophlebitis). 1999; *Retina* 11: 3-11. [PMID: 1565869.]
- 5 Chang YC, Wu WC. Management of papillophlebitis associated cystoid macularedema with intravitreal triamcinolone acetonide: a case report. *Retin Cases Brief Rep.* 2007 Winter; 1(1): 14-6.
- 6 Lima VC, Prata TS, Landa G, Yannuzzi LA, Rosen RB. Intravitreal triamcinolone and bevacizumab therapy for combined papillophlebitis and central retinal artery occlusion. *Retin Cases Brief Rep.* 2010 Spring;4(2):125-8. [PMID: 25390382]; [DOI: 10.1097/ICB.0b013e3181ad3957]
- 7 Chang YC, Wu WC. Intravitreal triamcinolone acetonide for the management of papillophlebitis and associated macular edema. *Int Ophthalmol.* 2008 Aug; 28(4): 291-6. [PMID: 17701380]
- 8 Lyle T, Wybar K. Retinal vasculitis. *Br J Ophthalmol* 1961; 45: 778-788.
- 9 Hart CD, Sanders MD, Miller SJH. Benign retinal vasculitis: clinical and fluorescein angiographic study. *Br J Ophthalmol* 1971; 55: 721-733. [PMID: 5129964]; [PMCID: PMC1208541]
- 10 Recchia FM, Carvalho-Recchia CA, Hassan TS. Clinical course of younger patients with central retinal vein occlusion. *Arch Ophthalmol* 2004; 122: 1545-1549. [PMID: 15006842]

Peer reviewer: Hülya Güngel